

CONTRALATERAL MASTECTOMY FOR UNILATERAL BREAST CANCER

AIMS

The aim of this document is to provide practical guidance for the management of a woman with unilateral breast cancer who requests a contralateral mastectomy (CM) at the time of the index mastectomy or at a later date.

This document does not provide guidance with regards to bilateral mastectomy as part of a risk reduction strategy for high-risk individuals without breast cancer. Please refer to [NICE](#).

SUMMARY

For the majority of women with unilateral breast cancer, contralateral mastectomy is not required. Women with unilateral breast cancer who proceed with contralateral mastectomy must be fully counselled as to the potential risks.

BACKGROUND

In the USA increasing numbers of bilateral mastectomies are being performed for unilateral breast cancer, this is despite a decreasing incidence of contralateral breast cancer (CBC) due to the use of adjuvant systemic therapies^{1,2}. A similar rise in bilateral mastectomy has been observed in the UK³ but not all European countries⁴.

The reasons for a request or offer of contralateral mastectomy (CM) can be multi-factorial and complex: e.g. to prevent future regret (done everything I can), to avoid breast screening because of breast density, fear of screening recalls, to achieve symmetry or maximise use of a generous abdominal donor site, etc. In addition, high profile public figures, such as Angelina Jolie, undergoing bilateral mastectomy as part of a risk reduction strategy reduction for BRCA mutations, have led to the misconception amongst woman with breast cancer that bilateral mastectomy offers the 'best' chance of survival.

The majority of women do not require CM and for some it will have a negative impact on quality of life. It is important clinicians explore the reasons behind a request for CM and address the individual patient concerns. Those patients who decide to proceed with CM must be fully counselled and understand the potential risks⁵.

The American Society of Breast Surgeons produced comprehensive [guidelines](#) for contralateral mastectomy in 2016. The publication includes a patient decision tool.

HOW TO MANAGE A REQUEST FOR CONTRALATERAL MASTECTOMY FOR UNILATERAL BREAST CANCER

The majority of women who request a contralateral mastectomy for unilateral cancer either at the time of the index mastectomy or at a later date do so because they [overestimate the benefits](#) or misunderstand the rationale for a contralateral mastectomy.

It is important to explore, address and document the reasons behind a request for CM.

Often women will be satisfied with a simple explanation of the risks and benefits of CM and a clear explanation as to what CM can and cannot achieve.

SUMMARY STATEMENT:

CONTRALATERAL MASTECTOMY FOR UNILATERAL BREAST CANCER

Broadly the risk of contralateral breast cancer (CBC) is:

- BRCA 1 or 2 gene carrier: 2 - 3% per annum (20-30% at 10yrs)⁶
- Woman with no significant FH: 0.5% per annum (5% at 10yrs)⁵

These risks are reduced by 50-70% by use of Tamoxifen or aromatase inhibitors if the index cancer is ER positive⁷.

CM will reduce the incidence of a new contralateral breast cancer primary by 90-95% but this is unlikely to give any survival advantage as this has been determined by the prognosis of the presenting cancer. The lack of overall survival benefit should be emphasised to the patient as part of the counselling process.

Any new contralateral cancer is likely to be early and screen detected as part of the post cancer surveillance for the index cancer.

The greater risk of needing chemotherapy is for systemic relapse rather than a contralateral breast cancer.

If possible defer decisions about CM until the treatment of the primary breast cancer is complete.

RISKS

- Increased complications including chronic pain and need for multiple surgeries⁵
- Impact of unilateral radiotherapy on reconstructive symmetry
- Potential delay of adjuvant therapies for cancer
- Up to half of women express problems with femininity and sexuality^{8,9,10,11}

BENEFITS

- Less screening
- Aesthetic symmetry
- Psychological: reduction of anxiety^{8,12}

INDIVIDUALISED RISK ASSESSMENT AND STRATIFICATION (IF REQUIRED)

The current predicted average life span for women in the UK is 83 years¹² but 80 years can be used for ease of calculation when estimating the life time risk of developing CBC.

Life span will obviously be affected by the index cancer.

Determine :

- Prognosis from index cancer at 10 years ([Predict NHS](#))
- Prognosis from index cancer + Co-morbidities at 10 years ([Adjuvant online](#))
- Risk of CBC :
 - BRCA status: 20-30% risk at 10 years, 40-60% at 20 years etc^{6,13}
 - Baseline risk 5% risk at 10 years, 10% at 20 years etc
 - The above risks can be increased by
 - FH (RR1.5-3.5)¹⁴, young age at diagnosis²
 - previous mantle RT(RR 2.7)¹⁵
 - lobular histology +FH (RR2.0)
 - ER negative (RR1.3)¹⁶
 - The above risks can be reduced 50-70% by Endocrine therapy^{2,7,16} Oophorectomy before 40 years, early menopause (<45 years)

Low risk : < 10% remaining life time risk of CBC

Population risk: 10 -20% remaining life time risk of CBC

Moderate risk : 20 -30% remaining life time risk of CBC

High risk: >30% - remaining life time risk of CBC

SUMMARY STATEMENT:

CONTRALATERAL MASTECTOMY FOR UNILATERAL BREAST CANCER

Although these risk calculations are not validated, they are used on a regular basis by the Manchester Group and have been published¹⁷

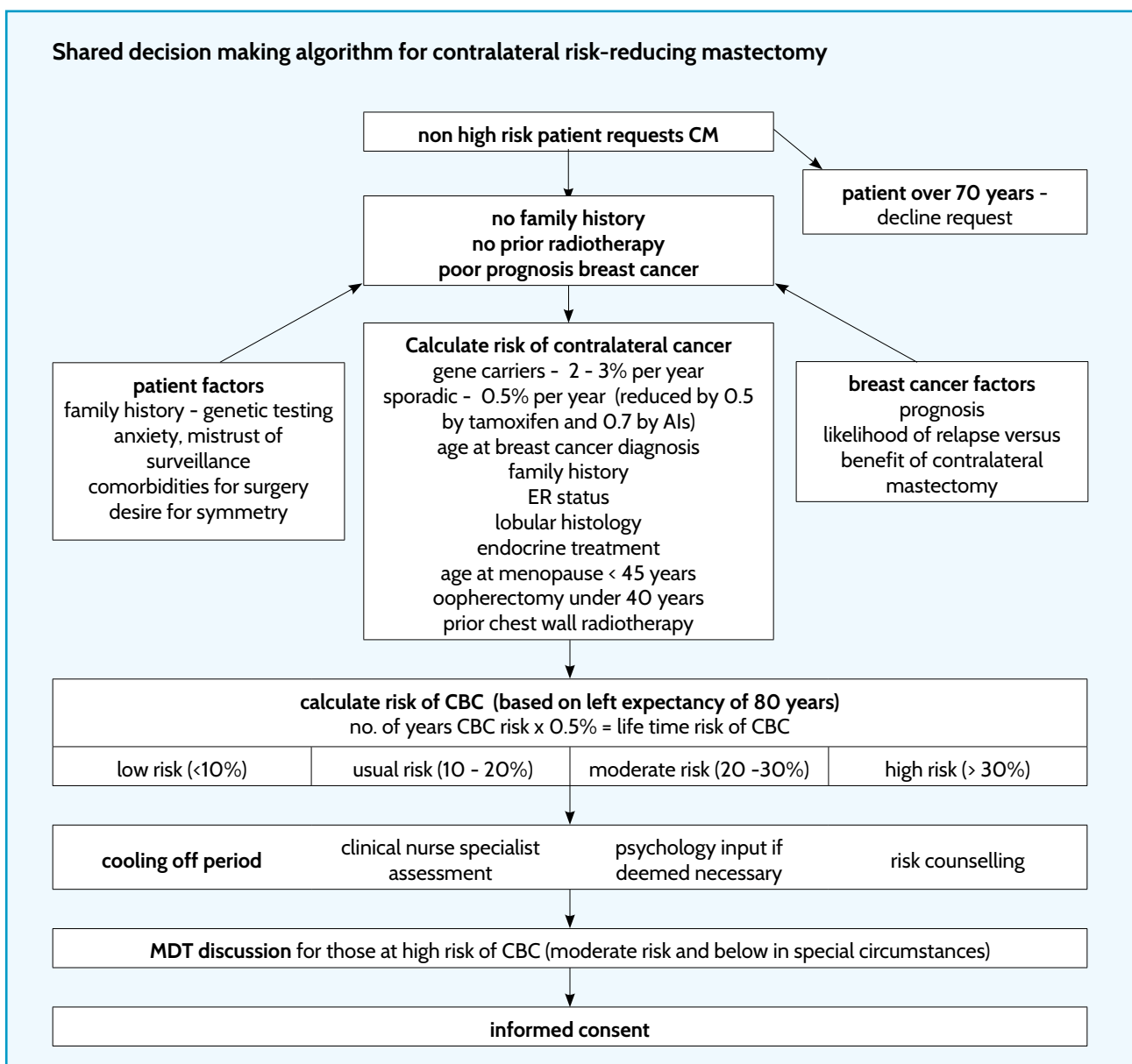
RELATIVE INDICATIONS FOR CM

For a small number of women CM will be reasonable recommendation because of CBC risk but other women will request CM regardless of risk¹⁸. Their reasons need to be explored by and the request ideally assessed by the breast MDT, preferably with genetic and psychological input if considered necessary.

- moderate to high risk of CBC
- low- population risk but risk averse and fully counselled
- to avoid screening uncertainties
- to achieve symmetry with or without implants or use of generous abdominal donor site autologous flap

The incidence of unexpected occult invasive breast cancer in contralateral mastectomy specimens is 1.8%¹⁹ and as such routine sentinel node biopsy is not required.

Although women may request bilateral mastectomy for unilateral cancer, not all CCGs will fund bilateral reconstruction in low risk cases.



SUMMARY STATEMENT:

CONTRALATERAL MASTECTOMY FOR UNILATERAL BREAST CANCER

Authors:	Maria Bramley, Matthew Barber, Clare Fowler, Elisabeth Grimsey, Jennifer Hu, Fiona MacNeill, Philip Drew, John Benson, Nicola Roche and Ashu Gandhi
Produced:	March 2017
Version:	1

REFERENCES

1. Katz SJ, Morrow M. Contralateral Prophylactic Mastectomy for Breast Cancer. Addressing Peace of Mind. *JAMA* 2013;310(8):793-794
2. Nichols HB, Berrington de Gonzalez A, Lacey JV, et al. Declining incidence of contralateral breast cancer in the United States from 1973 to 2006. *J Clin Oncol* 2011; 29 (12): 1564 – 9
3. Neuburger J, MacNeill F, Jeevan R, et al. Trends in the use of bilateral mastectomy in England from 2002 to 2011: retrospective analysis of hospital episode statistics. *BMJ Open* 2013; 3(8): e003179
4. Guth U, Myrick ME, Viehl CT, et al. Increasing rates of contralateral prophylactic mastectomy – a trend made in USA? *EJSO* 2012; 38(4): 296–301
5. Benson JR, Winters ZE. Contralateral prophylactic mastectomy. *BJS* 2016; 103: 1249-1250
6. National Institute for Health & Clinical Excellence. Clinical evidence review familial breast cancer: Classification and care of women at risk of familial breast cancer and management of breast cancer and related risks in people with a family history of breast cancer. Update of clinical guideline 14 and 41. 2013. UK National Collaborating Centre for Cancer
7. Cuzick J, Sestak I, Baum M, et al. Effect of anastrozole and tamoxifen as adjuvant treatment for early-stage breast cancer: 10-year analysis of the ATAC trial. *The Lancet Oncology* 2010; 11(12): 1135–1141
8. Frost MH, Slezak JM, Tran N, et al. Satisfaction After Contralateral Prophylactic Mastectomy: The Significance of Mastectomy Type, Reconstructive Complications, and Body Appearance. *Journal of Clinical Oncology* 2005; 23(31): 7849-7856
9. Frost MH, Hoskin TL, Hartmann L, et al. Contralateral prophylactic mastectomy: long-term consistency of satisfaction and adverse effects and the significance of informed decision-making, quality of life, and personality traits. *Ann Surg Oncol* 2011; 18(11): 3110–6
10. Altschuler A, Nekhlyudov L, Rolnick S, et al. Positive, negative, and disparate-women’s differing long-term psychosocial experiences of bilateral or contralateral prophylactic mastectomy. *Breast J* 2008; 14(1): 25-32
11. Montgomery LL, Tran KN, Heelan M, et al. Issues of regret in women with contralateral prophylactic mastectomies. *Ann Surg Oncol* 1999; 6(6): 546-52
12. Office for National Statistics. www.ons.gov.uk/peoplepopulationandcommunity/birthsdeathsandmarriages/lifeexpectancies/datasets/lifeexpectancyatbirthandage65bylocalareasintheunitedkingdomtable3ukandlocalareasinnorthernireland
13. Metcalf K, Lynch HT, Ghadirian P, et al. Contralateral Breast Cancer in BRCA1 and BRCA2 Mutation Carriers. *J Clinical Oncology* 2004; 22(12): 2328-2335
14. Reiner AS, John EM, Brooks J et al. Risk of Asynchronous Contralateral Breast Cancer in Noncarriers of BRCA1 and BRCA2 Mutations with a Family History of Breast Cancer: A Report From the Women’s Environmental Cancer and Radiation Epidemiology Study. *Journal of Clinical Oncology* 2013; 31(4): 433-439
15. de Bruin ML, Sparidans J, van’t Veer M, et al. Breast Cancer Risk in Female Survivors of Hodgkin’s Lymphoma: Lower Risk After Smaller Radiation Volumes. *Journal of Clinical Oncology* 2009; 26: 4239-4246
16. Saltzman BS, Malone KE, McDougall J, et al. Estrogen receptor, progesterone receptor, and HER2-neu expression in first primary breast cancers and risk of second primary contralateral breast cancer. *Breast Cancer Res Treat* 2012; 135: 849-855
17. Basu NN, Ross GL, Evans DG, et al. The Manchester guidelines for contralateral risk-reducing Mastectomy. *World J Surg Oncol* 2015; 13: 237
18. Rosenberg SM, Sepucha K, Ruddy K, et al. Local Therapy Decision-Making and Contralateral Prophylactic Mastectomy in Young Women with Early-Stage Breast Cancer. *Ann Surg Oncol* (2015); 22: 3809-3815
19. Nagaraja V, Edirimanne S, Eslick G. Is Sentinel Lymph Node Biopsy Necessary in Patients Undergoing Prophylactic Mastectomy? A Systematic Review and Meta-Analysis. *Breast Journal* 2016; 22(2): 158-165