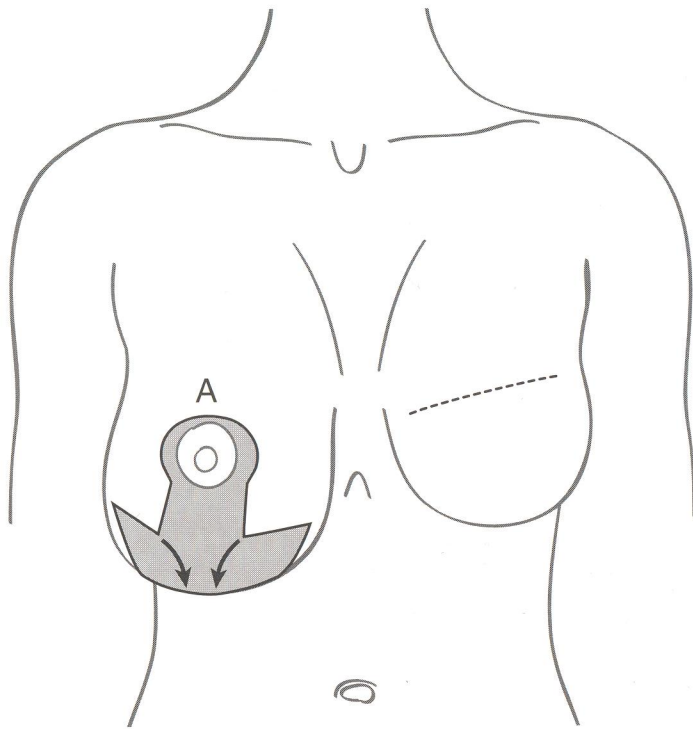


The inferior pedicle markings used for mastopexy

If the breast is ptotic, rather than being very much larger than the opposite side, the same skin markings can be used to create a higher and firmer breast. The entire area within the keyhole and inferior triangles can be de-epithelialised before the lateral margins are incised and repositioned to create the new breast shape.

10



Closure I

When the nipple and areolar pedicle is moved up into place, the '12 o'clock position' on the areola is sutured into place at point 'A' with subcutaneous sutures. The pedicle is pulled upwards, and the lateral flaps are overlapped over the pedicle. At this stage adjustments should be made to ensure that there is not excessive bulk medially or laterally, and that the flaps are thin enough to overlap the pedicle.

11

