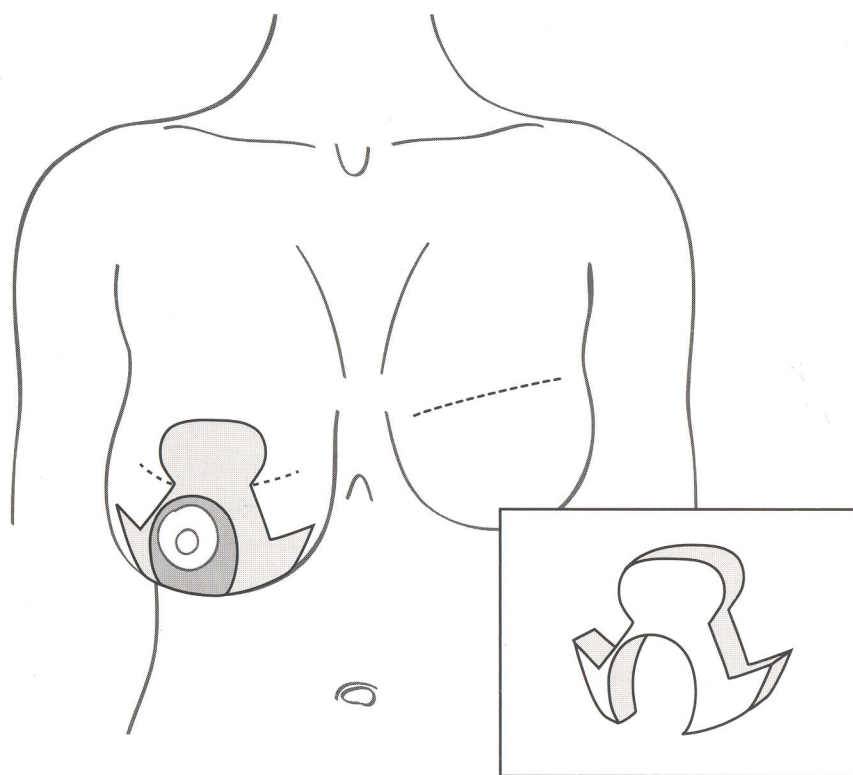


8



### Making the initial incision

The outer margins of the breast tissue excision are marked by the keyhole pattern above and the medial and lateral triangles below. The pattern of tissue excised is arch-like. The pedicle around the nipple and areola is de-epithelialised, leaving full thickness bulk behind the nipple and areola to preserve neurovascular connections.

### Assembling the reduced breast

Following removal of the breast tissue, the shape and thickness of the flaps can be checked. It is important that the medial and lateral flaps are reasonably thin, because they will overlap and lie on top of the pedicle. There should be a full thickness excision within the rounded part of the keyhole in order to accommodate the top of the nipple and areolar pedicle when it is moved up.

9

