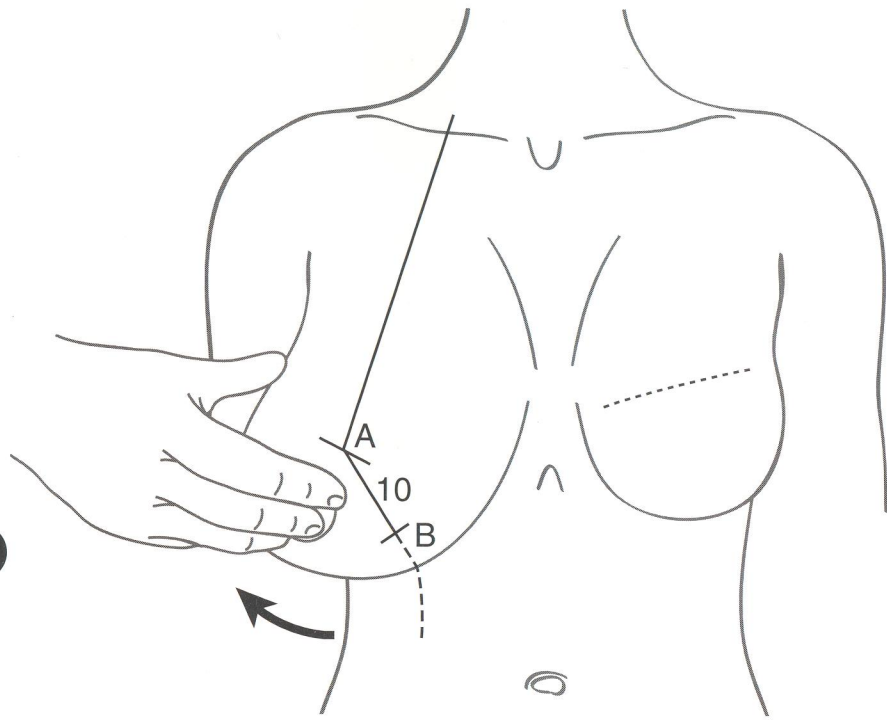


4



Marking the medial vertical incision

The examiner displaces the breast laterally from the point 'A' which is the '12 o'clock position' of the new areola. A line is dropped down to meet the point on the chest wall where the projected breast meridian crosses the inframammary crease. With the patient standing and the breasts dependent, a 10 cm mark is made on this line. Point 'B' on this line will join up with the intersection of the breast meridian and inframammary crease on the chest wall after resection of tissue.

Marking the lateral vertical incision

The examiner displaces the breast medially, and projects the line down from 'A' to pass lateral to the nipple and areola, to create another 10 cm incision line which will meet with the point 'B'.

5

