

Standards and datasets for reporting cancers

Dataset for histopathological reporting of breast disease in surgical excision specimens of breast cancer

November 2024

Authors: Dr Rahul Deb (Chair), University Hospitals of Derby and Burton, Royal Derby Hospital
 Professor Sarah E Pinder (Deputy), Kings College London, School of Cancer & Pharmaceutical Sciences
 Dr C Boyd, Belfast Health and Social Care Trust laboratory
 Professor G Callagy, National University of Ireland (NUI) Galway
 Dr P J Carder, Bradford Royal Infirmary
 Dr AHS Lee, Nottingham University Hospitals NHS Trust
 Dr Y Mir, Royal Liverpool University Hospitals Foundation Trust
 Dr E Provenzano, Cambridge University Hospitals NHS Foundation Trust
 Professor C Quinn, St Vincent’s University Hospital
 Professor E Rakha, Nottingham University Hospitals NHS Trust
 Professor A Shaaban, Birmingham NHS Foundation Trust, University Hospitals Birmingham NHS Trust
 Dr B Tanchel, Birmingham Heartlands Hospital

| | |
|-------------------------------|---|
| Unique document number | G148 |
| Document name | Dataset for histopathological reporting of breast disease in surgical excision specimens of breast cancer |
| Version number | 3 |
| Produced by | The authors are members of the Guidelines Working Group of the UK National Coordinating Committee for Breast Pathology, |



| | |
|-----------------------------|--|
| | <p>which leads on developing pathology guidance for the NHS Breast Screening Programme (NHSBSP) and for preparation of dataset standards in breast cancer pathology for the Royal College of Pathologists.</p> <p>Dr R Deb (lead author) is a consultant histopathologist at the University Hospitals of Derby and Burton. Professor S E Pinder (Deputy) is a professor of pathology at King’s College London. Dr C Boyd is a consultant pathologist at Belfast HSC Trust laboratory. Professor G Callagy is a professor of pathology at NUI Galway. Dr P Carder is a consultant pathologist at Bradford Royal Infirmary. Dr AHS Lee is a consultant pathologist at Nottingham University Hospitals NHS Trust. Dr Y Mir is a consultant pathologist at Liverpool University Hospitals Foundation Trust. Dr E Provenzano is a consultant pathologist at Addenbrooke's Hospital Cambridge. Professor C Quinn is a University College Dublin clinical professor at St Vincent’s University Hospital. Professor E Rakha is a professor of breast pathology at Nottingham City Hospital. Professor A Shaaban is a professor of cancer and genomic sciences at University Hospitals Birmingham. Dr B Tanchel is a consultant pathologist at University Hospitals Birmingham.</p> |
| Date active | November 2023 (to be implemented within 3 months) |
| Date for full review | November 2026 |
| Comments | <p>This document will replace the 2nd edition of the <i>Pathology reporting of breast disease in surgical excision specimens incorporating the dataset for histological reporting of breast cancer</i>, published in June 2016.</p> <p>In accordance with the College’s pre-publications policy, this document was on the Royal College of Pathologists’ website for consultation from 1 May to 29 May 2024. Responses and authors’ comments are available to view on request.</p> <p>Dr Brian Rous Clinical Lead for Guideline Review</p> |

The Royal College of Pathologists
6 Alie Street, London E1 8QT
Tel: 020 7451 6700
Fax: 020 7451 6701
Web: www.rcpath.org

Registered charity in England and Wales, no. 261035
© 2024, the Royal College of Pathologists

This work is copyright. You may download, display, print and reproduce this document for your personal, non-commercial use. Requests and inquiries concerning reproduction and rights should be addressed to the Royal College of Pathologists at the above address. First published: 2024.

Contents

| | |
|---|-----|
| Key changes in this edition | 5 |
| Foreword..... | 5 |
| 1 Introduction..... | 11 |
| 2 Specimen handling..... | 13 |
| 3 Classifying benign lesions | 54 |
| 4 Male breast lesions | 68 |
| 5 Classifying epithelial proliferations | 71 |
| 6 Classifying malignant non-invasive lesions | 86 |
| 7 Classifying invasive carcinoma..... | 102 |
| 8 Core data items | 115 |
| 9 Assessment of hormone receptors..... | 139 |
| 10 Assessment of human epidermal growth factor receptor 2..... | 147 |
| 11 Comments/additional information | 159 |
| 12 Non-core data items | 159 |
| 13 Criteria for audit..... | 160 |
| 14 References | 161 |
| Appendix A RCPATH and NHSBSP breast pathology synoptic proforma template for surgically resected lesions, including dataset and commonly used optional items..... | 179 |

| | | |
|------------|---|-----|
| Appendix B | RCPATH and NHSBSP breast pathology synoptic proforma template for surgically resected lesions, including dataset and commonly used optional items in list format..... | 184 |
| Appendix C | Assessing percentage tumour and total tissue cellularity for molecular testing | 199 |
| Appendix D | TNM classification of tumours of the breast (UICC TNM 8)..... | 201 |
| Appendix E | SNOMED codes for breast pathology..... | 207 |
| Appendix F | Diagnostic immunohistochemistry of the breast | 216 |
| Appendix G | Prognostic classifiers in breast cancer and emerging prognostic and biomarker assays..... | 227 |
| Appendix H | Histological grade monograph | 235 |
| Appendix I | Summary table – Explanation of levels of evidence | 236 |
| Appendix J | AGREE II guideline monitoring sheet..... | 238 |

Key changes in this edition

The entire document has been updated to reflect changing evidence. The key changes in this document are mentioned here. Please refer to the appropriate sections to peruse these in detail.

- The sections on specimen handling have been significantly updated. New sections have been added on handling a range of specimens to include re-excision specimens in different scenarios, some benign specimens and handling operative specimens following neoadjuvant treatment.
- The sections on lobular carcinoma in situ (LCIS) has been updated to include description on variants such as florid LCIS and pleomorphic LCIS.
- Histological subtypes have been updated in line with changes in the 5th edition of the World Health Organization (WHO) Classification of Tumours of the Breast.¹
- A separate section on male breast disease has been added.
- The section on reporting of oestrogen receptor (ER) status has been updated to include ER low status (1–10% positive cells).
- A new appendix on assessing percentage tumour and total tissue cellularity for molecular testing has been added.
- The appendix on prognostic classifiers in breast cancer and emerging prognostic and biomarker assays has been updated.
- TNM staging systems have been modified from UICC TNM 7 to UICC TNM 8.

Foreword

The cancer datasets published by the Royal College of Pathologists (RCPATH) are a combination of textual guidance, educational information and reporting proformas. The datasets enable pathologists to grade and stage cancers in an accurate, consistent manner in compliance with international standards and provide prognostic information, thereby allowing clinicians to provide a high standard of care for patients and appropriate management for specific clinical circumstances. Rarely, it may be necessary, or even desirable, to depart from the guidelines in the interests of specific patients and those special circumstances. The clinical risk of departing from the guidelines should be assessed by the relevant multidisciplinary team (MDT) and the pathologists should be able

to justify doing so. Just as adherence to the guidelines will not necessarily constitute a defence against a claim of negligence, so a decision to deviate from them should not necessarily be deemed negligent.

Each dataset contains core data items that are mandated for inclusion in the Cancer Outcomes and Services Dataset (COSD – previously the National Cancer Data Set) in England. Core data items are items that are supported by robust published evidence and are required for cancer staging, optimal patient management and prognosis. Core data items meet the requirements of professional standards (as defined by the Information Standards Board for Health and Social Care [ISB]) and it is recommended that at least 90% of reports on cancer resections should record a full set of core data items. Other, non-core, data items are described. These may be included to provide a comprehensive report or to meet local clinical or research requirements. All data items should be clearly defined to allow the unambiguous recording of data.

The following stakeholder organisations were consulted during the preparation of the dataset:

- Association of Breast Pathology
- National Co-ordinating Committee for Quality Assurance Radiologists
- Association of Breast Surgery
- NHS Breast Screening Programme
- UK National External Quality Assessment Scheme (UK NEQAS) for immunocytochemistry (ICC).

The information used to develop this dataset was obtained by undertaking a systematic search of literature sources used such as PubMed. Key terms searched included breast cancer and breast disease. Dates searched were between June 2016 and May 2023. Evidence for the revised dataset was obtained from updates to international tumour grading, staging and classification systems. All publications have widespread national and/or international peer acceptance and reflect the current accepted professional standards and practice in breast pathology diagnosis and reporting. Published evidence was evaluated using modified SIGN guidance (see Appendix I). Consensus of evidence in the guideline was achieved by expert review. Gaps in the evidence were identified by College members via feedback received during consultation.

No major organisational changes or cost implications have been identified that would hinder the implementation of the dataset.

A formal revision cycle for all cancer datasets takes place on a 3-yearly basis. However, each year, the College will ask the authors of the dataset, in conjunction with the relevant subspecialty advisor to the College, to consider whether or not the dataset needs to be updated or revised. A full consultation process will be undertaken if major revisions are required, i.e. revisions to core data items (the only exception being changes to international tumour grading and staging schemes that have been approved by the Specialty Advisory Committee on Cellular Pathology and affiliated professional bodies; these changes will be implemented without further consultation). If minor revisions or changes to non-core data items are required, an abridged consultation process will be undertaken whereby a short note of the proposed changes will be placed on the College website for 2 weeks for fellows' attention. If fellows do not object to the changes, the short notice of change will be incorporated into the dataset and the full revised version (incorporating the changes) will replace the existing version on the College website.

The dataset has been reviewed by the Professional Guidelines team, Working Group on Cancer Services and Lay Advisory Group and was placed on the College website for consultation with the membership from 1 May to 29 May 2024. All comments received from the Working Group and membership were addressed by the authors to the satisfaction of the Chair of the Working Group and the Clinical Lead for Guideline Review.

This dataset was developed without external funding to the writing group. The College requires the authors of datasets to provide a list of potential conflicts of interest; these are monitored by the Professional Guidelines team and are available on request. The authors of this document have declared that there are no conflicts of interest.

| Abbreviations, in the order they appear in the text | |
|--|----------|
| Royal College of Pathologists | RCPPath |
| NHS Breast Screening Programme | NHSBSP |
| Ductal carcinoma in situ | DCIS |
| External Quality Assurance | EQA |
| Human epidermal growth factor receptor 2 | HER2 |
| Immunohistochemistry | IHC |
| Multidisciplinary team | MDT |
| Vacuum-assisted excision | VAE |
| Oestrogen receptor | ER |
| Vacuum-assisted biopsy | VAB |
| Magnetic resonance imaging | MRI |
| Complete pathological response | pCR |
| 1-step nucleic acid amplification | OSNA |
| Haematoxylin and eosin | H&E |
| High power field | HPF |
| No special type carcinoma | NST |
| Breast implant-associated anaplastic large cell lymphoma | BIA-ALCL |
| Pseudoangiomatous stromal hyperplasia | PASH |
| Smooth muscle actin | SMA |
| Breast cancer gene | BRCA |
| Atypical ductal hyperplasia | ADH |
| High molecular weight | High MW |

| | |
|---|---------------------------------------|
| Lobular carcinoma in situ | LCIS |
| Atypical lobular hyperplasia | ALH |
| Terminal duct lobular unit | TDLU |
| Fine needle aspiration | FNA |
| World Health Organization | WHO |
| Epithelial membrane antigen | EMA |
| Gross cystic disease fluid protein 15 | GCDFP15 |
| Nottingham Prognostic Index | NPI |
| Union for International Cancer Control | UICC |
| Tumour, node and metastasis | TNM |
| Isolated tumour cells | ITCs |
| Collaborative Trials in Neoadjuvant Breast Cancer | CTNeoBC |
| Residual cancer burden | RCB |
| Progesterone receptor | PR |
| ASCO | American Society of Clinical Oncology |
| College of American Pathologists | CAP |
| National Institute for Health and Care Excellence | NICE |
| Cancer Outcomes and Services Dataset | COSD |
| UK National External Quality Assurance Scheme | UK NEQAS |
| Immunocytochemistry | ICC |
| In situ hybridisation | ISH |
| Ethylenediaminetetraacetic acid | EDTA |
| Fluorescence in situ hybridisation | FISH |
| Chromosome 17 centromeric region | CEP17 |

| | |
|--|-----------|
| Histochemical score | H score |
| Lymph node | LN |
| Deoxyribonucleic acid | DNA |
| Ribonucleic acid | RNA |
| Sentinel node | SN |
| Reverse transcription polymerase chain reaction | RT-PCR |
| Systematized Nomenclature of Medicine Clinical Terms | SNOMED CT |
| Smooth muscle myosin heavy chain | SMMHC |
| Thyroid transcription factor 1 | TTF1 |
| Cytokeratin | CK |
| Tumour infiltrating lymphocytes | TILs |
| Programmed death-ligand 1 | PD-L1 |

1 Introduction

All professional groups involved in the diagnosis and treatment of breast cancer are required to perform at the highest standards to guide appropriate treatment. The quality of pathological services is of the utmost importance; it is the pathologist who makes the definitive diagnosis of breast cancer, but additional features of in situ and invasive carcinomas that have prognostic significance are also required to determine the most appropriate management for individual patients. Thus, the management of patients with breast disease and breast cancer detected through both mammographic screening and with symptomatic presentation depends heavily on the quality of the pathology service. It is relevant to both screen-detected and symptomatic disease.

This document has been produced by the Royal College of Pathologists and updates the NHS Breast Screening Programme's (NHSBSP) guidelines for pathology reporting in breast cancer screening and the College dataset for breast cancer (Reporting of breast disease in surgical specimens, 2016). It serves to give guidance and recommendations on all aspects of pathology examination of breast lesions. As well as being essential for patient management, the adherence to these standards and the provision of accurate information allows breast services and the NHSBSP to be effectively monitored and evaluated. A standard set of data from each patient, using the same terminology and diagnostic criteria, is essential to achieve these objectives. These guidelines, therefore, encourage the use of a common terminology and definitions of breast disease and methods of classifying breast cancer, provided in a standardised, synoptic report.

The reporting forms and the guidance in the following pages were produced after extensive and lengthy consultation with participating pathologists. They define the RCPATH dataset for reporting breast cancer and the complementary NHSBSP dataset for breast screening pathology. The standards of reporting symptomatic cancers are the same as those for reporting screen-detected lesions. The dataset for reporting of breast cancer has been implemented for the following reasons.

- Certain features of invasive breast carcinoma (size, type, grade, lymphovascular invasion, lymph node status) and completeness of excision have been shown to be related to clinical outcome. Consequently, these features may be important in:
 - deciding on the most appropriate treatment for a particular patient, including the extent of surgery and the use and choice of neoadjuvant and adjuvant therapy

- monitoring breast screening programmes, the success of which is reflected by more favourable prognostic features of the cancers detected
- monitoring changing patterns of disease, particularly by cancer registries.
- Classification and grade of ductal carcinoma in situ (DCIS), together with reporting of margins of excision and DCIS size has been shown to be related to the probability of recurrence after local excision and may influence the use of re-excision/mastectomy and adjuvant radiotherapy and endocrine therapy.
- Close correlation of radiological and histopathological features is essential to ensure that mammographically detected lesions have been sampled and accurately diagnosed.

This document also serves to provide guidance for pathologists when participating in the UK breast pathology External Quality Assurance (EQA) scheme. 2 of the major objectives for pathology quality assurance (QA) in the NHSBSP in early years of the programme were to improve the consistency of diagnoses made by pathologists and the quality of prognostic information in pathology reports. To achieve these objectives, a standardised reporting proforma and supporting guidelines for reporting breast pathology were developed jointly by the RCPATH and the NHSBSP. The national breast EQA scheme was set up in parallel as an educational tool and to investigate the level of consistency that pathologists involved in the screening programme could achieve in reporting breast lesions. Clearly, this is determined not only by the performance of the pathologists themselves but also by the methodology they use. Problems identified can be addressed through various initiatives, the success of which can be evaluated in further rounds of the scheme. The EQA scheme now also incorporates a measure of individual performance appraisal.²

In addition, guidance is included in this document on technical laboratory aspects and the reporting of predictive factors, specifically hormone receptor and HER2 status. Sections dealing with the handling of oncological and post-neoadjuvant therapy surgical specimens are included, as are appendices on diagnostic immunohistochemistry (IHC) and on emerging prognostic biomarkers as well as methodology for assessment of tumour cellularity for molecular testing.

1.1 Target users and health benefits of this guideline

The target primary users of the dataset are trainee pathologists, biomedical scientist specimen dissectors (especially specimen handling and dissection sections) and

consultant cellular pathologists and, on their behalf, the suppliers of IT products to laboratories. Secondary users are surgeons, radiologists, oncologists, breast care nurses, hospital cancer centre staff, UK NHS breast screening programmes, breast cancer charities, cancer registries and the National Cancer Registration and Analysis Service. Standardised cancer reporting and MDT working reduce the risk of misdiagnoses and help ensure clinicians have all the relevant pathological information required for tumour staging, patient management decisions and prognosis prediction. Collection of standardised cancer-specific data also provides information for healthcare providers and epidemiologists and facilitates international benchmarking and research.

2 Specimen handling

2.1 General principles

General principles for specimen handling, both in the operating theatre and in the laboratory, should be applied. The type of surgical procedure will be influenced by whether a preoperative diagnosis has been achieved and by the nature of that diagnosis (benign, indeterminate (B3 or B4) or malignant).

If no preoperative diagnosis has been made, the surgical procedure will be in the form of a diagnostic open biopsy/diagnostic excision biopsy (see section 2.5). Surgical quality assurance guidelines indicate that such diagnostic specimens should be confined to removal of the lesion with a minimal amount of surrounding tissue and that these should weigh less than 20 g. Weight must, therefore, be recorded in the histology report. For a large abnormality, only a part will be sampled to avoid leaving a cosmetic defect. The lesion may be impalpable and resection will require image-guided localisation, for example using a guide-wire, radioactive or magnetic seed marker or other method. If a radio-opaque marker has been inserted it is particularly important that this is recorded on the request form.

Frozen section examination is inappropriate for the diagnosis of screen-detected lesions.

If a benign preoperative diagnosis has been made, the lesion may be removed at the patient's request. Such resection specimens should be confined to removal of the lesion with a minimal amount of surrounding tissue, to avoid leaving a cosmetic defect. A wide bore, vacuum-assisted technique for vacuum-assisted excision (VAE) may be used for the resection of some benign and selected indeterminate (B3) lesions.³

If a malignant diagnosis has been made, the aim of the surgical procedure is therapeutic. The type of operation (e.g. wide local excision or mastectomy) will be influenced by the nature, size and location of the lesion, as well as by patient choice. The technique chosen for pathological examination of these specimens requires knowledge of the surgical procedure, the anatomical boundaries of the resection and whether (particularly if the lesion has been detected mammographically) the radiological abnormality is a mass lesion or calcification. Whichever technique is used, the method should enable production of the breast cancer dataset information. This should be collated by the pathologist, if necessary, from the findings from multiple specimens.

Before examining the specimen, the pathologist should ensure that they are aware of any relevant radiological, clinical and previous pathological findings; these should be detailed on the pathology request form.

2.2 Pathology request form

A request form (example in Figure 1) with a standardised approach to its completion for all breast tissue specimens is recommended. Diagrams are very useful. The information provided should be relevant to the specimen type and include, as appropriate, the following, in addition to patient's details/demographic information.

2.2.1 Specimen(s)

- Date and (ideally) time of surgery.
- Side of specimen (right or left).
- Description of the specimens submitted including:
 - number of specimen containers
 - contents/nature of each container
 - relationship to each other, where appropriate.
- The site of the tumour in the breast. In breast conserving surgery specimens, this will assist in identification of the margin nearest to the nipple, if this has not been marked by the surgeon. In mastectomy specimens, it will assist in the identification of small lesions.
- If more than 1 piece of tissue is removed, it must be made clear (e.g. using sutures and/or clips) how the samples are orientated with respect to each other. Diagrams are particularly valuable in this situation.

- Orientation protocol used.
- Method of localisation used; this may include wire, magnetic or radioactive seed localisation method or other. Radioactive specimens should be clearly labelled.
- If any axillary procedure undertaken, the type of specimen: sentinel lymph node biopsy, lymph node sample or axillary clearance; for the latter, the level(s) of dissection.

2.2.2 Clinical findings

- Number of lesions and their size (a diagram can be very helpful, particularly if there are multiple lesions and/or multiple specimens submitted).
- Location within the breast (clock-face/quadrant position).
- Relevant imaging (mammography, ultrasound, magnetic resonance imaging [MRI]) results.
- Whether there is a history of neoadjuvant therapy, including comment on clinical/radiological degree of response. Information about any marker clips/coils, including position, type and number. Diagrams can be very useful.
- Prior biopsy results for each lesion (particularly if performed and reported elsewhere).

Figure 1: An example specimen request form.

| Breast Excision Request Form | | | |
|---|------------------------|--|-----------|
| Please Complete This Request Form Fully and Carefully | | | |
| Surname | Address | | |
| Forenames(s) | | | |
| Unit no. | Sex | | |
| Birthdate | Age | | |
| Consultant | Ward/Dept. | | |
| | | | |
| Specimen | | Specimen | |
| A | _____ | E | _____ |
| B | _____ | F | _____ |
| C | _____ | G | _____ |
| D | _____ | H | _____ |
| Date & time removed | | | |
| i. Orientation Sutures: | | v. Multifocal Tumour Sites & Sizes: insitu / invasive | |
| ii. Shave Present Orientation: | | vi. NACT Original Tumour Size: | |
| iii. Screening case: Y / N | | vii. NAET Original Tumour Size: | |
| iv. Unifocal Tumour Site & Size: insitu / invasive | | | |
| Relevant Clinical History: | | MDT meeting date: | |
| | | | |
| Name of Medical Officer | | Bleep No. | Signature |
| For Laboratory use | | | |
| Date & time received | | Block/Stains | |
| For Lab Audit Use Only | | | |
| Date of cut up | | | |
| Please Initial | | | |
| Rec'd By | Macroscopic Appearance | | |
| Cut Up By | | | |
| Lab Detailed | | | |
| QA By | | | |
| Further Work QA'D BY | | | |
| | | | |

This request is:
 non-urgent
 urgent, date required by: *

Patient Category (please circle)

| | |
|-----------|----------------|
| NHS or PP | IP or OP or DC |
|-----------|----------------|

2.3 Surgical handling

- The majority of therapeutic surgical excisions will include tissue from the skin to the deep fascia. If the surgical resection differs from this, e.g. if dissection does not extend down to the deep fascia or up to the skin when this is the norm, this should be clearly

indicated on the request form, as this will influence the examination of the margins of the specimen.

- The surgeon should orientate all breast cancer resection specimens, both mastectomies and breast conserving surgery with an agreed common code of orientation using either different lengths, or number, of sutures and/or metal staples/clips or ink.
- The nipple extension/direction of the nipple may be separately marked in wide local excision specimens. In nipple-sparing mastectomies, the nipple area should be indicated as it will be examined histologically.
- If clip/suture placement differs from the agreed local protocol this must be clearly stated on the request form.
- Intra-operative specimen radiography is mandatory for impalpable lesions requiring localisation and recommended for all wide local excision procedures.⁴ This allows confirmation of the presence of the abnormality and also its location in the specimen, thus facilitating immediate re-excision if the specimen is close to a margin. The specimen radiographs must be available to the pathologist to view so that they can be certain of the nature of the lesion, e.g. mass, stromal deformity, calcification and the site within the specimen, to facilitate histological sampling.
- It is strongly recommended that the specimen should be sent immediately to the pathology laboratory with an ideal cold ischaemic time of ideally less than an hour. If it is impossible to send the specimen immediately to the laboratory in the fresh state, by mutual agreement, incision(s) by the surgeon from the posterior aspect of large specimens can be very helpful to aid fixation, thus preserving the integrity of key margins while allowing immediate penetration of fixative (Figure 2a). This is most important for mastectomy specimens into which formalin penetration can be particularly poor with consequent effects on mitotic count as a component of histological grade, biomarker expression including ER and the assessment of lymphovascular invasion etc.
- If the specimen is small or if incision of the fresh specimen is not possible, it should be immediately placed in an adequate volume of fixative, at least twice that of the specimen in an appropriately sized container.⁵

[Level of evidence – GPP.]

2.4 Laboratory handling

2.4.1 Fixation

- Good fixation is vital to preserve the morphological detail. This is particularly relevant for the diagnosis of some difficult intraductal epithelial proliferations, classification and prognostication in malignancy (e.g. histological grade (particularly mitotic figures), type and presence of lymphovascular invasion) and expression of biomarkers, e.g. ER.
- As noted, above, it is strongly recommended that the specimen should be sent to the pathology laboratory immediately, with an ideal cold ischaemic time of less than an hour. If it is impossible to send the specimen immediately in the fresh state, by mutual agreement, incision(s) by the surgeon from the posterior aspect of large specimens can be very helpful to aid fixation, thus preserving the integrity of key margins while allowing immediate penetration of fixative (Figure 2a). This is most important for mastectomy specimens into which formalin penetration can be particularly poor with consequent effects on mitotic count as a component of histological grade, biomarker expression including ER, HER2 and the assessment of lymphovascular invasion, etc.
- The benefits of rapid fixation outweigh the desire to preserve the specimen intact prior to examination by the pathologist.
- The plane of maximum dimension of a tumour, if present, should be palpated and identified before slicing to enable incision through the tumour.
- If no tumour is palpable, a mastectomy specimen should be incised as soon as possible after resection at approximately 10 mm intervals, typically in the sagittal plane, to permit rapid fixation of the specimen. Slicing in the coronal plane may be appropriate in some cases, particularly where it may facilitate correlation with imaging findings.
- In mastectomy specimens, incision of the nipple for fixation is recommended. In some centres, the nipple is removed for fixation and to facilitate blocking.
- Following incision, the specimen should be fixed.
- Some centres have adopted a fixative injection methodology to assist in fixation of larger mastectomy specimens, although there is little documented evidence for this. This is considered a reasonable approach when it is impossible to incise the specimen fresh.

- Vacuum-packing and/or refrigeration can also be helpful in delaying autolysis during transport.^{6,7}
- If the specimen is small or if incision of the fresh specimen is not possible, it should be immediately placed in an adequate volume of fixative, at least twice that of the specimen in an appropriately sized container.⁵

2.4.2 Inking

- For wide local excisions, all clinically relevant surgical margins should be inked so that the margins of excision can be easily determined histologically.⁸
- Inking can be facilitated by prior removal of surface lipid by dipping the specimen in alcohol and drying and then applying an appropriate pigment such as India ink, Alcian blue, dyed gelatine or a multiple ink technique.
- Multiple colour ink techniques have advantages, as specific resection margins are still identifiable even if one has to re-examine the wet specimen; this is less valuable for mastectomy specimens, for which most departments would ink only the posterior margin along with the anterior margin of skin-sparing specimens.
- Multiple inks facilitate large block use, if this is available and desired.
- Particularly if only 1 colour ink is used, highlighting a particular edge with clear nicking with a scalpel blade is used in some centres. In other departments, 1 or more nicks are used to identify which blocks are in continuity with each other, for example in a mastectomy specimen.
- Ink can be fixed after painting using 10% acetic acid.

2.4.3 Radioactivity

There is no requirement to delay handling of radioactive specimens for reasons of radiation risk. Procedures for the management of radioactive materials and specimens are at the sole discretion of the Local Radiation Protection Officer. However, it has been shown that from a radiation protection risk perspective, there is no reason to delay handling of radiolabelled sentinel lymph node specimens in view of the low radiation exposure from such samples.⁹ Furthermore, those who handle them do not need to be registered as radiation workers. Any concerns should be discussed with the local Radiation Protection Office. Aside from the pathology dissection issues, the local Radiation Protection Office may provide advice about the transport of specimens to the laboratory

and stipulations about discharge of radioactive material into the waste system, with which the laboratory will need to comply.

Please see individual sections below for further instructions regarding handling of different specimen types.

2.5 Diagnostic localisation excision biopsies

See sections 2.1–2.4 for general principles of laboratory handling and fixation.

Diagnostic localisation excision specimens are submitted when:

- a pre-operative diagnosis has not been made and there are suspicious radiological or clinical findings
- or the pre-operative diagnosis is of an indeterminate (e.g. B3 or B4) lesion and VAE is considered inappropriate or technically not possible
- the sampling technique and the number of blocks taken are clearly dependent on the size of the specimen and the size of the abnormality. If the specimen is small (e.g. less than 30 mm), it is best to block and examine all of the tissue.

The specimen should be inked, weighed, measured in 3 dimensions and then, usually, serially sliced at intervals of approximately 3–5 mm.

Specimens containing impalpable mammographic lesions, such as microcalcification, require specimen slice X-ray examination to facilitate block selection, unless the specimen will be embedded in its entirety.

Images can usefully be annotated to indicate sites of block selection.

Blocks should be taken to enable a measurement of the histological size of the lesion.

Although a diagnostic excision specimen is typically small, if the lesion is larger than can be assessed in a single block, a large block to encompass the maximum dimension may be taken. Whenever taking large blocks it is recommended that at least 1 other normal-sized lesional block should be processed as well, to ensure optimal processing and for ease of IHC/molecular testing.

If the specimen was excised because of radiological calcifications and if, despite thorough or complete sampling, calcifications cannot be seen histologically, X-ray of the paraffin wax block may be helpful to determine their presence, number and location.

2.5.1 Therapeutic surgical specimens

See sections 2.1–2.4 for general principles of laboratory handling and fixation.

The following are relevant to therapeutic surgical specimens:

- It is usual for the surgeon when performing a therapeutic operation to take all of the tissue from the subcutaneous aspect to the pectoral fascia as per surgical guidelines for the management of breast cancer.⁴ As noted above, it is essential that the pathologist be informed if the usual surgical protocol has not been undertaken as this will affect the optimum specimen handling methodology. When tissue remains at the deep (posterior) or superficial (anterior) aspect of the specimen, e.g. as is typical with some central excisions, the distance to these margins is clinically relevant.
- On receipt in the laboratory, the specimen should be weighed and measured in 3 dimensions.
- The specimen should have been incised to allow prompt fixation, ideally in the fresh state (see above and Figure 2a). Excision margins should be inked (see above).
- After fixation the specimen should be carefully examined.
- The direction of additional incisions, after fixation, will depend on the technique for examining and sampling to be used (see methods, below). This choice will depend on the size of the specimen, the nature of the lesion and the pathologist's preference.
- Details of the macroscopic appearances of abnormalities identified should be recorded including tumour size in 3 dimensions and distances to all margins.
- For all methods of sampling (see below), the number of blocks taken will depend on the size of the specimen and the size of the abnormality. If the specimen is small (e.g. less than 30 mm in maximum dimension), it is best to block and examine all the tissue.
- The site of all blocks taken should be recorded in a block key, which should form part of the report.

2.5.2 General principles re macroscopy and tumour size

- It is not possible to be prescriptive, but sufficient blocks of the tumour should be taken to accurately assess important primary characteristics, e.g. size, grade, histological type and lymphovascular invasion.
- For all specimens, sampling should be adequate to assess the size of the lesion. The number of tumour blocks will vary with tumour size but is usually between 3 and 6.

- If multiple tumours are believed to be present, the tissue between these foci should be sampled to facilitate tumour size measurement determine if these are truly separate lesions.
- Large blocks, if available without significant delay to assessment and reporting, can be valuable for accurate determination of microscopic tumour size.
- If large blocks are not easily available, 'routine' blocks across the maximum macroscopic tumour dimension should be taken, so that the tumour size can be measured. A diagram or macroscopic photograph (e.g. with site of blocks marked) may be helpful to indicate how the adjacent blocks relate to each other.
- It may not be possible to define the extent of tumour macroscopically, for example in diffuse lesions like lobular carcinoma. In such cases, either large blocks or consecutive smaller blocks to include adjacent fibrotic tissue may be necessary.
- Sampling should include the extremes of the mammographic abnormality and adjacent tissue to avoid underestimation of size. This is particularly important with cases that have a DCIS component, where mammographic size may underestimate extent. In addition, lymphovascular invasion is most frequently seen peritumourally and should be sought at the edge of the tumour.
- Occasionally, when the plane of maximum dimension of a tumour is not known or is anticipated incorrectly, it may be necessary to add the consecutive slice/block thicknesses, to obtain a tumour measurement; this is likely to be imprecise and the need to try to find the plane of maximum dimension of the tumour prior to slicing is emphasised.
- Primary chemotherapy, prior core biopsy/vacuum-assisted biopsy (VAB), or previous diagnostic excision biopsy, may result in partial tumour removal or complete ablation.
- If the invasive tumour has been completely removed by the core, VAB or diagnostic excision (no invasion or only DCIS remaining), the pathologist should review the relevant previous specimen and provide an estimate of invasive carcinoma size from that.
- The estimate of the invasive tumour size from a previous diagnostic tissue sample is likely to be inaccurate; it should be noted, however, that the carcinoma in these instances of removal by core or VAB is likely to be small (certainly <10 mm).

- Discussion with the radiologist and correlation with MRI, ultrasound and mammographic features (in that order of accuracy) should be undertaken. If there is (residual) DCIS in a therapeutic excision but invasive carcinoma has been removed by previous sampling, it should be noted that radiological assessment of size of invasive focus may be impossible.
- If therapeutic samples are sent in more than 1 portion, it can be difficult to measure the largest extent of the whole lesion and a degree of pragmatism is required. If tumour is present in several pieces of tissue, the maximum dimension in each should be added to give an estimated total size. Typically, the orientation of the specimens can be determined, so size can be ascertained by summation. Discussion with the radiologist at the MDT meeting is helpful and correlation with MRI, ultrasound and mammographic features (in that order of accuracy) undertaken. See also below, re re-excision specimens (delayed or immediate).
- Correlation with the imaging size should be undertaken (ultrasound, MRI or mammographic in that order).

2.5.3 General principles re macroscopy and margins

- All surgically relevant margins of therapeutic excision specimens should be sampled, no matter the macroscopic distance from the lesion.¹⁰
- This will include all radial/circumferential margins (superior, inferior, medial, lateral and nipple margins) and the deep (posterior) and superficial (anterior) margins if dictated by local protocol.
- Particular attention should be paid to the margin nearest the abnormality and the margin nearest the nipple, if marked.
- Large blocks, if available without significant delay to assessment and reporting, can be valuable for assessment of multiple margins in 1 section, depending on the size of the specimen.
- The nearest portion of the anterior margin to tumour in a skin-sparing mastectomy should be sampled, if close.
- The nipple area of a nipple-sparing mastectomy should be submitted for microscopic examination.

[Level of evidence – GPP.]

2.6 Therapeutic wide local excisions

See sections 2.1–2.4 for general principles of laboratory handling and fixation and section 2.5 for assessing tumour size and sampling margins.

Lesions that have a pre-operative diagnosis of malignancy and are deemed to be suitable for breast conserving surgery with regard to clinical/radiological size may be excised as a therapeutic wide local excision.

The technique for examining the specimen and sampling the abnormality will vary according to type and size of specimen and according to pathologist/laboratory preference, therefore flexibility is required. Several options are available. Whichever is used, as an absolute minimum, the information for the breast cancer dataset, including accurate measurement of size and detailed examination of the margin status and distance to margins, must be provided. Figures 2–4 describe the 3 preferred methods for handling these samples.

2.6.1 Wide local excision for malignant lesions presenting as a mass

Method 1: Radial blocks, with or without shave margins

- As shown in Figures 2b and 2c, the specimen may be incised from the deep (posterior) fascial plane in a cruciate fashion through the centre of the tumour, essentially extending the fixation cruciate excisions (Figure 2a). This allows the tumour to be sampled as 4 blocks, which include the medial to lateral and superior to inferior dimensions with the anterior-posterior portions on each of the 4.
- It may be possible to sample the lesion and its adjacent radial margin in 1 block from smaller resections. Larger specimens may require tumour and margin blocking in a large block or 2 (or more) cassettes.
- A block through the lesion to the radial margin will allow measurement of the lesion to the margin distance.
- If the closest margin is the superolateral, superomedial, inferomedial or inferolateral aspect, 1 or more additional radial blocks from this should also be taken.
- After sampling the radial margin blocks, the circumferential edge of a wide local excision specimen can be ‘shaved’ to allow more extensive examination of the radial margins; such shaves are typically sampled after taking the radial tumour blocks to produce a series of additional blocks including: superior shave, supero-lateral shave, lateral shave, infero-lateral shave, inferior shave, infero-medial shave, medial shave

and supero-medial shaved edges, depending on the size of the specimen (see Figure 2c).

- The value of these additional blocks depends entirely on the local definition of adequate excision; as closer margins than previously regarded as adequate are now being accepted (e.g. Association of Breast Surgery recommend 1 mm as sufficient margin width for early invasive cancer.¹¹ Therefore, examination of the cut surface (rather than the external aspect) of such specimens is of limited value, as such portions of tissue are necessarily at least 2–3 mm thick.
- Therefore, if this ‘shave’ approach is used, consideration should be given to embedding the inked, external aspect face down; the presence of disease histologically will indicate its presence less than 1 mm from the margin, but the distance to the margin will not be assessable.

Figure 2a. Cruciate incision of a wide local excision specimen from the posterior deep fascial margin to aid fixation.

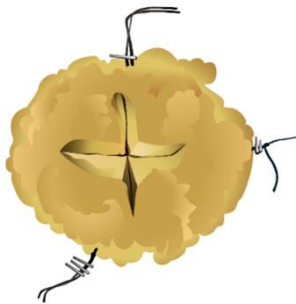


Figure 2b. Cruciate specimen incision method for block sampling.

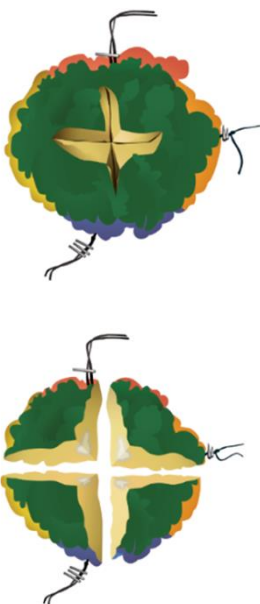
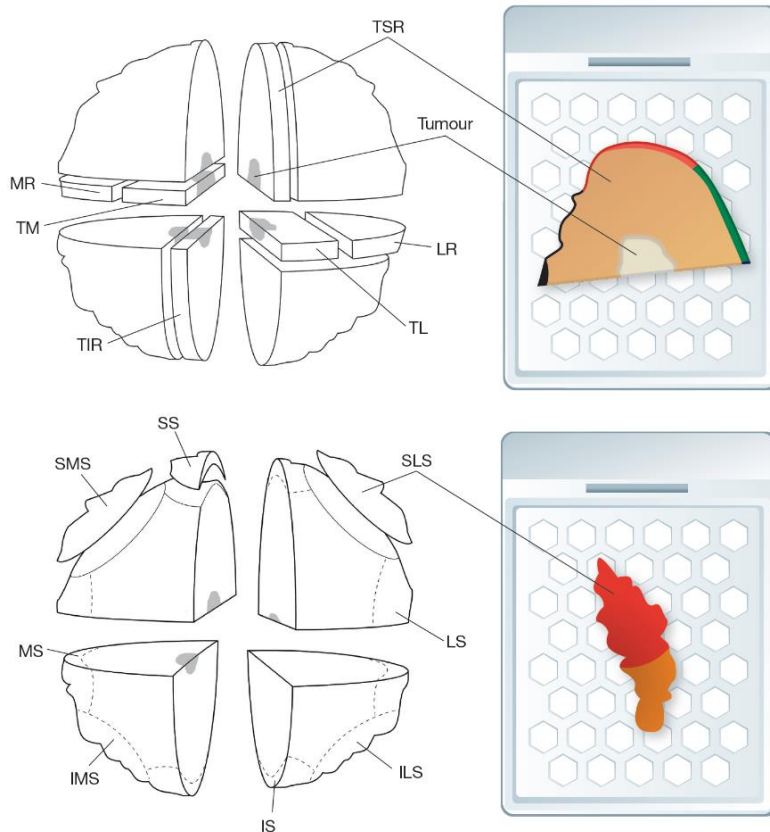


Figure 2c. Cruciate specimen incision method for block sampling indicating example radial and shave margin blocks annotated related to specimen orientation. ILS: inferior lateral shave; IMS: inferior medial shave; IS: inferior shave; LR: lateral resection margin; LS: lateral shave; MR: medial resection margin; MS: medial shave; SLS: superior lateral shave; SMS: superior medial shave; SS: superior shave; TIR: tumour inferior resection margin; TL: tumour lateral; TM: tumour medial; TSR: tumour superior resection margin.



Method 2: Serial slicing perpendicular to the medial–lateral plane (sagittal slicing).

- This method (Figure 3) is commonly used for examination of impalpable lesions, such as microcalcification (see section 2.6.2 below), as it enables specimen slice X-ray mapping of the specimen.
- This method is also frequently used by some pathologists for the assessment of mass lesions.
- The specimen is sliced at intervals of approximately 3–5 mm, perpendicular to the medial/lateral axis in the anterior/posterior plane.

[Level of evidence – GPP.]

Figure 3a: Sagittal slicing specimen examination method with coloured inks used to indicate specimen-orientated margins based on conventional block size.

Wide local excision: sagittal slicing

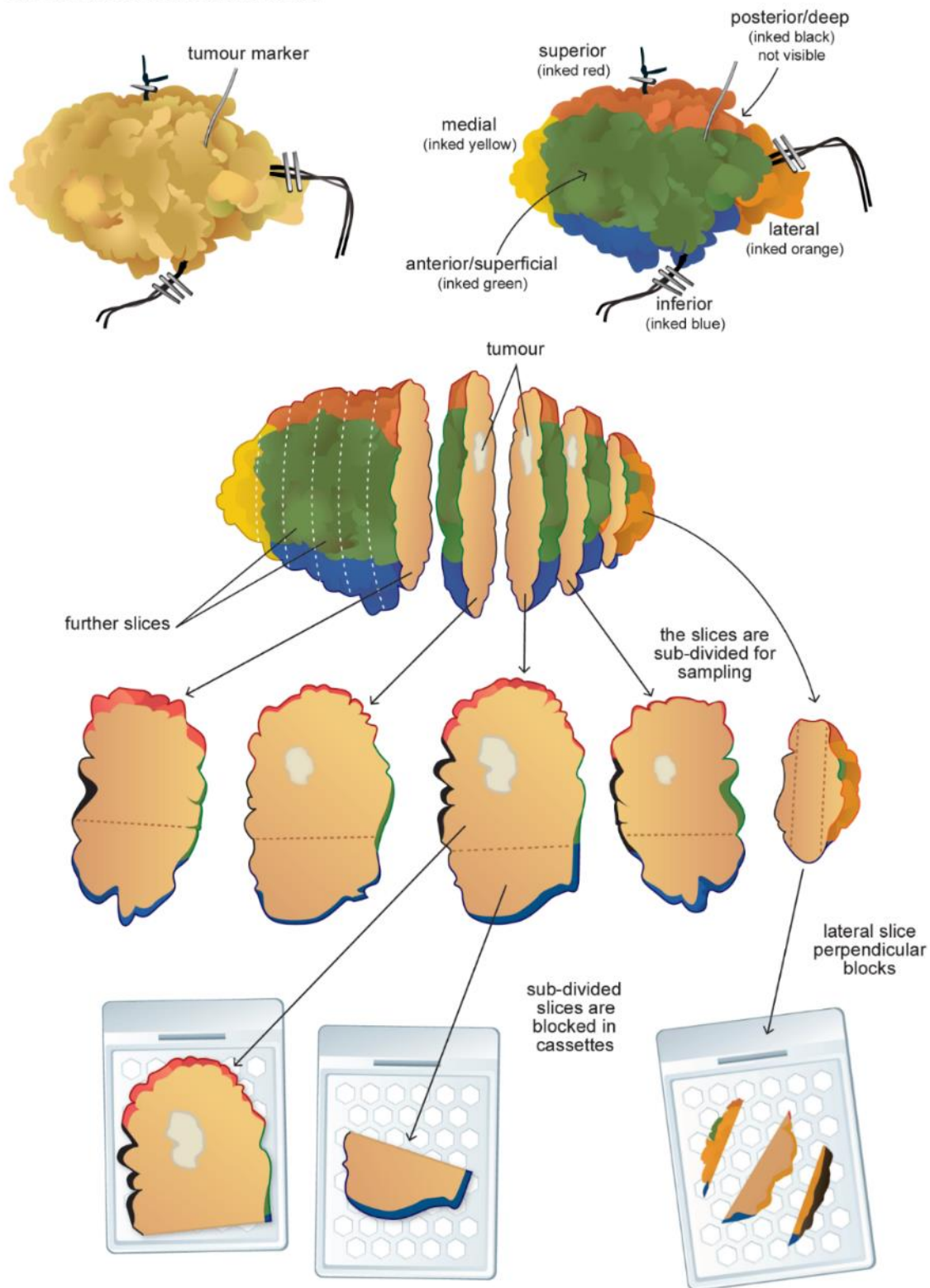


Figure 3b: Sagittal slicing specimen examination method with coloured inks used to indicate specimen-orientated margins and use of large blocks.

Wide local excision: sagittal slicing

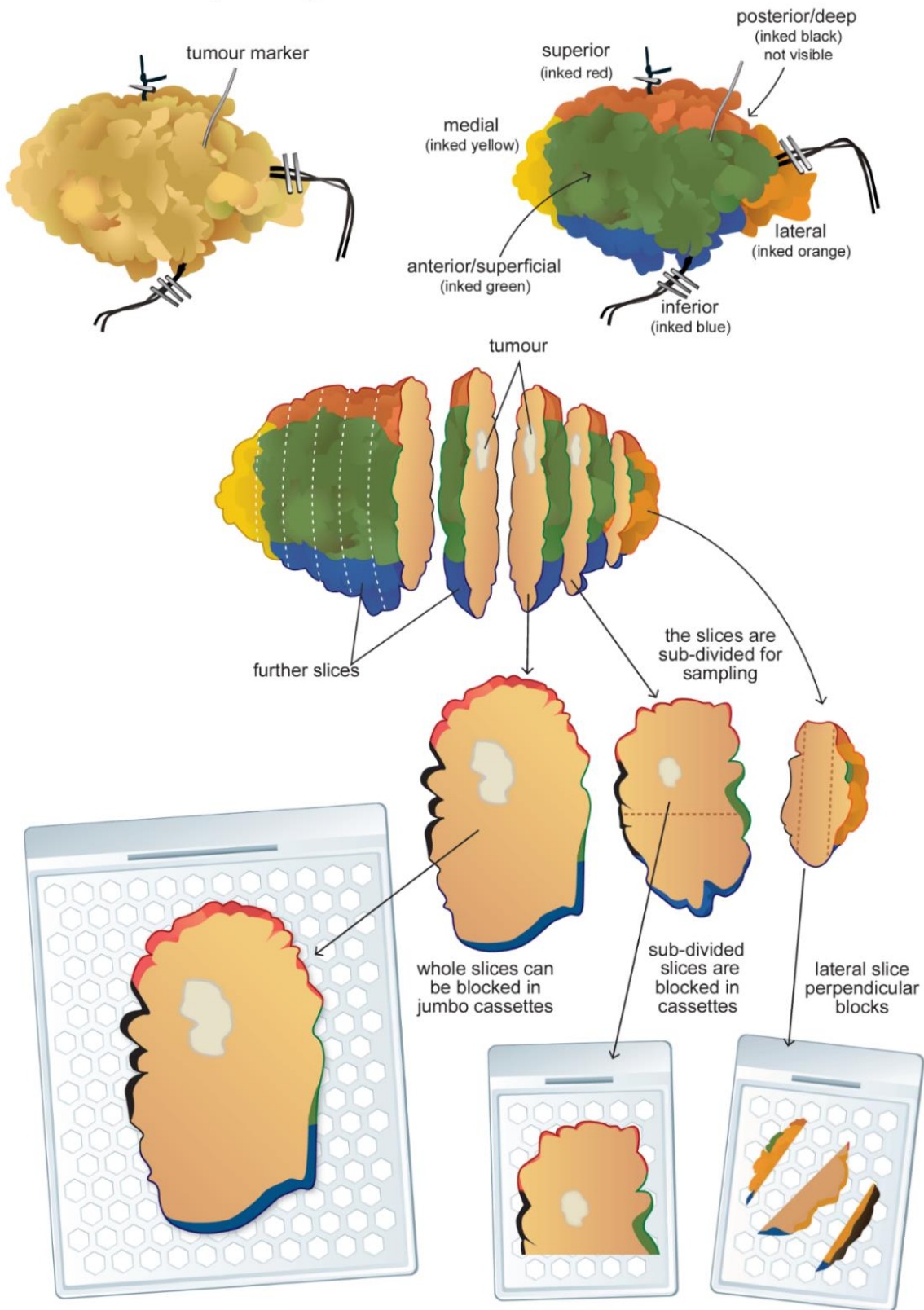
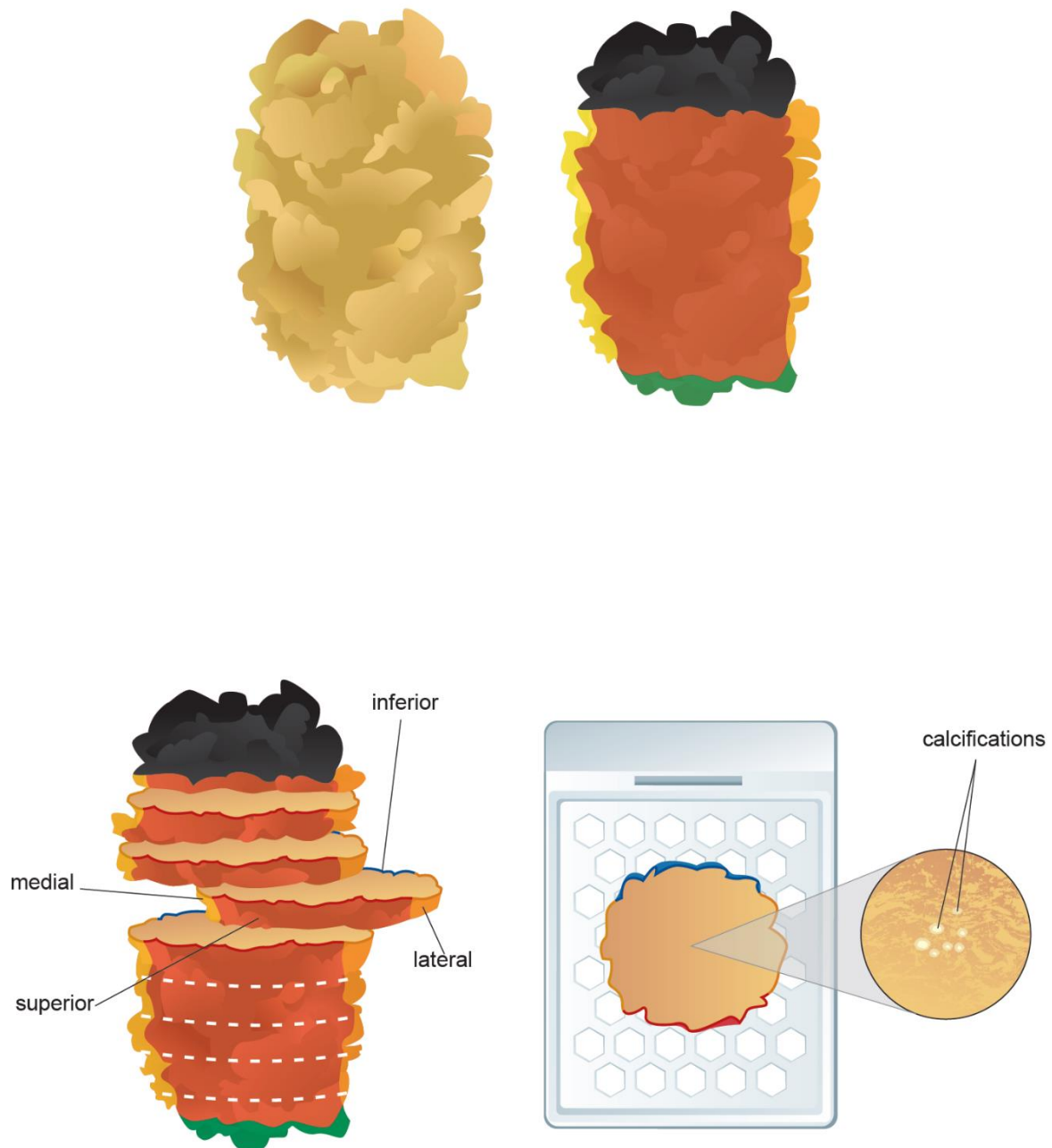


Figure 3c: Sagittal slicing specimen examination method with coloured inks used to indicate specimen-orientated margins relating to an area of microcalcification.

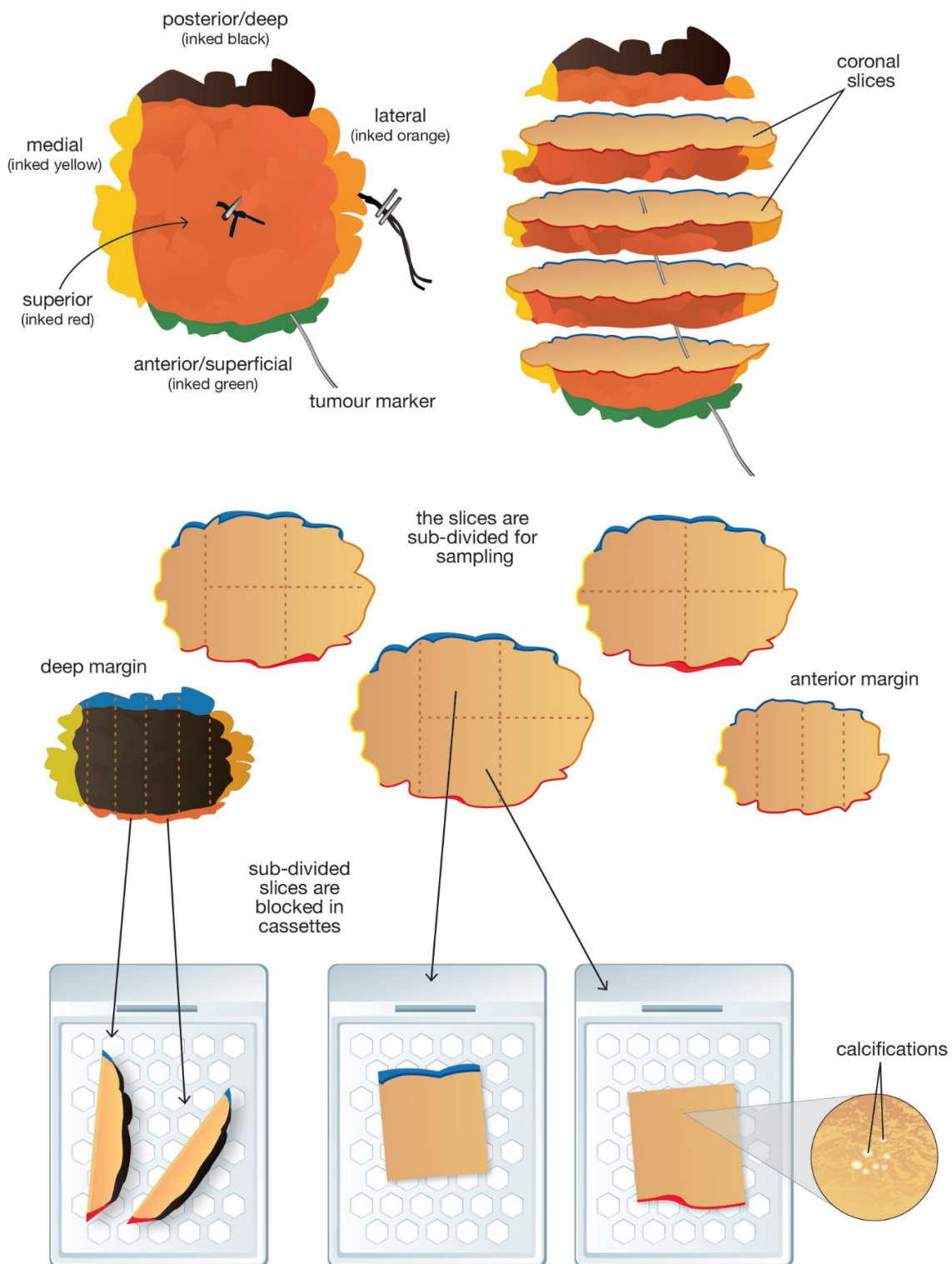


Method 3: Serial slicing perpendicular to the superficial–deep plane (coronal slicing)

- This is a variation of Method 2 and is particularly suitable for smaller specimens when used in association with large block techniques (Figure 4). The entire specimen can be examined as a small number of serial large sections enabling assessment of all radial/circumferential margins on a single section. The technique is similar to the method currently used to examine radical prostatectomy specimens in many centres.

Figure 4: Diagram to illustrate the coronal slicing method with coloured inks used to indicate specimen-orientated margins based on conventional block size.

Wide local excision: coronal slicing with calcifications



2.6.2 Wide local excisions for malignant lesions presenting as mammographic calcification (e.g. DCIS)

See sections 2.1–2.4 for general principles of laboratory handling and fixation and section 2.5 for assessing tumour size and margins.

- DCIS typically presents as a mammographically detected abnormality, usually calcification, which may not be visible on macroscopic examination of the sliced tissue. These specimens are, therefore, typically best handled with serial slicing of the tissue rather than by the cruciate method. Specimens from patients presenting with such lesions will benefit from a combined radiological-pathological approach to diagnosis.
- Orientation of the nipple margin is particularly valuable in cases of known DCIS; DCIS tracks towards the nipple and, in this plane in particular, can be some distance from the main area of microcalcification.¹² It is helpful if the request form indicates the site of the lesion within the breast so that the margin of the specimen nearest the nipple can be identified, if not marked by the surgeon.
- The specimen should have been X-rayed intraoperatively prior to receipt to confirm the presence of the lesion within the specimen. The intraoperative radiographs should be available to the pathologist, who should be aware of the size and location within the specimen of the radiological abnormality and the presence of any radiological markers.
- If the specimen is large, incision posteriorly before fixation is recommended.
- The specimen should be sliced at intervals of approximately 3–5 mm (see Figure 3c). Serial slicing enables specimen slice radiographic mapping to ensure that the mammographic abnormality can be accurately and adequately sampled.
- Macrophotography or schematic diagrams assist in recording macroscopic findings, as well as identifying blocks from sampled margins and for radiological–pathological correlation.
- The site of all blocks taken should be recorded in a block key, which should form part of the report.
- Sampling may be facilitated by the identification of a radiological marker. If a centre uses different methods of marking, it is considered good practice for the surgical team to mention the type of marker used. Tissue changes relating to previous core biopsy are an important landmark to indicate sampling of the site of the index lesion and

should be recorded in the report, particularly if the whole abnormality was removed by the cores.

- The number of blocks taken will depend on the size of the specimen and the size of the abnormality. If the specimen is small, or if slice radiology unavailable, it is best to block and examine all of the tissue. Specimens 30 mm or less in maximum dimension should be embedded in their entirety.
- While specimen slice radiography is invaluable to avoid underestimation of lesion size and inaccurate assessment of the distance to specimen margins, sampling must include not only the extremes of the radiographic calcification but the adjacent tissue. This is particularly important for microcalcifications associated with DCIS, as it is recognised that mammographic size may be an underestimate of the true lesion size. Sampling should include tissue towards the nipple as DCIS frequently extends in this plane.¹²
- Defining the minimum number of blocks that should be taken is impossible; however, it is recommended that 2 blocks per 10 mm of the maximum dimension of the area of calcification be taken, as well as blocks from the immediately adjacent tissue in order to assess DCIS size.
- Although these representative samples (rather than the entire radiological area of concern or indeed the whole specimen) may be taken, sufficient blocks should be taken with the aim of identifying associated occult invasive carcinoma if present.
- Some units use large blocks and if good processing can be achieved and does not significantly delay reporting of the case, these can be valuable in cases of DCIS to assess size of the lesion more accurately.
- In some centres, after inking, fixation and slicing, the slices are laid out, in labelled order, on top of paper towels or similar, in lipped trays or boxes or are vacuum-packed for X-ray. Examination of the specimen slice X-rays enables the pathologist to target the areas with calcification, and those adjacent, for sampling. After X-ray and block sampling, the specimen slices can be stored in the same trays to which a layer of formalin has been added (e.g. with bags around). In other units, the slice order is retained (in case additional sampling is required) by careful wrapping and storage of remaining tissue. These approaches are particularly relevant to cases where no macroscopic abnormality is seen.

[Level of evidence – GPP.]

2.6.3 Additional specimen types from malignant lesions

See sections 2.1–2.4 for general principles of laboratory handling and fixation and section 2.5 for assessing tumour size and margins.

A range of specimens and different terminologies are used for the additional portions of tissue that surgeons may submit from the periphery of a wide local excision. Terms such as cavity shaves, cavity re-excisions, re-excisions and bed biopsies appear to be used synonymously and interchangeably, but not with consistency. In particular, the terms are used differently in different centres, and even between surgeons in an individual unit.

These portions of tissue also vary greatly in size, both between cases and between departments, so for the purposes of this guidance on specimen handling, the term ‘cavity shave’ is used for the small portions of tissue, often taken as routine from multiple radial margins;¹³ ‘immediate re-excision’ is used for larger portions of tissue submitted, usually from 1 or 2 aspects, taken at the same time as the main portion of tissue (wide local excision); ‘delayed re-excision’ is used for those taken at subsequent operation.¹⁴

It is noteworthy that these terms may not be used synonymously in departments and indeed between surgeons in the same unit. It should also be recognised that these vary in size (and in particular in width/thickness) and this should be taken into account in block taking and sampling.

Cavity shaves

In some units, surgeons will often, or always, submit small portions of tissue from all radial margins as routine; for the purposes of this description, these are named ‘cavity shaves’. Cavity shave specimens should be distinguished from more substantive margin re-excision specimens, either immediate or as second operation.

- The site of each specimen should be clearly labelled and each specimen examined separately.
- Specimens should be weighed and measured, particularly noting their thickness, and this should be recorded.
- Cavity shaves are generally a small sheet of fibroadipose tissue such that transverse slicing and laboratory embedding is impracticable and inappropriate. These should be embedded in total, usually in 1 block, without any slicing. Those that are larger thin sheets of tissue may be sliced (transversely), simply to enable submission of all the

tissue. Only exceptionally will these specimens require embedding into more than 1 cassette.

- Cavity shaves may be received with marker suture on 1 surface. If orientated, a local protocol for marking should be established, e.g. suture marks on the cavity side or the new margin.
- If orientated, ideally the new margin should be placed face down for histological examination.
- Inking of such small specimens is not mandatory but can be undertaken for embedding purposes only (e.g. new margin inked to ensure this is examined). If this is performed care should be taken not to ink the internal margin/cavity side.
- Notably, such specimens do not enable assessment of the distance to margins and it is sufficient to comment that disease is, or is not, present in the tissue histologically.

[Level of evidence – GPP.]

Immediate re-excision specimens

The term 're-excision' is used here for larger portions of tissue, usually from a single aspect of the associated wide local excision. This may be taken at the same time as a therapeutic wide local excision ('immediate re-excision') or as a subsequent operation ('delayed re-excision', below). Of note, local terminology may not align with this and some surgeons will use the term 'shaves' for such specimens.

The aim of an immediate re-excision is to remove 1 or more specific margins suspected (e.g. on intraoperative specimen X-ray or due to clinical suspicion) to be involved by the disease process. It should be noted that the specific clinical aim of such specimens is to obtain complete excision of the malignancy.

- The site of the specimen should be clearly labelled.
- Immediate re-excision specimens should be orientated according to local protocol. Typically this will be with a single suture, for example on the cavity side or the new margin aspect. Full orientation, as per the local protocol for a wide local excision specimen, should not be routine.
- Specimens should be weighed and measured, particularly noting their thickness, and this should be recorded.

- The new margin should be inked to facilitate identification histologically. Some units may choose to ink both the new margin and the cavity side, but this is not mandatory.
- Inking with multiple colours as for a therapeutic wide local excision, should not be routinely necessary.
- The immediate re-excision specimen should be sliced transversely at 3–5 mm intervals and examined by eye.
- As above, the procedure of the pathologist taking ‘shaves’ from the external new margin does not facilitate measurement of distance of disease from the new margin and is, therefore, not recommended as routine, given present UK clinical guidelines on minimum margin width defined as ‘complete excision’ of breast malignancy.
- Slicing and embedding of transverse portions facilitates measurement of distance to the new margin histologically as well as extent of any residual malignancy present.
- If the immediate re-excision specimen is small (e.g. approximately 30 mm or less in maximum dimension), after inking and transverse slicing, each slice should be embedded.
- If of a larger size, such that complete sampling is impractical, the transverse slices should be examined macroscopically and any suspicious areas should be sampled.
- As guidance, depending on the specimen size, alternate slices should also be blocked, unless very large when every third slice may be sufficient.
- Pragmatism is required: it may be appropriate to block more, or less, of larger specimens, depending on the anticipated disease sought and the macroscopic distance of disease in the main wide local excision. For example, an immediate re-excision for microcalcifying DCIS that is close to the specified re-excision aspect on a specimen X-ray, should be sampled more than an immediate re-excision for a discrete mass that is macroscopically assessed as being widely excised.
- It is not necessary to embed each slice in a separate cassette, e.g. if more than 1 comfortably fits into a block.
- Blocks should be taken to permit accurate assessment of the adequacy of excision and size of any malignant lesions identified.

- The pathologist should measure the distance of any additional tumour present to the new margin of excision, or to approximate the distance of the original tumour to the new margin of excision if no tumour is present (e.g. margin width is now >5 mm).
- If an immediate re-excision specimen contains further tumour, it can be extremely difficult to determine accurately the overall size of lesion. A pragmatic approach is required; the maximum extent of the tumour from the new margin in the re-excision can be measured and this added to that in the wide local excision to give an approximate total size of tumour. If, however, the orientation of the specimens can be determined, the size of tumour can be ascertained more reliably.
- On some occasions the surgeon will excise an additional portion of tissue, not to specifically obtain complete removal of a malignant process but for cosmetic purposes. Such cosmetic re-excision specimens should be sampled as akin to a breast reduction specimen, rather than as for those excised for oncological purposes.

Delayed re-excision specimens

A 'delayed re-excision' is regarded here as taken at a second (or more) operative procedure. The aim is to remove 1, or more, specific margins known to be involved or overly close (as defined by local protocol) to the disease process or, less commonly, the previous surgical diagnostic biopsy site and its margins. Notably, local terminology may not align with this and some surgeons will use the term 'shaves' for such specimens. It should be noted that the specific clinical aim of such specimens is to obtain complete excision of the malignancy.

- The site of the specimen(s) should be clearly labelled.
- Re-excision specimens should be orientated according to local protocol. Typically, this will be with a single suture, for example on the cavity side or the new margin aspect.
- Exceptionally, if large, or if the entire cavity of previous surgery has been excised (e.g. following previous diagnostic excision surgery), these may be more fully orientated as per local protocol for a wide local excision specimen.
- Specimens should be weighed and measured, particularly noting their thickness, and this should be recorded.
- The new margin should be inked to facilitate identification histologically. Some units may choose to ink both the new margin and the cavity side, but this is not mandatory.

- If the entire cavity of previous surgery has been excised and the specimen has been more fully orientated, the tissue should be inked with multiple colours as for a therapeutic wide local excision.
- The delayed re-excision specimen should be sliced transversely at 3–5 mm intervals and the slices carefully examined macroscopically.
- As above, the ‘shave’ approach to the external new margin does not facilitate measurement of distance of disease from the new margin and is, therefore, not recommended as routine, given present UK clinical guidelines on minimum margin width defined as ‘complete excision’ of breast malignancy.
- Slicing and embedding of transverse portions facilitates measurement of distance to the new margin histologically as well as extent of any residual malignancy present.
- If the delayed re-excision specimen is small (e.g. approximately 30 mm or less in maximum dimension), after inking and transverse slicing, each slice should be embedded.
- If the specimen is large, such that complete sampling is impractical, the transverse slices should be examined macroscopically and any suspicious areas sampled. This is often more difficult than for immediate re-excisions, as there will be surgical changes (such as fat necrosis and fibrosis) and so additional care should be taken with delayed re-excision specimens and more extensive sampling of these compared to immediate re-excisions should be considered. Even if the specimen is large, typically at least alternate slices should be blocked.
- It may be appropriate to block more of larger delayed re-excision specimens, depending on the anticipated disease sought. For example, more sampling of delayed re-excisions for DCIS that extended up to the margin of a previous wide excision is considered appropriate; many departments would block all of such specimens.
- It is not necessary to embed each slice in a separate cassette, e.g. if more than 1 comfortably fits into a block.
- Blocks should be taken to permit accurate assessment of the adequacy of excision and size of any malignant lesions identified.
- The pathologist should measure the distance of any additional tumour present to the new margin of excision, or to approximate the distance of the original tumour to the new margin of excision if no tumour is present (e.g. margin width is now >5 mm).

- If a delayed re-excision specimen contains further tumour, it can be extremely difficult to determine accurately the overall size of lesion. A pragmatic approach is required, and the maximum extent of the tumour from the new margin in the delayed re-excision can be measured and this added to that in the wide local excision, to give an approximate total size of tumour (invasive size and whole tumour size).

2.7 Mastectomy specimens

2.7.1 Mastectomy specimens for malignant lesions presenting as a mass

See sections 2.1–2.4 for general principles of laboratory handling and fixation and section 2.5 for assessing tumour size and margins.

- Invasive carcinomas typically present as mass lesions, which may or may not be clinically palpable, and are usually visible radiologically and macroscopically in the resected tissue (Figures 5a and 5b). The location of the tumour or tumours should be stated on the request form or indicated in a diagram.
- The specimen should be handled according to the general guidance above. It is particularly important for mastectomy specimens that a method should be employed to ensure good and rapid fixation.
- In some centres, the nipple is removed and fixed separately. In some others, the nipple is incised. Both methods aid fixation.
- The tumour is conventionally incised from the deep (posterior) fascial plane in the sagittal plane at a maximum of 10 mm intervals after inking the posterior aspect (Figure 5).
- Differential colour marking of anterior, posterior and radial surfaces is not routinely performed but may facilitate orientation and block taking in skin-sparing mastectomies (Figures 5b and 5c).
- Slicing in the coronal plane from deep (posterior) to anterior (superficial) (Figure 6) may facilitate correlation with imaging findings.
- Alternatively, the tumour may be incised from the deep (posterior) fascial plane in a cruciate fashion allowing the tumour to be sampled as well-fixed blocks, which include the anterior–posterior, medial–lateral and superior–inferior dimensions (Figures 2a and 2b).

- The apparently normal portion of the mastectomy specimens should also be sliced at 10 mm intervals and examined and palpated to identify any additional abnormalities. These should be described and sampled and their position relative to the main mass lesion recorded.
- If multiple tumours are identified, the distance between tumours should be measured and dimensions of each tumour recorded. The tissue between tumour deposits should be sampled to ascertain if the foci are truly separate or, for example, arising within a large area of in situ carcinoma.
- It is not possible to be prescriptive but sufficient blocks of the tumour should be taken to accurately assess important primary characteristics, e.g. grade, type and presence or absence of lymphovascular invasion. The number of tumour blocks taken will vary with tumour size but is usually between 3 and 6 and may relate to specimen examination method (Figure 3 or 5). The edges of the tumour with surrounding uninvolved tissue should also be examined to identify associated DCIS not visible to the naked eye, to permit an assessment of whole tumour size and to search for the presence of lymphovascular invasion.
- Slice specimen radiography may be helpful, or even necessary, to identify calcifying DCIS associated with a mass lesion or located elsewhere in the specimen. This may have been detected preoperatively and identification may be facilitated by the presence of a radiological marker and by macroscopic changes relating to previous core biopsy.
- Large blocks may be helpful in accurately determining whole tumour size, i.e. including surrounding DCIS.
- In addition to areas corresponding to radiological and macroscopic abnormalities, the lateral end of the specimen should be examined by eye and palpation for the presence of intramammary or low axillary lymph nodes.
- The nipple should be examined macroscopically and histologically. At least 1 sagittal section through the skin of the nipple should be sampled in cases with macroscopic or clinical evidence of Paget's disease.
- An effective method to assess nipple duct involvement by DCIS is a coronal section through the nipple which allows visualisation of all nipple ducts in 1 cross section (see Figures 5a–c).

- If the tumour mass or calcification is close to the nipple it is prudent to examine the nipple ducts/nipple; in cases where the tumour or calcification is distant to the nipple, sampling of the nipple–areolar complex can be performed, but it should be noted that this is of limited clinical value.¹⁵
- Measuring the macroscopic distance of the tumour from the nipple can facilitate determination of whole tumour size if the nipple ducts are subsequently found to contain DCIS.
- Any other abnormality in the background breast tissue should be sampled but additional random sampling of quadrants provides limited additional information of clinical value.¹⁵
- The margins of a mastectomy specimen should be examined histologically when the tumour is very close to or abutting a margin.
- In skin-sparing mastectomies the anterior margin is relevant and should be sampled if the lesion is close to that margin.
- In nipple-sparing mastectomies the nipple area should be marked by the surgeon and should be sampled as a shave from that area.

2.7.2 Mastectomy specimens for malignant lesions presenting as mammographic calcification (e.g. DCIS)

See sections 2.1–2.4 for general principles of laboratory handling and fixation and section 2.5 for assessing tumour size and margins.

- DCIS usually presents as a mammographically detected abnormality, most often calcification, which may not be visible on macroscopic examination of the sliced tissue. In mastectomy specimens from patients presenting with such lesions a combined radiological-pathological approach to diagnosis is essential.
- The specimen should be handled according to the general guidance above. It is particularly important for mastectomy specimens that a method should be employed to ensure good and rapid fixation.
- After adequate fixation and slicing, it can be very helpful to X-ray the specimen slices to facilitate identification and accurate sampling of the radiological abnormality. X-raying the specimen in this scenario helps direct rational block taking.

- Accurate localisation of the lesion(s) may be facilitated by the presence of a radiological marker and the identification of macroscopic changes relating to any previous core biopsy.
- The extent of sampling will depend on the radiological size of the lesion. It is anticipated that patients undergoing mastectomy for DCIS will in general have larger DCIS lesions with a greater probability of occult invasive cancer being present. It is therefore suggested that a minimum of 2 conventional blocks per 10 mm of calcification be taken.
- Sampling should include the extremes of the radiographic calcification and adjacent tissue to avoid underestimation of the size of the lesion. This is particularly important as it is recognised that mammographic size may be an underestimate of the true lesion size of DCIS.
- An accurate log of the site of blocks must be recorded and macroscopic photographs or diagrams are helpful for recording block maps.
- Measurement can then be made from block mapping across the main area of calcification and any adjacent (non-calcified) DCIS.
- Any mass should be sampled thoroughly to exclude an associated invasive component.
- Large blocks may be helpful in assessing large areas of DCIS and determining extent accurately.
- The apparently normal portion of the mastectomy specimens should be sliced at 10 mm intervals and examined by eye and palpation to identify any other additional abnormalities that should be described and sampled and their position in relation to the main lesion recorded.
- The lateral aspect of the specimen should be examined and palpated for the presence of intramammary or low axillary lymph nodes.
- The nipple should be examined macroscopically. At least 1 sagittal section through the skin of the nipple should be sampled in cases with macroscopic abnormality and/or clinical evidence of Paget's disease or if DCIS is known (e.g. from pre-operatively imaging) to extend close to the nipple.

- An effective method to assess nipple duct involvement by DCIS is a coronal section through the nipple which allows visualisation of all nipple ducts in 1 cross section. (see Figures 5a–c).
- In cases where the calcification/DCIS is distant to the nipple, sampling of the nipple-areolar complex can be performed, but it should be noted that this is of limited clinical value.
- Measuring the distance of the lesion from the nipple macroscopically can facilitate determination of size if the nipple ducts are subsequently found to contain DCIS.
- Any other abnormality in the background breast tissue should be sampled but additional random sampling of quadrants provides limited additional information of clinical value.¹⁵

[Level of evidence – GPP.]

Figure 5a: Mastectomy specimen examination using sagittal slicing to assist specimen fixation.

Mastectomy (left): sagittal slicing

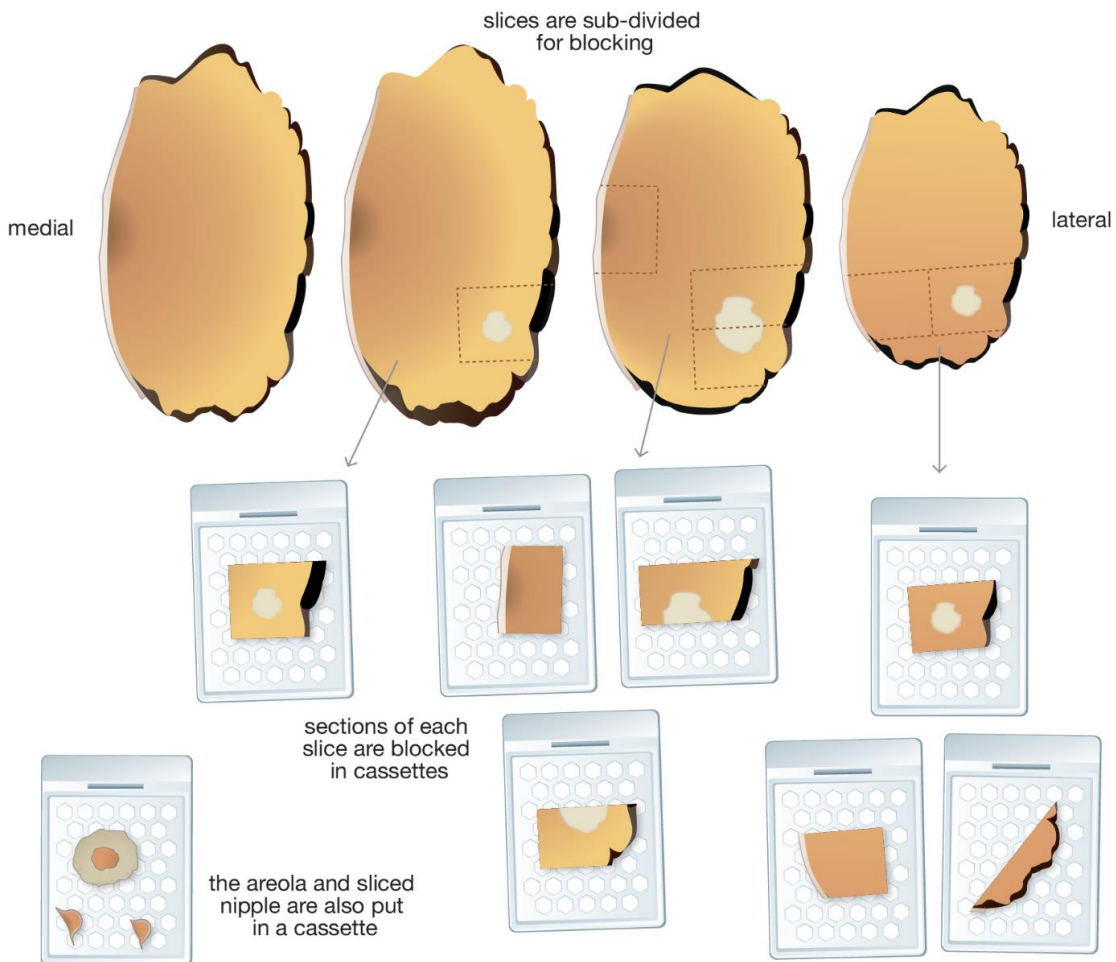
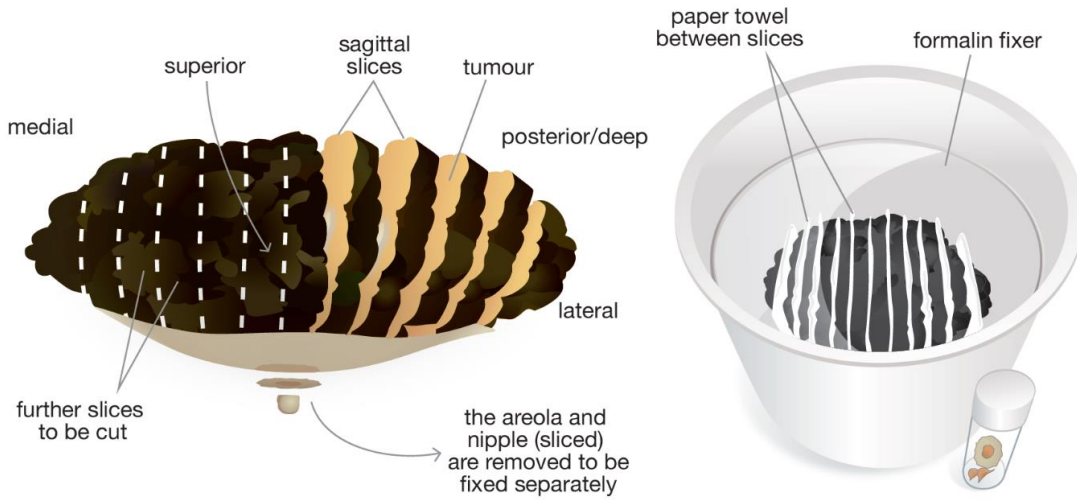


Figure 5b: Mastectomy specimen examination using sagittal slicing to assist specimen fixation (differential inks).

Mastectomy (left): sagittal slicing

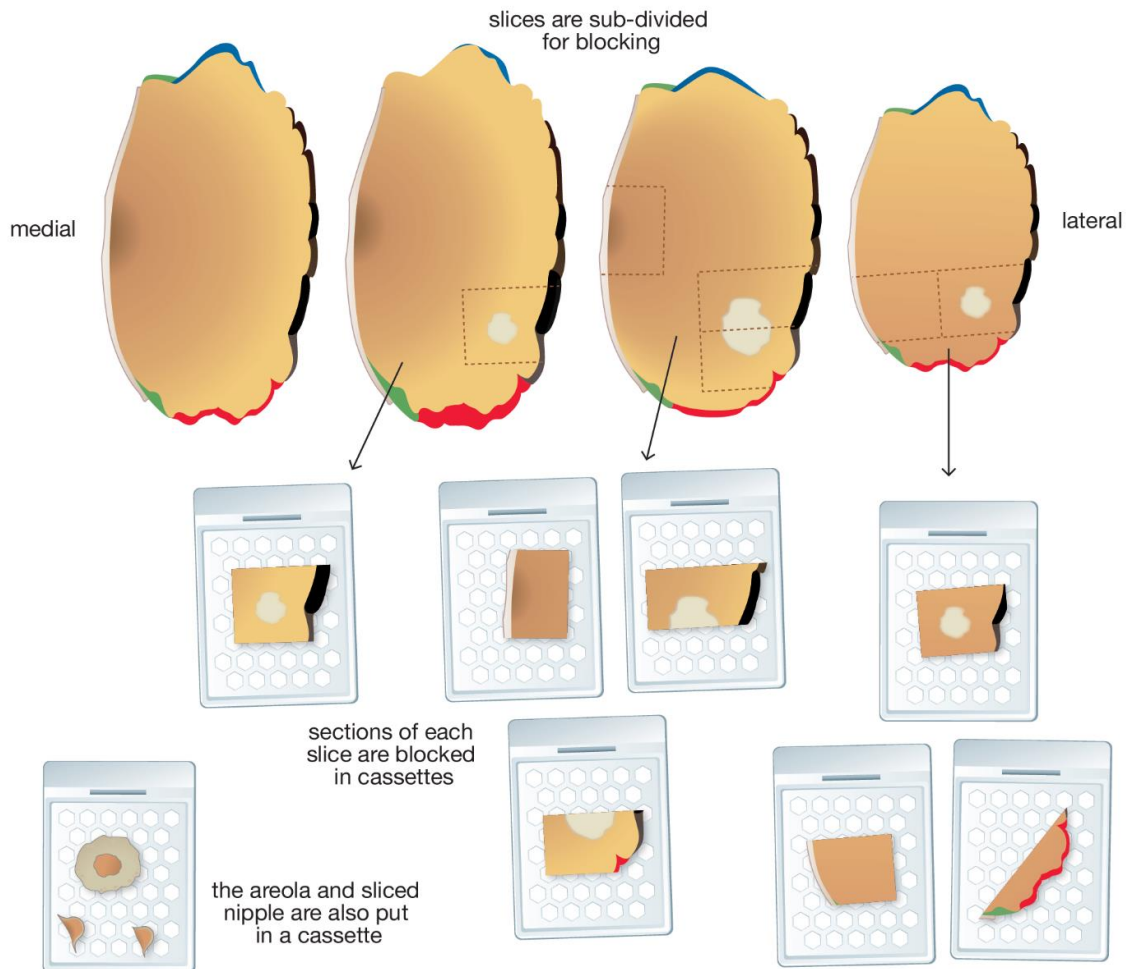
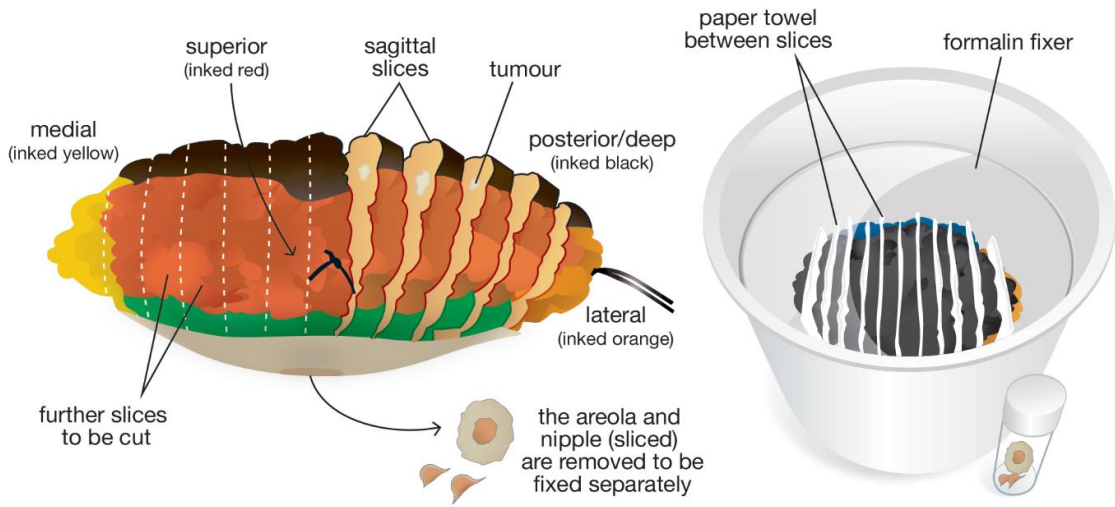
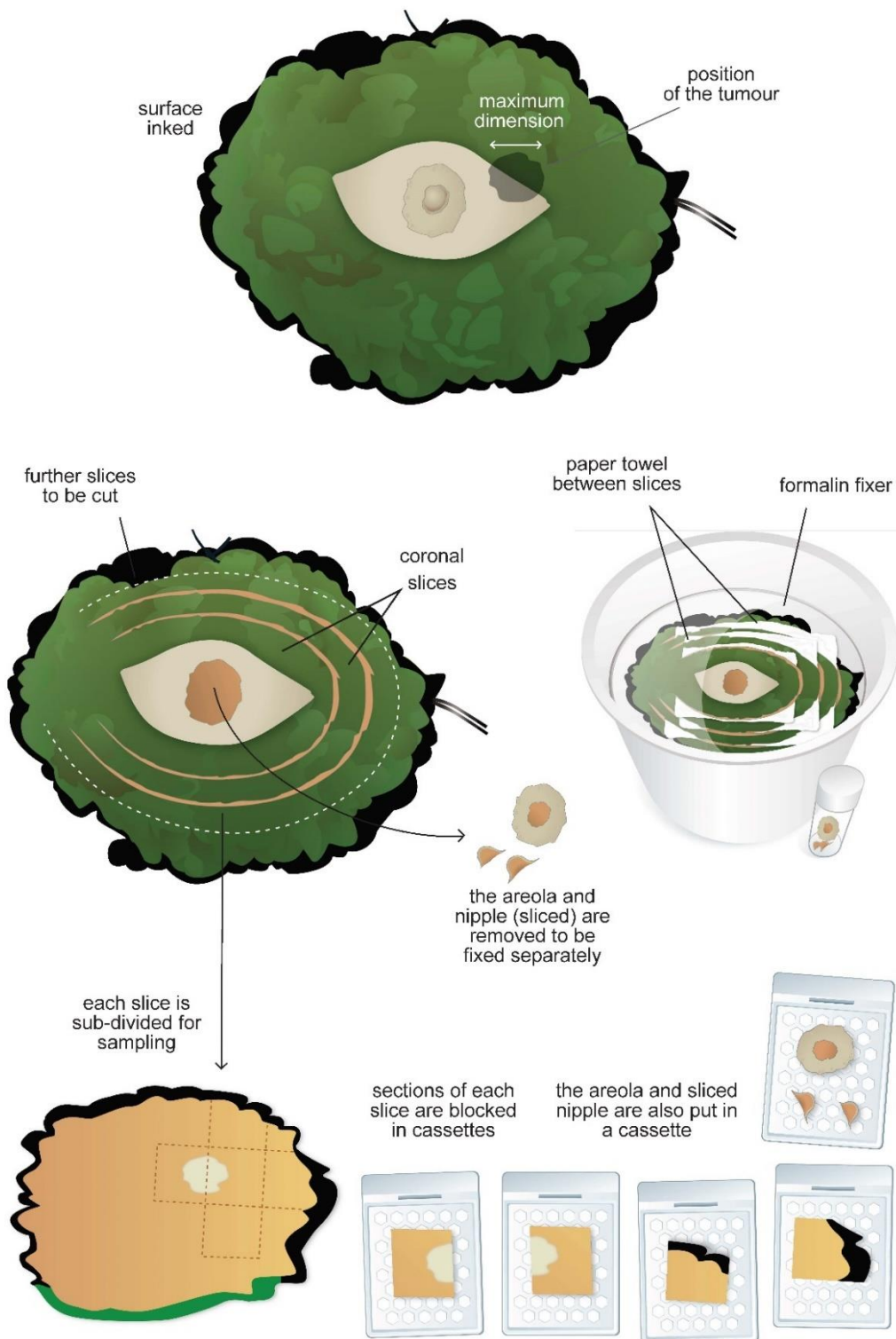


Figure 5c: Mastectomy specimen examination using coronal slicing to assist specimen fixation.

Mastectomy (left): coronal slicing (skin sparing)



2.7.3 Completion mastectomies (following incomplete excision of malignancy in a wide local excision)

See sections 2.1–2.4 for general principles of laboratory handling and fixation and section 2.5 for assessing tumour size and margins.

- The specimen should be fixed, inked and sliced as detailed above for other mastectomy specimens (see section 2.7). The site of the previous surgery will usually be apparent as a cavity lined by haemorrhagic granulation tissue and fat necrosis or an area of scarring.
- Sections should be taken from the walls of the cavity or fibrous scarring to include adjacent breast tissue, especially focusing on any margins previously identified as close/involved in previous surgical specimen(s) and any macroscopically suspicious areas. Reference to previous reports will identify close/involved margins and these areas should be thoroughly sampled. It is difficult to be prescriptive about the number of blocks that should be taken from such specimens as additional invasive disease is unlikely to be clinically relevant, unless the previous wide local excision was for pure DCIS. The presence of further disease may, occasionally, alter tumour size (e.g. in TNM staging systems) and its identification will provide assurance to the surgeon and the patient that the procedure was necessary.
- It is not, however, considered appropriate to block such specimens excessively; a low rate of identification of residual invasive carcinoma may not necessarily imply inadequate sampling.
- The nipple can be sampled, as described above.
- Any other abnormality in the background breast tissue should be sampled, but additional random sampling of quadrants provides limited additional information of clinical value).¹⁵

2.8 Therapeutic excision and mastectomy specimens for invasive carcinoma following neoadjuvant chemotherapy: macroscopic handling

See sections 2.1–2.4 for general principles of laboratory handling and fixation and section 2.5 for assessing tumour size and margins.

While neoadjuvant chemotherapy was historically recommended for patients with large or locally advanced or inflammatory breast carcinomas, this is increasingly being advised for

a range of patients with operable disease, especially HER2 positive or triple negative disease. Working with the other members of the MDT is particularly vital in this setting.

- The macroscopic handling of breast excision specimens following neoadjuvant (primary) therapies can be difficult, particularly if there has been a good or complete response to the systemic treatment. This is especially the case for the post-neoadjuvant chemotherapy specimen, when the situation is more common than following primary endocrine therapy.
- The proper pathological approach to such specimens is, therefore, crucially dependent on knowledge of the previous clinical, imaging and pathological findings, including tumour type and grade and the location of the tumour within the breast. The difficulties in identifying the tumour bed are exacerbated if limited clinical information is provided; for example, if mastectomy is performed and details of the original location of the lesion are not provided on the request form. Similarly, multiple invasive foci may be missed if inadequate information is given to the pathologist.
- The initial laboratory handling of post-chemotherapy specimens should be undertaken in a similar manner to wide local excision or mastectomy specimens from patients not receiving such treatment; for example, they should be orientated and promptly fixed.
- A marker clip or coil should be inserted into the tumour(s) prior to starting treatment. Its localisation within the excised breast tissue can help determine the site of tumour bed. To ensure that this tumour site is completely removed, some units mark the skin to delineate the tumour size prior to treatment, which can also be helpful.
- On palpation and slicing, a mass lesion may be obvious if there has been incomplete response to neoadjuvant therapy and the specimen can be handled as for any other primary resection specimen. When there has been a decrease in tumour size compared with original imaging, additional blocks should be taken from around the residual mass to encompass the pre-treatment area of involvement.
- If there has been a significant tumour response, the lesion may be difficult to identify, both visually and by palpation; a pale, ill-defined, soft, oedematous area of fibrosis may be all that can be detected. With a good or complete pathological response (pCR) there may only be a vague impression that the tissue architecture is abnormal. In such cases the marker, or residual microcalcification, can be seen in specimen X-ray and thus direct the attention of the pathologist to the appropriate area. Usually, the marker can be detected macroscopically on thin slicing of the specimen.

- The tumour bed (as identified by the location of the radiological marker, clinical and radiological information and gross appearance) should be thoroughly sampled to detect residual disease and allow for assessment of the tumour bed in 3 dimensions.
- For large tumours where cruciate blocks cannot easily be taken, assessment of the tumour bed can be achieved by estimation of slice thickness and the number of consecutive blocks involved, along with the 2 dimensions seen histologically.
- A tumour that has responded to chemotherapy may regress focally and appear as multiple apparently separate foci. Representative blocks should be taken from the entire area originally involved by tumour, as residual foci may be scattered throughout it.
- Large blocks, if available, are useful in preserving the tissue architecture. They can facilitate the assessment of multiple foci of invasive carcinoma and the assessment of the amount of residual tumour in relation to the tumour bed, thus aiding an assessment of tumour response.
- The margins of therapeutic wide local excision specimens post-neoadjuvant chemotherapy should be sampled particularly thoroughly.
- Lymph nodes should be blocked as per the guidelines (below) for patients who have not received neoadjuvant therapy, depending on the surgical procedure (i.e. sentinel lymph node, targeted axillary dissection or axillary clearance). Like the lesion in the breast, lymph nodes are often more difficult to identify macroscopically after neoadjuvant treatment. Some units insert a marker into involved nodes prior to chemotherapy. If the biopsied node has been marked pre-treatment, comment should be made regarding identification of the marker site in the resected node.
- There is evidence that there is a decreased yield of nodes in patients who have received neoadjuvant chemotherapy.¹⁶
- Current UK guidance is that intraoperative molecular techniques (e.g. 1-step nucleic acid amplification [OSNA]) should not be used in the neoadjuvant setting.¹⁷

2.9 Oncoplastic specimens

The concept of oncoplastic surgery combines the aim of completely removing the breast cancer while maintaining breast aesthetics by achieving a good cosmetic outcome. While such surgery includes mastectomy with total reconstruction, a variety of techniques for partial reconstruction of defects can be used, which allow the surgeon to remove large

portions of cancer-bearing tissue without compromising cosmesis. Such wide local excision specimens may contain larger tumours than could otherwise be completely removed or the aim of the procedure may be to achieve wider tumour-free margins than could otherwise be obtained.

The principles of examining oncoplastic wide local excisions are the same as for conventional specimens. The carcinoma is sampled in the same way. All margins should be examined histologically but the tumour is usually further from these, so that less exhaustive sampling of the margins is needed. Sampling of re-excision specimens can be limited unless the carcinoma is close to the relevant margin of the main excision specimen.

[Level of evidence – GPP.]

2.9.1 Breast reduction and cosmetic procedures

Breast reduction specimens from patients with breast cancer and risk-reducing (prophylactic) mastectomies should be sampled more thoroughly than cosmetic breast reductions, as the likelihood of identifying a risk or precursor lesion is higher. Mastectomy specimens from patients undergoing gender reassignment surgery should also be examined histologically with the number of blocks sampled depending on other familial and patient risk factors (e.g. age at surgery).

Tissue removed from non-oncoplastic cosmetic breast procedures are generally submitted for pathology examination. It is recognised that there is a low risk of detection of invasive cancer, in situ carcinoma or atypical hyperplasia in such specimens. This risk appears to be higher in patients over the age of 40. Such specimens should be carefully visually inspected, manually palpated and sliced at between 5 and 10 mm thickness. Abnormal areas should be sampled for pathological examination. It is recommended that in general a minimum of 2 tissue blocks is taken for histological examination. Block sampling should be targeted towards white fibrous, potentially parenchymal-rich and non-fatty tissue. In patients with prominent fibrous breast tissue and those over age 40, additional block sampling can be considered.

[Level of evidence – GPP.]

2.9.2 Other specimens

Excision biopsies

- Other than excision of a radiologically detected impalpable lesion for diagnosis and assessment, as described above, excision specimens may be received from patients

with a known benign lesion who have requested removal, for example a fibroadenoma, or where there remains some clinical concern despite a benign pre-operative result.

- The specimen should be inked, weighed, measured in 3 dimensions and then sliced at intervals of approximately 3–5 mm.
- Typically, a lesion will be seen on slicing; the number of blocks sampled from this are dependent on the size of the specimen, the size of the abnormality and pre-operative diagnosis category. For example, it is acceptable to examine only 2 or 3 blocks from a 30 mm fibroadenoma (with a known pre-operative diagnosis). If, however, the lesion is excised because the pre-operative diagnosis is B3, cellular fibroepithelial lesion, more blocks should be sampled.

Microdochectomy/microductectomy

- Microdochectomies/microductectomies are typically excised for patients with single duct discharge, with or without pre-operative diagnosis of a papillary lesion. These are most often thin, sinuous, portions of tissue with a suture present on the anterior aspect. This suture is, however, not generally for orientation purposes but for clinical handling. Nevertheless, this may be useful for pathological handling and the anterior margin may be inked to distinguish this from the 'radial' or deep aspects of the tissue.
- The specimen should be weighed, measured in 3 dimensions and then sliced at intervals of approximately 3–5 mm from the anterior to posterior.
- Often, no lesion will be seen on slicing; in this situation in particular, it is prudent to slice and embed the whole of the tissue (which is not usually large). As noted, the anterior and posterior portions can be separately embedded.
- If an overt lesion is seen then this should be thoroughly sampled, along with the anterior (sutured) and posterior aspects.

Total duct excisions (Hadfield's procedure)

- These specimens are typically received from patients with multi-duct nipple discharge and are received as a disc of fibrofatty tissue from the sub-areolar region. These are not usually orientated, although a suture may be placed by the surgeon, usually on the anterior aspect. The specimen should be weighed, measured in 3 dimensions and then sliced at intervals of approximately 3–5 mm from the anterior to posterior. Often no macroscopic abnormality is seen and it is prudent to simply embed the entire specimen, which is not large.

Capsulectomies

- Breast implant capsules may be excised following implant rupture or leakage; specimens submitted may be a selected portion of or the entire capsule and may thus be a small piece of tissue which can be transversely sliced and embedded in a single cassette or a thick-walled cystic structure from which blocks must be chosen.
- The tissue should be measured in 3 dimensions, with particular attention paid to recording the thickness of the wall.
- Block selection should concentrate on the thickest areas of the capsule; any nodularity should be sampled.
- Anaplastic large cell lymphoma may be seen as a fibrinoid or granular material on the inner aspect of the breast capsule, thickening of the wall or mural nodules and these should all be recorded and sampled.¹⁸
- Transverse slicing with tissue orientation and sectioning on edge allows examination of the entire capsule wall, from the luminal surface to the outer soft tissues.
- The number of blocks taken will depend on clinical suspicion and macroscopic appearances.

2.10 Pathological examination of lymph nodes

Resected lymph nodes, usually axillary and occasionally internal mammary, should be submitted for microscopic examination. These specimens may take the form of axillary clearance specimens, axillary lymph node samples or sentinel lymph node biopsies.

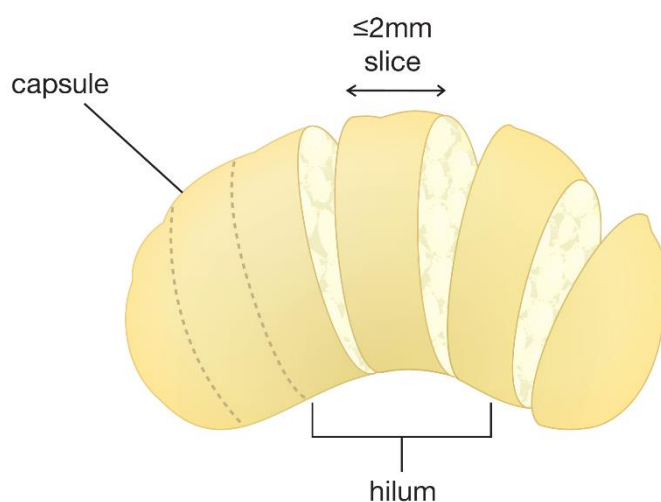
2.10.1 Sentinel lymph node and lymph node sample specimens

- Individual lymph node specimens should be identified separately from the breast sample and placed in clearly labelled specimen containers for routine fixation.
- Each lymph node should be examined and blocked independently; for larger lymph nodes, this may necessitate examination as more than 1 paraffin block but multiple slices from 1 node can be examined in a single cassette.
- The method used should provide the highest chance of finding metastatic disease by conventional microscopic examination of haematoxylin and eosin (H&E) stained sections.
- A representative complete section of any grossly involved lymph node is adequate.

- Lymph nodes greater than 4 mm in maximum size should be sliced at intervals of 2 mm or less perpendicular to the long axis; this is an effective and simpler alternative to serial sectioning to detect small metastatic deposits in lymph nodes (Figure 6).
- Lymph nodes less than 4 mm should ideally be bisected and blocked in their entirety.
- Examination of levels is not routinely necessary. It may be performed if small groups of suspicious cells are identified, if initial sections do not achieve a full-face section, and to determine the maximum size of any metastatic deposits.
- IHC may be helpful if there are cells suspicious of carcinoma seen in the H&E section but is not routinely necessary. If this is required, clone AE1/AE3 is recommended.¹⁹ Reactivity of dendritic reticulum cells and some lymphoid cells may lead to false positive results when using some cytokeratin antibodies and assessment must therefore be based on immunoreactivity and morphological correlation (see Appendix G).

Figure 6: Lymph node slicing perpendicular to the long axis.

Sentinel Lymph Node: slicing perpendicular to the long axis



2.10.2 Axillary clearance specimens

- Axillary clearance specimens should be placed in clearly labelled containers with sufficient formalin for routine fixation.
- Axillary node specimens should be examined carefully to maximise lymph node yield. This is usually achieved by manual dissection of fixed axillary tissue with careful examination by inspection and palpation. The yield of lymph nodes may be high in

such samples. The use of clearing agents may increase lymph node yield; however, this is time consuming, expensive and rarely used.

- Axillary lymph nodes may be softer and more difficult to palpate in post-chemotherapy specimens and lymph node yields may be lower.¹⁶
- Conversely, in certain scenarios (e.g. post neoadjuvant chemotherapy or marker clip insertion), lymph nodes may feel firm and it is impossible to be certain if there is metastatic disease present; all of these nodes should be embedded.
- An axillary clearance specimen can be divided into 3 levels if the surgeon has marked the specimen appropriately.
- The apical lymph node should be separately examined, if identified surgically.
- All lymph nodes identified must be examined histologically.
- The method should ensure that the total number of lymph nodes should be assessable.
- A representative complete section of any grossly involved lymph node is adequate.
- Macroscopically uninvolved nodes should be sliced and embedded in their entirety.
- Multiple small lymph nodes (which do not require slicing) may be embedded in a single block, with care that this is recorded in a block key, which should form part of the report.

2.10.3 Intraoperative examination of lymph nodes

Intraoperative assessment of lymph nodes is undertaken in some centres to identify patients with metastasis in sentinel lymph nodes who may thus have axillary node clearance as a single operative procedure. A number of methodologies can be employed, including frozen section, imprint cytology and molecular techniques.

The future role and value of intraoperative assessment has been influenced by the American College of Surgeons Oncology Group Z0011 trial and by current UK Association of Breast Surgery recommendations such that axillary clearance is not mandated in patients with low volume nodal metastatic disease.^{20,21} For this reason, and because of the success of ultrasound-guided sampling of abnormal axillary lymph nodes, there may be less demand for intraoperative detection of micrometastatic disease in lymph nodes in the future.

Frozen section examination and touch imprint cytology

Frozen section examination of lymph nodes for metastatic carcinoma detects about 70% of metastases (about 90% of macrometastases and 40% of micrometastases).²² Meta-analysis of touch imprint cytology shows an overall sensitivity of 63%. However, not surprisingly, the sensitivity for detection of micrometastases is 22%, compared to that for macrometastasis of 81%.²³

An exceptionally unusual circumstance in which intraoperative assessment is reasonable is when a sentinel node has a macroscopic appearance highly suspicious of metastatic carcinoma.

Molecular techniques on lymph nodes

OSNA is commercially available and has about 96% agreement with alternate slice histology. After intraoperative assessment, any residual sentinel lymph node should be examined as in section 2.10.1, above.

Current UK guidance is that molecular assays, such as OSNA, should not be used in the neoadjuvant setting.¹⁷

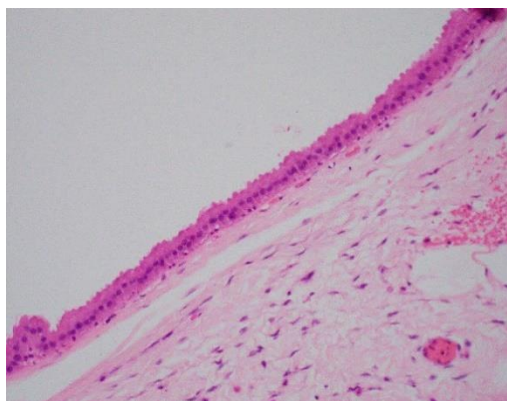
3 Classifying benign lesions

This section was historically derived to classify and record lesions on the screening form detected by breast cancer screening. However, we feel it is important that similar standardisation of diagnosis and of categorisation is also applied to symptomatic lesions. This approach should, therefore, be used to classify benign lesions identified in excision specimens. Most pathologists do not sub-classify and report benign conditions coexisting with established in situ or invasive carcinoma unless directly relevant (for example as explanation of radiological abnormality).

3.1 Solitary cyst

This term should be used when the abnormality appears to be a solitary cyst. The size is usually greater than 10 mm and the epithelial cell lining attenuated, frequently showing apocrine metaplasia (Figure 7). The latter may show papillary apocrine change/hyperplasia, which should be indexed separately under epithelial proliferation of appropriate type. If multiple cysts are present, it is preferable to use the term 'fibrocystic change'. Papillary lesions associated with cystic change should not be entered here but under papilloma or carcinoma.

Figure 7: Cyst lined by a single layer of apocrine cells.



3.2 Fibrocystic change

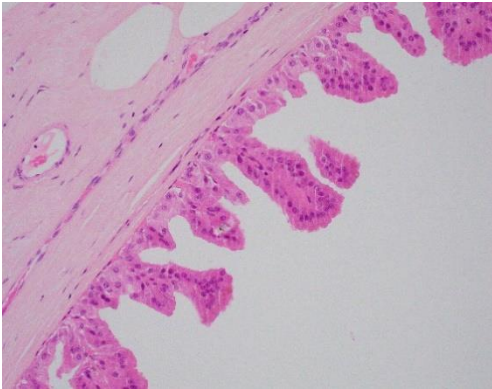
This term is used for cases with a constellation of benign features including cysts, some of which may be lined by apocrine type epithelium, fibrosis, usual epithelial hyperplasia and columnar cell change.

The term is not intended for use with minimal alterations, such as fibrosis, microscopic dilatation of acini or ducts, lobular involution and minor degrees of columnar cell change. These changes should be indexed as normal.

It is not intended that cystic change or apocrine metaplasia occurring within other lesions such as fibroadenomas, papillomas or sclerosing lesions should be coded here.

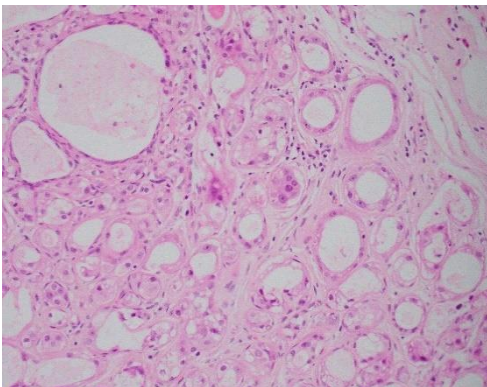
Apocrine epithelium lining cysts may show a variety of architectural patterns referred to as papillary apocrine hyperplasia. This may be simple (apocrine lining cells are at least 3 or more cells thick focally resulting in 'mounds' of cells, broader at the base than at the tip, that do not connect) (Figure 8), complex (papillae both taller and broader at the base than the mounds of simple hyperplasia with a tendency to anastomose within the lumen) and highly complex (greatly elongated papillae, 2–3 cells wide, with frequent anastomoses).²⁴ Papillary apocrine hyperplasia should be indexed separately under epithelial proliferation with or without atypia, depending on its appearance. It should be noted that apocrine cells often exhibit a degree of nuclear pleomorphism greater than is seen in normal breast cells. Apocrine hyperplasia should, therefore, be regarded as atypical only when the cytological changes are significantly more pronounced than usual with at least 3-fold variation in nuclear size. If atypia is deemed sufficient to warrant a diagnosis of atypical apocrine hyperplasia (record as atypical ductal hyperplasia) or apocrine DCIS (record as DCIS), this should be recorded separately on the screening form.

Figure 8: Papillary apocrine change/hyperplasia, simple: the apocrine cells form papillary structures that are at least 3 cells thick focally, broader at the base than at the tip and do not anastomose.



Apocrine metaplasia occurring in lobules without cystic change may produce a worrisome appearance, occasionally mistaken for carcinoma. Apocrine adenosis is the term used to refer to apocrine change within sclerosing adenosis.²⁵ These changes should be regarded as atypical only when there is at least 3-fold variation in nuclear size (Figure 9).²⁶

Figure 9: Atypical apocrine adenosis: the apocrine cells show at least 3-fold variation in nuclear size.



3.3 Columnar cell lesions

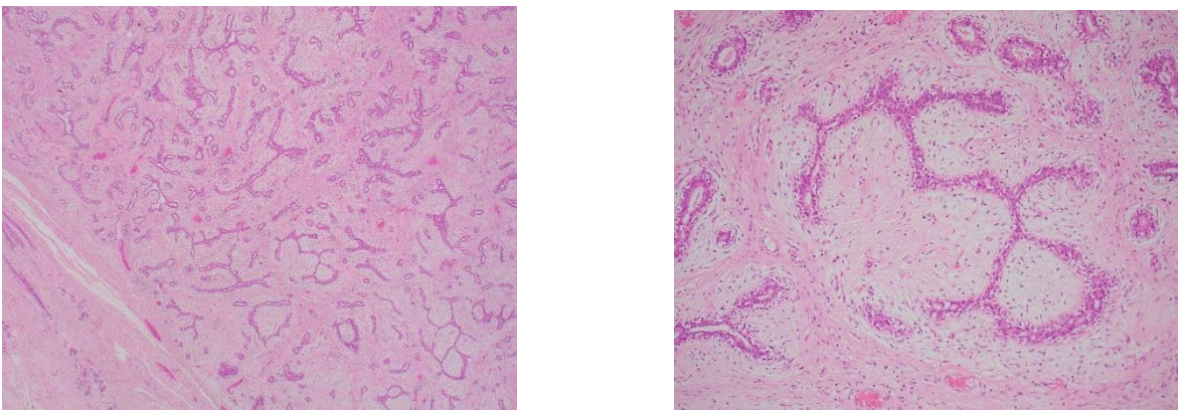
Columnar cell lesions represent an alteration in the terminal duct lobular unit and include columnar cell change, columnar cell hyperplasia and flat epithelial atypia.²⁷ These lesions may co-exist with atypical hyperplasia and low-grade in situ and invasive neoplasia and may represent precursor lesions.^{28,29} They are often identified as a result of investigations of radiological microcalcification.^{27,30,31}

Please refer to section 5.1 where these lesions are described in greater detail.

3.4 Fibroadenoma

A benign lesion composed of evenly distributed connective tissue and epithelium exhibiting an intracanalicular and/or pericanalicular growth pattern (Figure 10). The connective tissue is generally composed of spindle cells but may rarely also contain other mesenchymal elements, such as fat, smooth muscle, osteoid or bone. Myxoid change may be marked. The epithelium is characteristically bi-layered but changes commonly seen in lobular epithelium elsewhere in the breast (e.g. apocrine metaplasia, sclerosing adenosis, columnar cell change, hyperplasia of usual type) may occur in fibroadenomas; these are sometimes referred to as complex fibroadenomas. Co-existent benign changes within fibroadenomas do not need to be recorded separately.

Figure 10: Fibroadenoma with an intracanalicular architecture showing an even distribution of glands and stroma (left and right).



Sometimes individual lobules may exhibit increased stroma producing a fibroadenomatous appearance and occasionally such lobules may be loosely coalescent. These changes are often called fibroadenomatoid hyperplasia/change but may be recorded as fibroadenoma on the reporting form if they produce a macroscopically visible or palpable mass.

Fibroadenomas are not always perfectly circumscribed.

Old lesions may show hyalinisation and calcification (and less frequently ossification) of stroma and atrophy of epithelium. Calcified fibroadenomas may present as areas of indeterminate calcification on screening mammography. Fibroadenomas are occasionally multiple.

For the purposes of the screening form, tubular adenomas can be included with fibroadenomas.

Malignant change occurs rarely in the epithelial component of a fibroadenoma. This usually takes the form of carcinoma in situ, more frequently lobular than ductal. These changes should be recorded separately on the screening form.

3.4.1 Phyllodes tumours

Phyllodes tumours should be distinguished from fibroadenomas. Malignant phyllodes tumours are usually easily identified by their highly atypical, cellular, sarcoma-like stroma (or, less commonly, heterologous sarcomatous elements). Although a phyllodes tumour with liposarcomatous elements was previously regarded as malignant, the most recent edition of the *WHO Classification of Breast Tumours* notes that well differentiated liposarcoma occurring within a phyllodes tumour has a low metastatic risk and a borderline categorisation would therefore seem more appropriate.^{32,33}

Benign and borderline variants may be more difficult to distinguish from cellular fibroadenoma.³⁴ The key features are the classical architecture of an enhanced intracanalicular growth pattern with club-like projections into cystic spaces and increased stromal cellularity (Figure 11, Table 1). Adequate sampling is important as the characteristic stromal features may be seen only in parts of the lesion. Although phyllodes tumours are generally larger than fibroadenomas, size is not an acceptable criterion for diagnosis since fibroadenomas may be very large and conversely, phyllodes tumours small. Benign and borderline phyllodes tumours should be specified under 'other benign lesions' and malignant phyllodes tumours under 'other malignant tumour'. It is necessary to record margin status in the histopathology report as a compromised margin relates to risk of local recurrence. Although it is common practice to adopt a clinical and radiological surveillance approach for benign phyllodes tumours, re-excision of positive margins is recommended for borderline and malignant phyllodes tumours.^{35,36}

Figure 11: Benign phyllodes tumour with a well-defined margin and branching duct spaces lined by benign epithelium within cellular stroma (left and right).

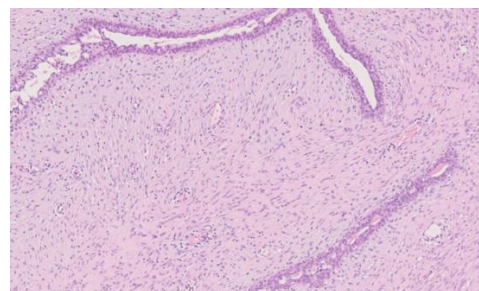
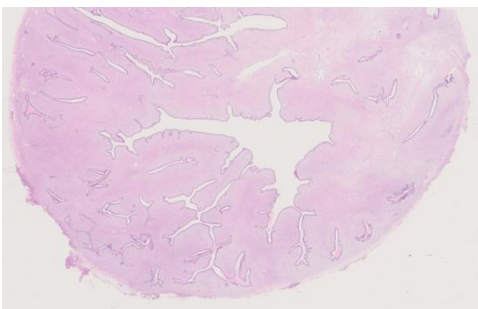


Table 1: Histological features of fibroadenoma and phyllodes tumour (benign, borderline and malignant). Adapted from WHO Classification of Breast Tumours (5th edition)³⁷ and College of American Pathologists' (CAP) Protocol for the examination of resection specimens from patients with phyllodes tumor of the breast (https://documents.cap.org/protocols/Breast.Phyllodes_1.1.0.0.REL_CAPCP.pdf)

| Histological feature | Fibroadenoma | Benign PT | Borderline PT | Malignant PT |
|--|---------------------------|--|---|--|
| Outline | Well defined | Well defined | Well defined, may be focally infiltrative | Infiltrative |
| Stromal cellularity | Variable, usually uniform | Cellular, usually mild (non-overlapping stromal nuclei), may be focal or diffuse | Cellular, usually moderate (some overlapping stromal nuclei), may be focal or diffuse | Cellular, usually marked (many overlapping stromal nuclei) and diffuse |
| Stromal atypia | None | Mild or none | Mild or moderate | Marked |
| Mitotic activity | None or low | Low (<2.5/mm ² or <5/10 HPFs) | Frequent (2.5-5/mm ² or 5-10/10 HPFs) | Abundant (>5/mm ² or >10/10 HPFs) |
| Stromal overgrowth* | Absent | Absent | Absent or very focal | Often present |
| Malignant heterologous elements | Absent | Absent | Absent | May be present |
| Distribution relative to other breast tumours | Common | Uncommon | Rare | Rare |

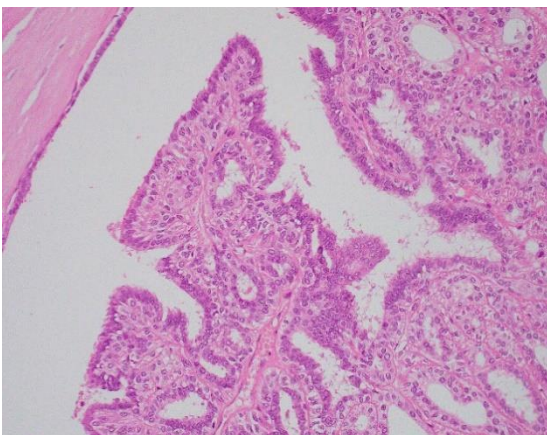
| | | | | |
|--|-----|--------|--------|-------|
| Relative % of all phyllodes tumours | N/A | 60–75% | 15–26% | 8–20% |
|--|-----|--------|--------|-------|

*Stromal overgrowth is defined as at least 1 low power microscope field (4x objective and 10x eyepiece (or 22.9 mm²) with no epithelial elements).

3.5 Papilloma

A papilloma is defined as a tumour with an arborescent fibrovascular stroma covered by an inner myoepithelial and outer epithelial cell layer (Figure 12). Epithelial hyperplasia without cytological atypia is often present. Atypical hyperplasia is rarely seen and, when present, should be recorded separately under ‘Epithelial proliferation’ on the screening form. See also section 5.4. The term ‘papilloma with atypical ductal hyperplasia’ is preferred to ‘atypical papilloma’. Apocrine metaplasia is frequently observed but should not be recorded separately on the reporting form. Squamous metaplasia is sometimes seen, particularly near areas of infarction. Sclerosis and haemorrhage are not uncommon and, where the former involves the periphery of the lesion, it may give rise to epithelial entrapment with the false impression of invasion. The benign cytological features of such areas should enable the correct diagnosis to be made. Myoepithelial cell IHC may be helpful in difficult cases. The term ‘intracystic papilloma’ is sometimes used by radiologists to describe a papilloma in a widely dilated duct. These lesions should be classified as papilloma on the form. These tumours should be differentiated from encapsulated papillary carcinoma.^{38,39}

Figure 12: Intraduct papilloma characterised by an arborising network of fibrovascular connective tissue cores covered by myoepithelial and epithelial cell layers.



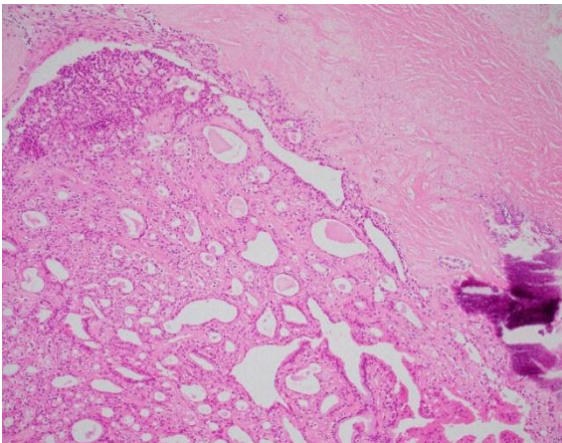
Papillomas may be solitary or multiple. The former usually occurs centrally in sub-areolar ducts whereas the latter are more likely to be peripheral and involve terminal duct lobular units. The distinction is important as the multiple form is more frequently associated with

atypical hyperplasia and DCIS, the latter usually of low grade, which should be recorded separately.⁴⁰

As atypical or malignant change may be focal within a papilloma, it is advisable to embed the lesion in its entirety (or extensively sample particularly large lesions) for microscopic evaluation. Some sub-areolar papillomas causing nipple discharge may be very small and thorough sampling of excision specimens may be required to detect them.

Lesions termed ductal adenoma (sclerosed duct papilloma) exhibit a variable appearance which overlaps with other benign breast lesions. They may resemble papillomas except that they display an adenomatous rather than a papillary growth pattern (Figure 13). These cases should be grouped under papilloma on the form. Indeed, some tumours may exhibit both papillary and adenomatous features. Some ductal adenomas show pronounced central and/or peripheral fibrosis and overlap with complex sclerosing lesions. Some use the term complex sclerosing papillary lesion for these entities.

Figure 13: Sclerosing papilloma (ductal adenoma) with calcification, comprising a proliferation of glandular structures within a duct.



3.6 Sclerosing adenosis

Sclerosing adenosis is an organoid lobular enlargement in which increased numbers of acinar structures exhibit elongation and distortion (Figures 14 and 15). The normal 2-cell lining is retained but there is myoepithelial and stromal hyperplasia. The acinar structures may infiltrate adjacent connective tissue and occasionally nerves and blood vessels, which can lead to an erroneous diagnosis of malignancy. Early lesions of sclerosing adenosis are more cellular and later ones more sclerotic. Calcification may be present.

Figure 14: Sclerosing adenosis: the acini of the terminal duct lobular unit are compressed due to intra-lobular fibrosis.

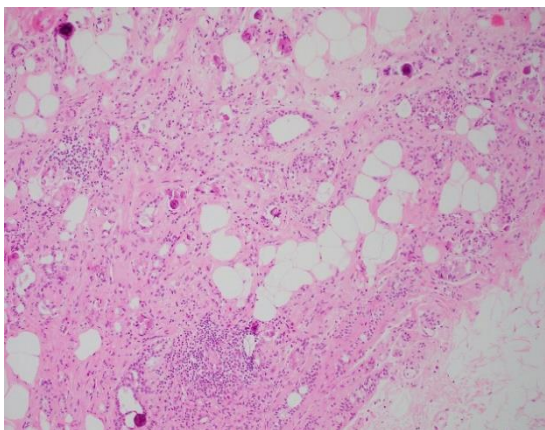
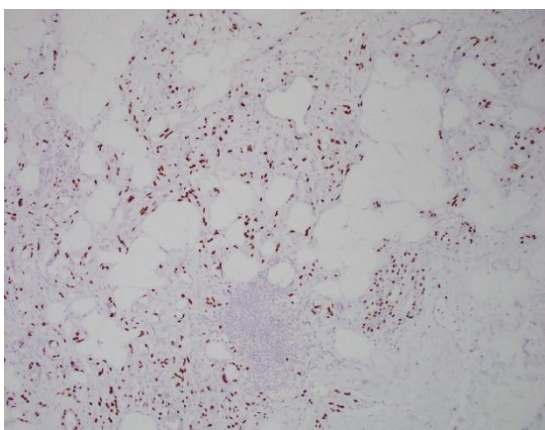


Figure 15: p63 immunostain demonstrates a myoepithelial cell layer around the acini.



There may be coalescence of adjacent lobules of sclerosing adenosis to form a mass detectable by mammography or macroscopic examination. The terms 'nodular sclerosing adenosis' or 'adenosis tumour' have been used to describe such lesions. It is recommended that sclerosing adenosis is not entered on the screening form if it is a minor change detectable only on histological examination. Although sclerosing adenosis often accompanies fibrocystic change (see below), this is not always the case and the 2 changes should be recorded separately.

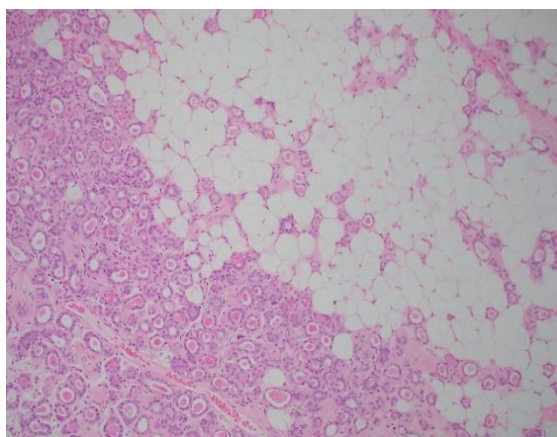
Occasionally apocrine metaplasia is seen in areas of sclerosing adenosis ('apocrine adenosis').^{25,41} This may produce a worrying appearance and should not be mistaken for malignancy. This has a lobular architecture at low power and variation in nuclear size should be less than 3-fold. There are usually adjacent benign changes. Apocrine change within sclerosing adenosis in which there is at least 3-fold variation in nuclear size is termed atypical apocrine adenosis.²⁶ Rarely, the epithelium in sclerosing adenosis may

show atypical hyperplasia or in situ carcinoma. In such cases, these changes should be recorded separately on the reporting form.

The differential diagnosis of sclerosing adenosis includes tubular carcinoma, microglandular adenosis and radial scar.⁴² In tubular carcinoma, the infiltrating tubules exhibit cytological atypia, lack a myoepithelial cell layer and a lobular organoid growth pattern; DCIS is a frequent accompaniment.

Microglandular adenosis differs from sclerosing adenosis in lacking the lobular organoid growth pattern and glandular distortion (Figure 16).⁴³ It is characterised by a proliferation of rounded tubules lined by a single layer of epithelial cells lacking cytological atypia and frequently containing luminal secretions. There is no stromal reaction and microglandular adenosis has a specific immunohistochemical profile (S100 positive and ER negative). Originally regarded as a benign lesion, there is accumulating evidence that microglandular adenosis may be a precursor lesion of triple negative breast cancer.^{44,45}

Figure 16: Microglandular adenosis: the glands are typically round, lined by a single layer of epithelial cells and contain luminal eosinophilic secretions.

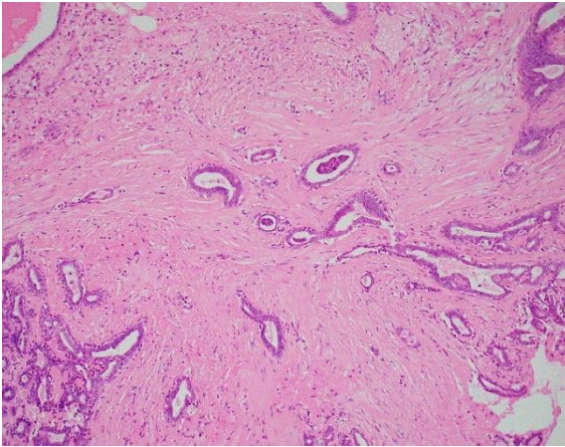


3.7 Sclerosing lesions (complex sclerosing lesion/radial scar)

The term complex sclerosing lesion/radial scar includes those sclerosing lesions with a pseudo-infiltrative growth pattern. A radial scar is defined as being 10 mm or less in maximum dimension and consists of a central fibro-elastic zone from which 2-layered, tubular structures radiate that may exhibit intra-luminal proliferation. Tubules entrapped within the central zone of fibro-elastosis exhibit a random, non-organoid arrangement (Figure 17). Lesions greater than 10 mm are generally termed complex sclerosing lesions. They have all the features of radial scar and, in addition to their greater size, exhibit more disturbance of structure, often with nodular masses around the periphery. Changes such as papilloma formation, apocrine metaplasia and sclerosing adenosis may be

superimposed on the main lesion. Some complex sclerosing lesions give the impression of being formed by coalescence of several adjacent sclerosing lesions. There is a degree of morphological overlap with some forms of ductal adenoma.

Figure 17: Radial scar nidus composed of tubules lined by epithelial and myoepithelial cells.



If the intra-luminal proliferation exhibits atypia or amounts to in situ carcinoma, it should be recorded separately under the appropriate heading on the screening form.

The main differential diagnosis is carcinoma of tubular or low-grade no special type (NST).⁴¹ The major distinguishing features are the presence of a myoepithelial cell layer and basement membrane around the tubules in the sclerosing lesions. IHC for myoepithelial cells is useful (see Appendix G). Cytological atypia is also lacking and intra-tubular proliferation resembles hyperplasia of usual type unless atypical hyperplasia and/or in situ carcinoma are superimposed (see above). Tubular carcinomas generally lack the characteristic architecture of sclerosing lesions.

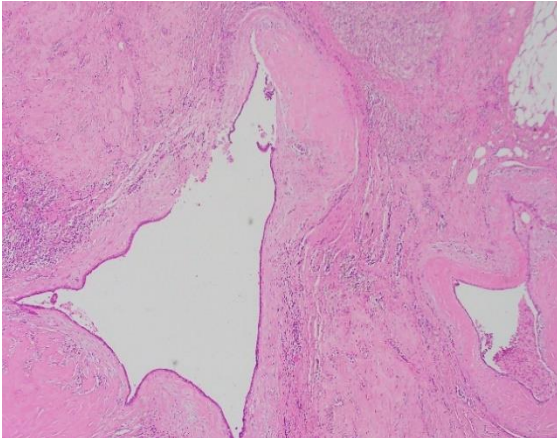
Radial scar is distinguished from sclerosing adenosis by its characteristic floret-type growth pattern with ducto-lobular structures radiating from a central zone of dense fibro-elastotic tissue. A myoepithelial cell layer is seen at the periphery of tubules in both sclerosing adenosis and radial scar/complex sclerosing lesion.

3.8 Duct ectasia (periductal mastitis)

This process involves large and intermediate size ducts, generally in a sub-areolar location. The ducts are lined by normal or attenuated epithelium, filled with amorphous, eosinophilic material and/or foam cells and exhibit marked periductal chronic inflammation, often with large numbers of plasma cells. There may be pronounced periductal fibrosis (Figure 18). The inflammatory cell infiltrate may contain large numbers of histiocytes

producing a granulomatous appearance. Calcification may be present. The process may ultimately lead to obliteration of ducts leaving dense fibrous masses. Persistence of small tubules of epithelium around the periphery of an obliterated duct results in a characteristic garland pattern. Duct ectasia is often associated with nipple discharge or retraction.

Figure 18: Duct ectasia characterised by ductal dilatation with inspissated luminal secretions and periductal inflammation and fibrosis.



Duct ectasia may present as calcification on screening mammography. In fibrotic duct ectasia there may be little residual epithelium for evaluation such that distinction from ‘burnt out’ DCIS may be difficult on core biopsy. Additional level sections may assist the diagnosis.

Cysts are distinguished from duct ectasia by their rounded rather than elongated shape, tendency to cluster, lack of stromal elastin, frequent presence of apocrine metaplasia and less frequent presence of eosinophilic material or foam cells in the lumina.

3.9 Reaction to breast implants

Most implants have an associated fibrous capsule, often with scattered chronic inflammatory cells. There may be a pseudosynovial reaction on the surface. Silicone that has leaked from the implant is seen as clear spaces, typically of variable size, with associated macrophages, foreign body giant cells and lymphocytes. A similar reaction to silicone may be seen in the regional lymph nodes. Fluids and tissue samples from implants where there is a suspicion of breast implant-associated anaplastic large cell lymphoma (BIA-ALCL) should be worked up according to published guidelines (see section 7.2.12).¹⁸

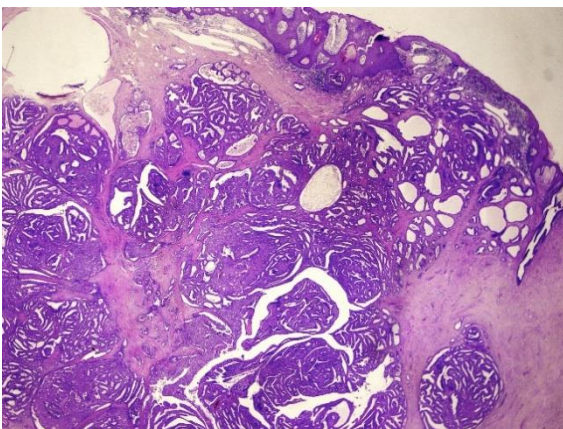
3.10 Other (specify)

This category is intended for recording less common conditions which form acceptable entities but cannot be entered into the categories above.

These include nipple duct adenoma, hamartoma, myofibroblastoma, fibromatosis, fat necrosis, pseudoangiomatous stromal hyperplasia (PASH), lactational/secretory change and benign and borderline phyllodes tumours (the latter discussed above).

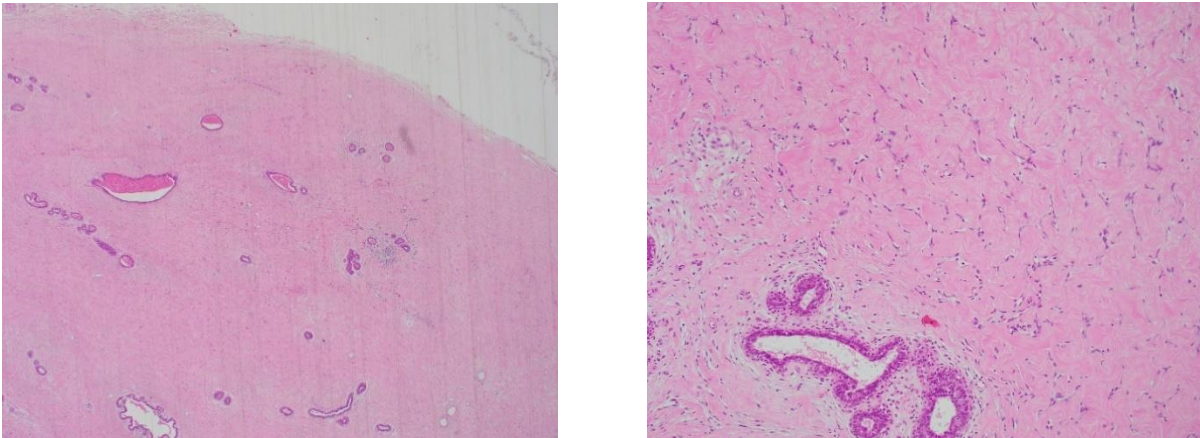
As the name implies nipple duct adenoma occurs in areolar breast tissue and may be accompanied by nipple ulceration mimicking Paget's disease clinically. It is characterised by a proliferation of tubular structures lined by epithelial and myoepithelial cell layers. Florid epithelial hyperplasia is common (Figure 19). Owing to its infiltrative outline, this lesion may be mistaken for invasive carcinoma histologically. Awareness of this pitfall and use of myoepithelial cell IHC will avoid misdiagnosis. This lesion should also be distinguished from syringomatous adenoma of the nipple.

Figure 19: Nipple duct adenoma characterised by a proliferation of benign tubular/glandular structures, with an irregular outline and frequently with accompanying epithelial hyperplasia.



Hamartoma is usually well circumscribed on radiological examination. Diagnosis may be difficult on core biopsy due to the presence of relatively normal tissue leading to a B1 designation. The presence of PASH and stromal adipose tissue in some lesions may assist identification (Figure 20). MDT review is important to ensure concordance with radiology.

Figure 20: Hamartoma comprising a proliferation of terminal duct lobular units in stroma (left) with pseudo-angiomatous stromal hyperplasia (right).



Myofibroblastoma is a benign spindle cell tumour of the breast, showing a fascicular growth pattern with intervening collagen bundles. The lesion is typically ER, CD34, smooth muscle actin (SMA) and desmin positive.

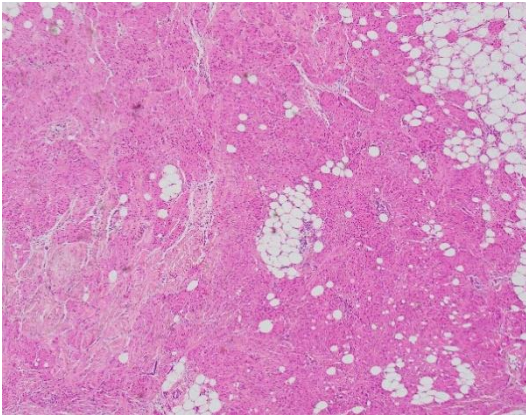
Fibromatosis of the breast is a rare locally aggressive lesion composed of a bland population of fibroblastic cells with spindle cell morphology, minimal cytological atypia and inconspicuous mitotic activity. Fibromatosis needs to be distinguished from fibromatosis-like carcinoma. Lesional cells typically display β -catenin nuclear staining, SMA cytoplasmic staining and lack expression of cytokeratin, p63 and CD34.

Fat necrosis may result from accidental trauma or following surgery. It is frequently accompanied by florid fibroblastic proliferation and older lesions may present as calcification.

PASH may be seen as an isolated lesion or in the context of gynaecomastia or in hamartoma. Slit-like stromal spaces are lined by stromal cells and do not contain red blood cells. Exuberant forms may mimic low-grade angiosarcoma. The lining cells are progesterone receptor and CD34 positive but are negative for all other endothelial cell markers.

Entities that are also included in this category include granular cell tumour (Figure 21), lipoma, granulomatous mastitis and rare inflammatory and infectious conditions.

Figure 21: Granular cell tumour composed of a proliferation of cells with dense eosinophilic cytoplasm and small, round, centrally located nuclei.



4 Male breast lesions

Almost all female breast lesions, including fibroadenomas, phyllodes tumours and columnar cell change, have been reported in men. Myofibroblastoma has traditionally been reported as a male breast lesion, but the lesion is currently recognised with equal frequency in women.⁴⁶ Below, we describe the most commonly encountered male breast conditions, including gynaecomastia and male breast cancer.

4.1 Gynaecomastia

Gynaecomastia is an increase in glandular tissue of the male breast (unilateral or bilateral) with consequent breast enlargement and is the commonest breast lesion in men. True gynaecomastia should be differentiated from pseudo-gynaecomastia (lipomastia) that occurs due to fat deposition. Physiological gynaecomastia occurs in neonates, during adolescence and in old age. Pathological gynaecomastia results from hormonal imbalance due to an underlying disease/condition, such as Klinefelter's syndrome, testicular/adrenal tumours, drugs, obesity or alcoholic cirrhosis. The commonest cause for gynaecomastia, however, is idiopathic with no underlying causes identified.⁴⁷

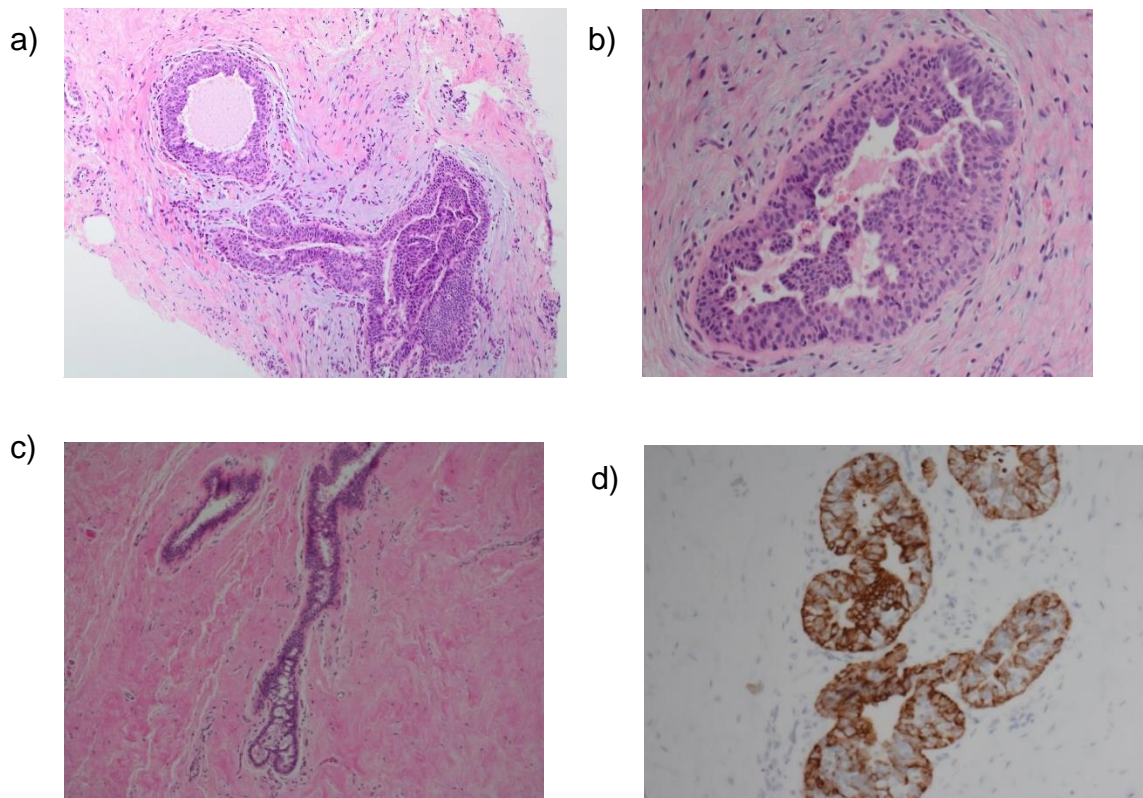
Histologically, gynaecomastia can be divided into florid (active), intermediate and fibrous (late) phases. The florid type is characterised by a proliferation of ducts with associated mild to moderate usual epithelial hyperplasia, often with micropapillary, papillary or cribriform architecture. The ducts are typically surrounded by cellular, loose or myxoid stroma often appearing as cuffs around epithelial structures (Figure 22a and b).

Pseudoangiomatous stromal hyperplasia (PASH) can be prominent. In the fibrous phase, hyalinised or fibrous stroma surrounds mammary ducts showing minimal or no hyperplasia (Figure 22c). The intermediate phase encompassing features of both florid and late

gynaecomastia can also be identified. Recognising florid gynaecomastia is of clinical relevance since this is the type that responds best to endocrine therapy.⁴⁸

It is worth noting that the pattern of cytokeratin expression in hyperplasia in breast ducts in males is different to that in the female breast; gynaecomastia shows a tri-layered pattern of inner and outer basal layers (CK5, CK14 positive) enclosing a middle layer of luminal cells (Figure 22d).⁴⁹ The recognition of such a pattern is important to avoid a mistaken diagnosis of atypical hyperplasia/DCIS.

Figure 22. Histological features of gynaecomastia. The active phase (a, b) shows florid epithelial hyperplasia with a micropapillary pattern within cellular myxoid stroma. The late phase (c) shows fibrosed stroma and minimal epithelial proliferation. Note the tri-layered pattern of male mammary ducts comprising inner and outer basal CK5/6 positive cells and a middle layer of negative cells (d).



4.2 Male breast cancer

Male breast cancer is rare, representing approximately 1% of all breast cancers, but the incidence is rising.⁵⁰ It is almost exclusively localised to the retroareolar region. Invasive breast cancer in men has a unimodal age distribution with a mean age of 68 years.⁵¹ The diagnosis potentially warrants consideration for genetic referral, since male breast cancer is associated with BRCA2 germline mutation (reported in 5% to 10% of male breast cancer patients), but not BRCA1 mutations.^{50,52,53} Klinefelter's syndrome is also associated with a 30–50 times relative risk of developing male breast cancer.⁵⁴ Other risk factors include

obesity, testicular disorders, prostate tumours and liver cirrhosis. Most studies have shown no link between gynaecomastia and male breast cancer.⁵⁵

Macroscopic handling, sampling and histological reporting protocols should be essentially the same as for female breast carcinoma and the dataset for male breast cancer is the same as that for breast cancer in women.

In situ carcinoma of the male breast is almost exclusively ductal, rather than lobular, in pattern. Pure DCIS and Paget's disease of the nipple have been described in the male breast with DCIS reported to represent 9% of male breast cancer.^{56,57}

The commonest type of invasive male breast cancer is NST carcinoma followed by papillary carcinoma, the latter being more common as a proportion than in the female breast.⁵⁵ Papillary lesions in the male breast include intraductal papillomas (with and without atypia), papillary DCIS, encapsulated papillary carcinoma, solid papillary carcinoma, and invasive papillary carcinomas.^{58,59} Compared with female breast cancer, invasive lobular carcinoma is extremely rare in men. Irrespective of sub-type, specimens should be examined and classified as in the female breast (see section 6).

ER and HER2 status should be assessed and reported, similar to female invasive breast cancers; breast cancers in men are more frequently ER-positive than female breast cancers (even up to 99% in some series), and are also typically progesterone and androgen receptor positive, and HER2 negative.^{51,60}

Male breast cancer should be differentiated from metastases to the male breast, including deposits derived from prostatic adenocarcinoma; of note it has long been recognised that prostate-specific antigen (PSA) can occasionally be positive in breast cancers and should therefore be interpreted with caution.⁶¹ Markers that support a mammary origin (e.g. GATA3) may be expressed in male breast cancer; in some series 100% (30 of 30) primary male breast cancers expressed GATA3 but other series have suggested that GATA3 is less frequently positive in male breast cancers (6 of 19 (31.6%) male versus 135 of 164 (82.3%) female carcinomas).^{62,63}

Although treatment for male breast cancer is now essentially similar to that for women, historically (e.g. data from 1973 through 2005 in the Surveillance, Epidemiology, and End Results [SEER]), suggested that male patients had a poorer prognosis.⁶⁴⁻⁶⁶ This has not been universally reported.⁵⁷ Prognostic factors in male breast cancer in some, but not all series, include age, histological grade and stage, as well as receipt of chemotherapy, endocrine therapy and radiotherapy.⁶⁷

5 Classifying epithelial proliferations

This section should be used to record the presence of intraluminal epithelial proliferation in terminal duct lobular units or interlobular ducts.

5.1 Epithelial proliferation – not present

This should be ticked if there is no epithelial multilayering (apart from that ascribed to cross-cutting).

5.2 Epithelial proliferation – present without atypia

This term should be used to describe all cases of intraluminal proliferation, most commonly usual type epithelial hyperplasia, showing no or only minimal atypia (not amounting to atypical ductal hyperplasia or flat epithelial atypia). The proliferation may vary from mild (up to 4 cell layers thick) to florid usual epithelial hyperplasia. The changes may involve terminal duct lobular units or interlobular ducts.

5.2.1 Usual ductal/epithelial hyperplasia

The major morphological features of usual epithelial hyperplasia are (Figures 23a–d, Table 2, and accompanying image):

- a mixed cell population comprising (luminal) epithelial cells, basal/myoepithelial cells
- irregular, slit-like and peripheral lumina (Table 2 and accompanying image)
- streaming epithelial bridges with indistinct cell boundaries
- overlapping nuclei with mild variation in size and shape
- infrequent mitoses, with no abnormal forms.

IHC:

- a mosaic/mixed pattern of reactivity for luminal epithelial cytokeratins (CK8, 18, 19) and basal intermediate epithelial cytokeratins (CK5, 5/6, 14) (see Appendix G and Figure 23c) is usually seen
- a range of intensity of expression with ER from negative to strongly positive cells is typically seen in usual epithelial hyperplasia. In low-grade clonal epithelial proliferations (atypical ductal hyperplasia [ADH], low-grade DCIS and lobular in situ neoplasia), uniform strong ER positivity is present (see Appendix G)

- cells of basal intermediate type (with basal cytokeratin reactivity) are absent in columnar cell lesions (which are uniformly ER-positive) and in apocrine proliferations (typically ER negative).

The distinctions from ADH and low-grade DCIS are summarised in Table 2.

Figure 23: Examples of usual epithelial hyperplasia (a, b). Use of ER (c) and high molecular weight cytokeratin staining (d) cytokeratin 5/6 staining) to demonstrate its heterogeneous cell population can be helpful in problematic cases.

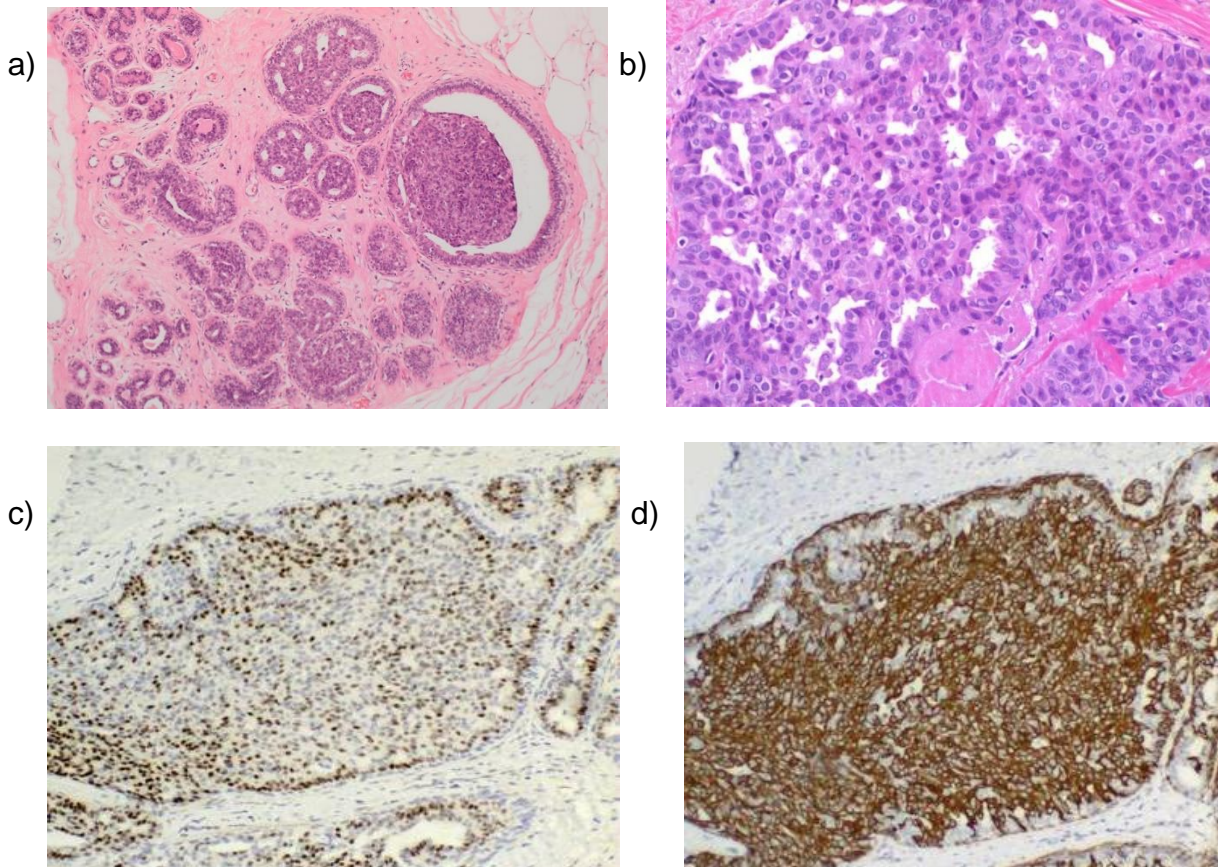

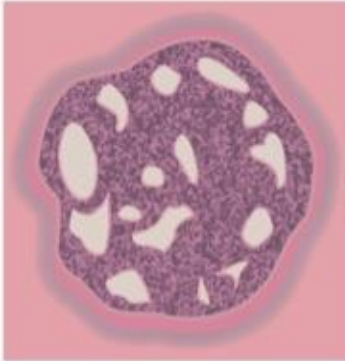
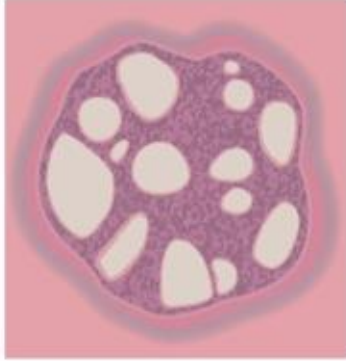


Table 2 and accompanying image: Comparison of histological features of ductal hyperplasia and DCIS.

| Histological features | Usual ductal hyperplasia | Atypical ductal hyperplasia | Low nuclear grade DCIS |
|------------------------------|--|--|---|
| Size | Variable size but rarely extensive unless associated with other benign processes such as papilloma or radial scar | Usually small (< 2 mm) and/or incomplete duct space involvement | At least 2 mm and/or 2 complete duct spaces |
| Cellular composition | Mixed epithelial cell and spindle-shaped cells often present Lymphocytes and macrophages may also be present Myoepithelial hyperplasia may rarely occur around the periphery | A uniform cell population, which may merge with areas of usual type hyperplasia within the same duct space | Single uniform cell population |
| Architecture | Variable | Micropapillary, rigid epithelial bridges and Roman arches or solid pattern | Well-developed micropapillary, cribriform or solid patterns |
| Lumina | Irregular, ill-defined peripheral slit-like spaces are common and a useful distinguishing feature | May be distinct, well-formed rounded spaces in cribriform type. Irregular, ill-defined lumina may also be present | Well delineated, regular punched out lumina in cribriform type. Micropapillae are of classical appearance, with thinner necks and more bulbous tips. |

| | | | |
|--------------------------------------|--|--|--|
| Cell orientation | Often a streaming pattern with the long axes of nuclei arranged in parallel to direction of cellular bridges, which often have a 'tapering' appearance | Cell nuclei may be at right angles to bridges in cribriform type, forming 'rigid' structures | Micropapillary structures with indiscernible fibrovascular cores or smooth, well delineated geometric spaces Cell bridges 'rigid' in cribriform type with nuclei orientated towards the luminal space |
| Nuclear spacing | Uneven | Even | Even |
| Epithelial/ tumour cell character | Small and ovoid, but showing variation in shape | Small uniform or medium-sized monotonous population present at least focally | Small uniform monotonous population |
| Nucleoli | Indistinct | Single small | Single small |
| Mitoses | Infrequent; no abnormal forms | Infrequent; abnormal forms rare | Infrequent; abnormal forms rare |
| Necrosis | Rare | Rare | If present, confined to small particulate debris/secretion in cribriform and/or luminal spaces |
| Immunohisto-chemistry ER | Heterogeneous/ mosaic Heterogeneous/ mosaic | Homogeneous usually strong Negative | Homogeneous usually strong Negative |

| | | | |
|---|---|---|--|
| High MW cyto-keratins (e.g. CK5, 5/6,14,17) | | | |
|  |  |  | |
| Usual epithelial hyperplasia | Atypical ductal hyperplasia | DCIS | |

5.3 Columnar cell lesions

Columnar cell lesions include the spectrum of changes ranging from bland columnar cell change (see section 4.3) through columnar cell hyperplasia to flat epithelial atypia.^{27,68} They have become increasingly identified clinically as a consequence of more rigorous investigation of radiological calcification.³⁰

5.3.1 Categorisation and recording of columnar cell lesions

- Columnar cell change (including columnar cell hyperplasia)
- Flat epithelial atypia
- Flat high-grade in situ carcinoma.

These should be recorded on the breast screening form according to their broad category:

- benign columnar alterations without atypia, or with minor degrees of atypia, as columnar cell change
- columnar cell change with architectural atypia as ADH (epithelial proliferation with atypia – ductal) or low-grade DCIS, according to extent (see sections 5.4 and 6.1.4)
- flat epithelial atypia should be categorised as epithelial proliferation with atypia – ductal
- lesions with marked atypia as flat high-grade DCIS (see section 5.1.2).

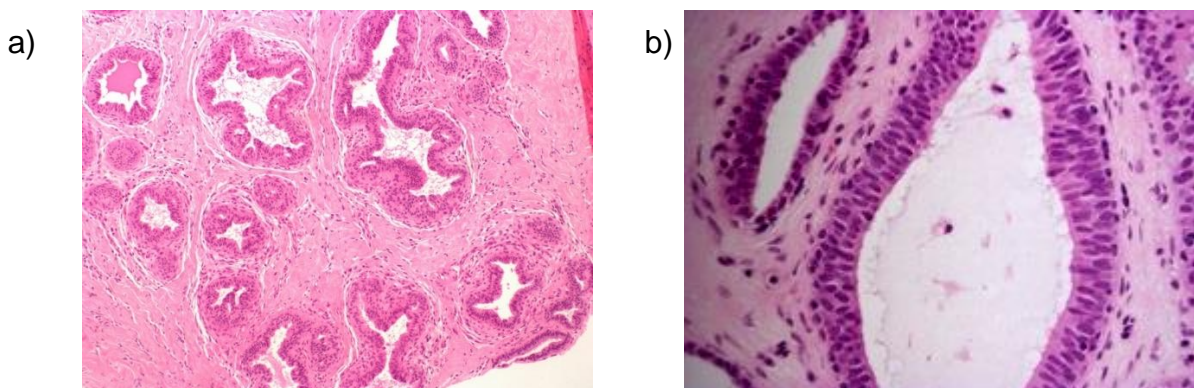
5.3.2 Columnar cell change and columnar cell hyperplasia

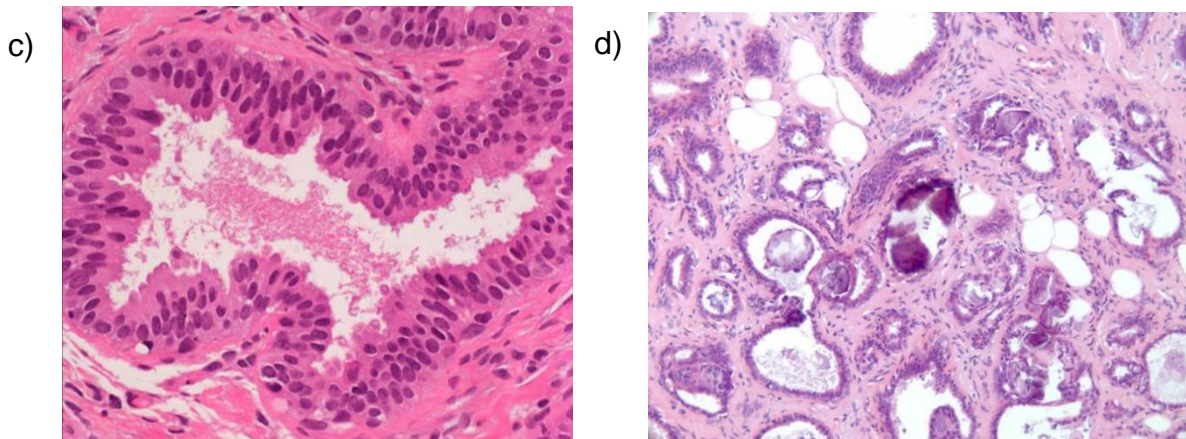
Classical columnar cell change (see also section 4.3 and Figures 24a–d) comprises lobular acini lined by cuboidal to tall columnar epithelial cells (Figure 24a and 24b). In columnar cell change, lobules are often dilated with an undulating contour. The lobules are typically lined by a single layer of columnar epithelial cells although minor tufting or multilayering may be present (Figure 24c). If a greater degree of multilayering of the epithelial cells is seen with more than 2 layers of cells not due to cross-cutting, the process is classified as columnar cell hyperplasia. There is some morphological variability within columnar cell lesions: nuclear size and the amount of hyperchromasia may vary, but significant nuclear atypia is absent. Columnar cell lesions are commonly associated with luminal secretions and/or microcalcifications (Figure 24d). Table 3 shows features of assistance in categorisation of the columnar cell lesions and distinguishing these from flat epithelial atypia and ADH.

Architectural complexity in the form of true micropapillary structures and rigid epithelial bridges is not seen in columnar cell change or columnar cell hyperplasia. If such architectural atypia is identified, the lesion should be assessed for degree within the membrane-bound spaces and overall extent, and classified as ADH or low-grade DCIS accordingly. See sections 4.4 and 5.1.4. As well as ADH/low-grade DCIS, other epithelial proliferations may merge, or be associated, with columnar cell hyperplasia, including atypical lobular hyperplasia (ALH), LCIS and invasive carcinoma, often of low-grade tubular or tubulo-lobular type.

The presence of such associations should be recorded as columnar cell change plus the additional type or types of lesion.

Figure 24: Examples of columnar cell change showing dilated lobules with an undulating contour. Typical columnar cell lining is also seen (a–d).





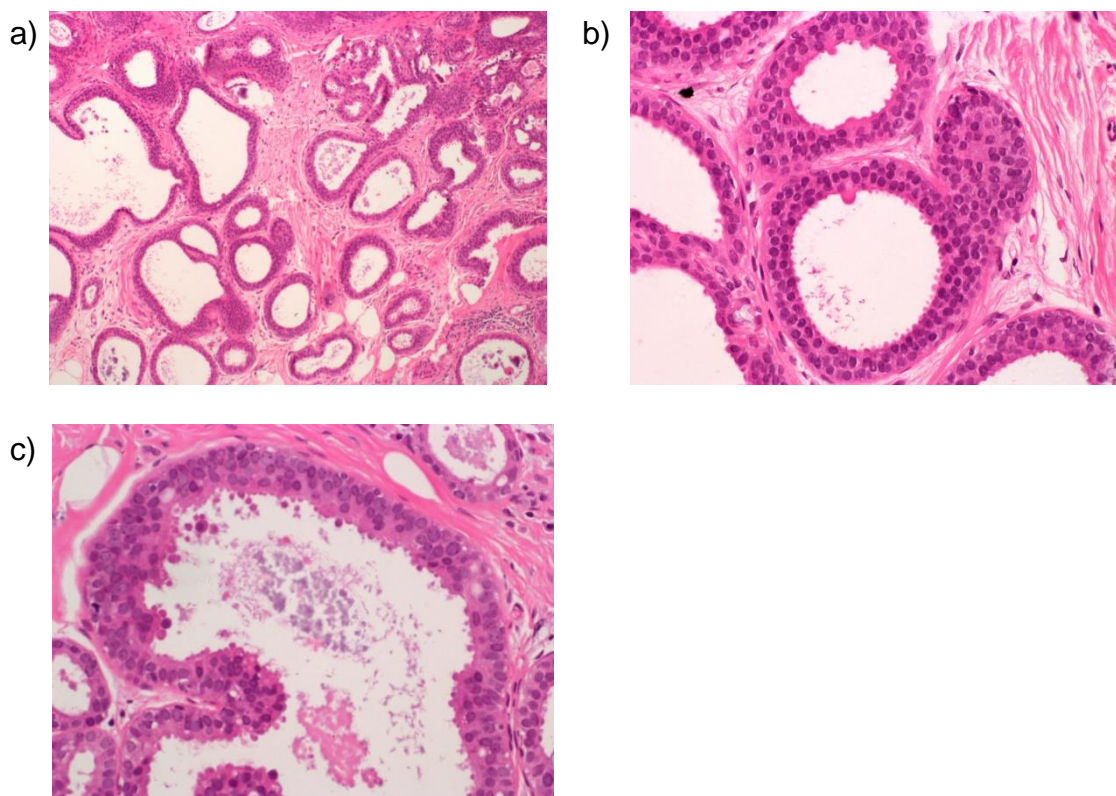
5.3.3 Flat epithelial atypia

If superimposed mild cytological atypia is seen within the columnar cell change in the terminal duct lobular unit (Figure 25a), the lesion is classified as flat epithelial atypia (Figures 25–c). In this lesion, the cells are morphologically similar to those of atypical ductal hyperplasia/low-grade DCIS but are present in a single layer lining round mildly dilated acini (Figure 25b). Acini involved by flat epithelial atypia often have a smooth, rigid outline in contrast to columnar cell change, where the dilated duct spaces have a more undulating contour. The nuclei are typically round or oval and evenly spaced (Figures 25b and 25c). The cells may have clumped chromatin or vesicular nuclei or prominent multiple nucleoli. Mitoses are infrequent. If there is marked cytological atypia the lesion is regarded as flat high-grade DCIS; see section 5.1.2.

It should be noted that the columnar epithelial cell proliferations, including columnar cell change and flat epithelial atypia, show uniform strong ER positivity and absent basal cytokeratin, in contrast to usual epithelial hyperplasia, as described in Appendix G. IHC is not useful in distinguishing between columnar cell change and flat epithelial atypia.

At present, the entity of flat epithelial atypia diagnosed in excision specimens is accepted as a lesion not associated with a significant risk of future development of cancer.⁶⁹ This is now included as a separate entity in the category of ‘epithelial proliferation – present with atypia (flat epithelial atypia)’.

Figure 25: Examples of flat epithelial atypia (a–c). Note the presence of prominent microcalcification.



5.4 Epithelial proliferation – present with atypia (ductal)

5.4.1 Atypical ductal hyperplasia

Atypical ductal hyperplasia (ADH) is an epithelial proliferation with some but not all features of low-grade DCIS (Figures 26a to 26c, Table 2 and accompanying image and Table 3). The diagnosis of ADH is based on both a qualitative and quantitative assessment of the lesion.⁷⁰

The qualitative assessment is based on cytological features and architectural growth pattern. These include:

- a uniform monomorphic luminal epithelial cell population (ER, CK8, 18, 19 positive, CK5, 5/6, 14 negative); see Appendix G and Figures 26a–c
- even spacing of the nuclei
- secondary lumina, some of which are rigid whereas others are tapering (Table 2 and accompanying image)
- hyperchromatic nuclei
- architectural complexity with cribriform, micropapillary or solid growth pattern

- incomplete duct space involvement.

The quantitative assessment is based on assessment of lesion size:

- areas of ADH are microfocal/small, with complete duct space involvement not exceeding 2 mm in size and/or less than 2 complete membrane-bound spaces^{70,71}
- proliferations with high-grade cytology qualify as DCIS, regardless of the size or quantity of epithelial proliferation.

The diagnosis of ADH is made in those cases in which a diagnosis of **low-grade** DCIS is seriously considered but where the architectural, cytological and quantitative features do not amount to a confident diagnosis of DCIS. If a diagnosis of ADH is contemplated, extensive sampling and/or levels should be undertaken to search for more evidence to establish an unequivocal diagnosis of DCIS.

Table 2 provides details of features to help distinguish ADH from usual type hyperplasia and DCIS and Table 3 shows features to help distinguish ADH from columnar cell lesions.

Figure 26: An example of atypical ductal hyperplasia (ADH). Note incomplete duct involvement (a). Low-grade DCIS and ADH are typically composed of a uniform luminal epithelial cell population which lacks high molecular weight cytokeratin expression (b, cytokeratin 5/6) and exhibits strong uniform ER staining (c).

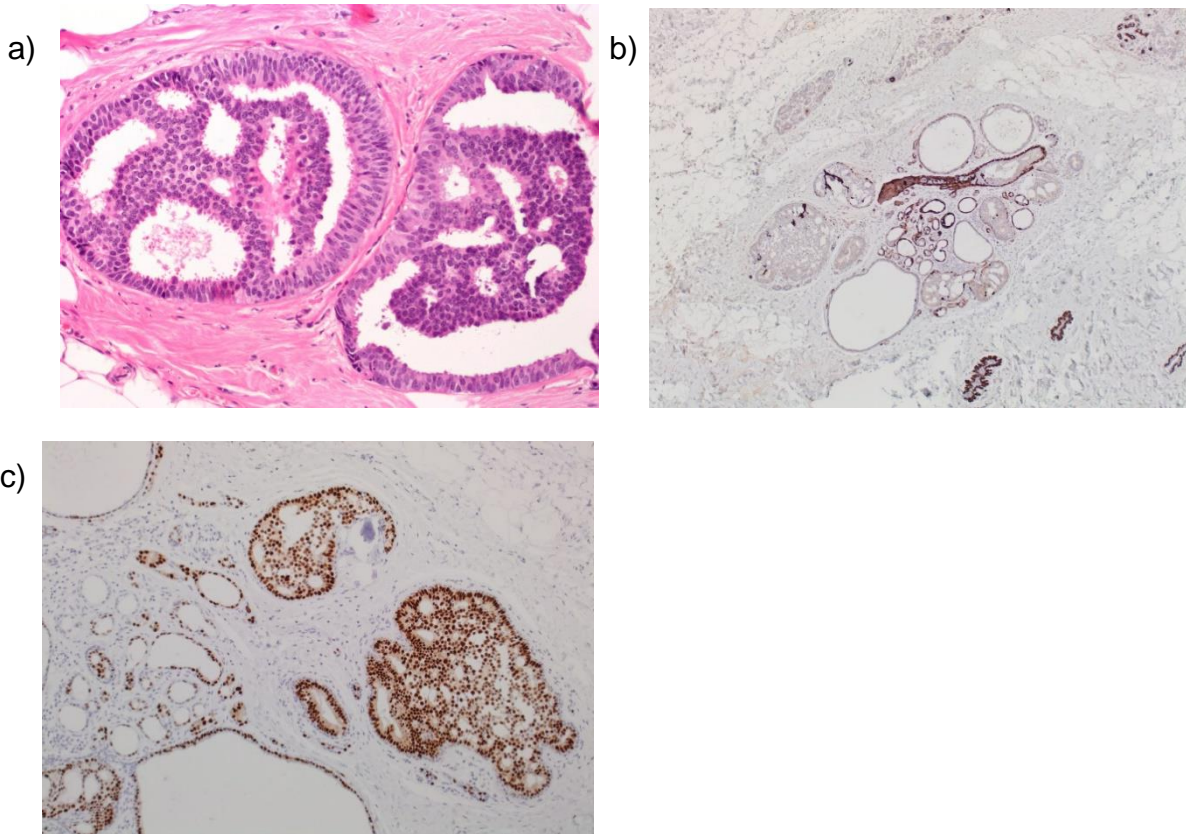


Table 3: Features of help in distinguishing the columnar cell lesions and atypical ductal hyperplasia (ADH) (TDLUs: terminal duct lobular units).

| Columnar cell change | Columnar cell hyperplasia | Flat epithelial atypia | Atypical ductal hyperplasia |
|---|--|--|--|
| TDLUs with variably, usually mildly, dilated acini. Irregular internal contour | TDLUs with variably dilated, usually irregularly shaped, acinar contour | TDLUs dilated. Usually bluer than normal at low power. Typically, smooth internal contour to acini | TDLUs may be dilated. Usually bluer than normal at low power due to increased cell numbers |
| Acini lined by 1 to 2 cell layers | Acini lined by more than 2 layers of cells; may form tufts, but no complex architectural patterns | Acini lined by 1 or more layers of cells with a flat growth pattern (no complex architectural patterns) | Acini lined by 1 or more layers of cells. Complex architectural pattern |
| Lining cells bland, columnar in shape, with uniform ovoid to elongated nuclei oriented perpendicular to basement membrane | Lining cells bland, columnar in shape, similar to those in columnar cell change, with uniform ovoid to elongated nuclei oriented perpendicular to basement membrane. Nuclei may appear crowded and overlap | Acini lined by cells with low-grade (monomorphic) cytological atypia; cells most often resemble those seen in low-grade DCIS. Nuclei typically round, but may be ovoid in some cases | Low-grade (monomorphic) cytological atypia. Nuclei typically round, evenly spaced |
| Normal nuclear to cytoplasmic ratio | Normal nuclear to cytoplasmic ratio | Increased nuclear to cytoplasmic ratio | Increased nuclear to cytoplasmic ratio |
| Nucleoli absent or inconspicuous | Nucleoli absent or inconspicuous | Nucleoli may or may not be prominent | Nucleoli may or may not be prominent |

| | | | |
|--|---|--|---|
| Cells polarised | Cells polarised | Cells typically lack polarity, not regularly oriented perpendicular to basement membrane; however, in some cases, stratified, atypical, ovoid nuclei are arranged perpendicular to basement membrane (resembling pattern seen in colonic adenomas) | Cells polarised around architecturally atypical features, such as micropapillae and cribriform spaces |
| Luminal secretions may be present but are usually not prominent. Calcifications may be present | Luminal secretions may be present and prominent; calcifications often present may be psammomatous | Luminal secretions may be present and prominent; calcifications often present may be psammomatous | Luminal secretions may be present but are usually not prominent. Calcifications may be present |
| Mitoses infrequent | Mitoses infrequent | Mitoses infrequent | Mitoses infrequent |

5.4.2 Useful rules of thumb to distinguish ADH from DCIS

- Restrict diagnosis of ADH to those cases in which DCIS is seriously considered but where the features are not sufficiently developed to make a confident diagnosis.
- DCIS usually extends to involve multiple duct spaces. If a lesion with features of ADH extends widely, the diagnosis of ADH should be questioned.

5.5 Epithelial proliferation – present with atypia (lobular)

5.5.1 Atypical lobular hyperplasia and lobular carcinoma in situ (lobular neoplasia)

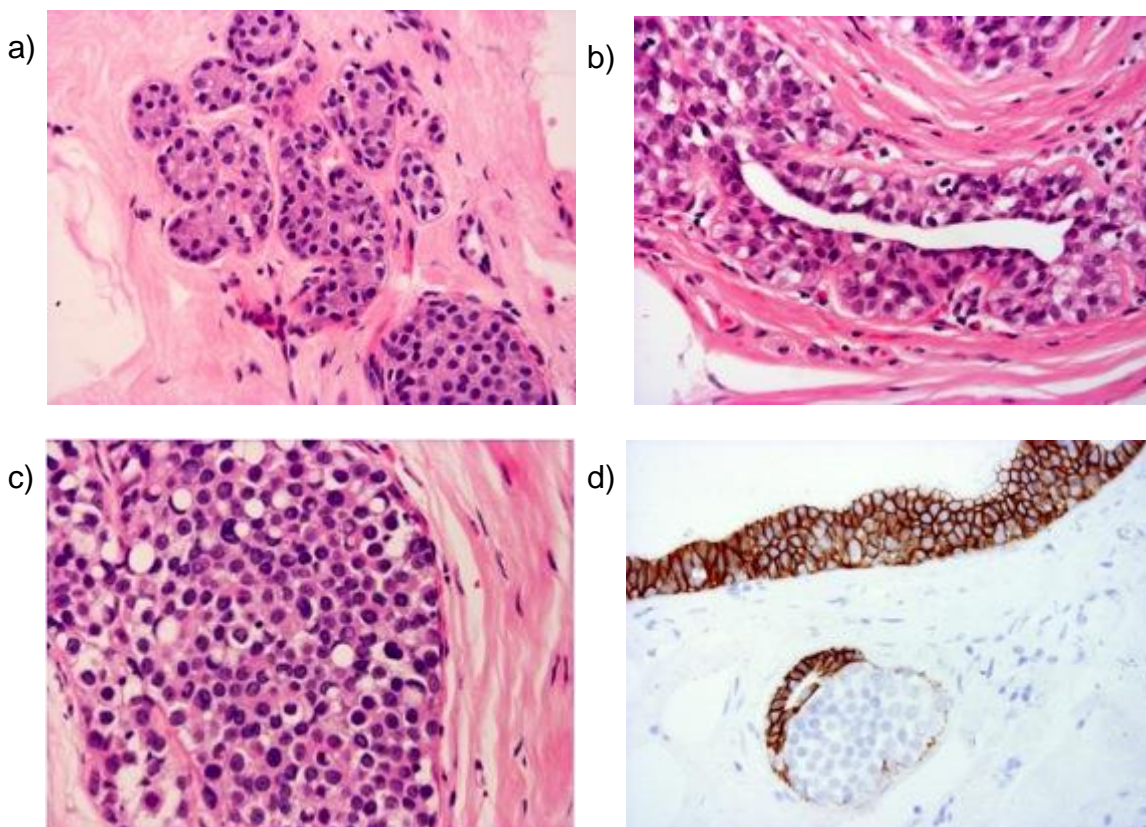
Atypical lobular hyperplasia (ALH) (Figures 27a and 27b) and classical LCIS (Figures 27d, 27e and 28a) have traditionally been separated as distinct entities based on cytological and quantitative features relating to the extent of lobular involvement.^{72,73} The justification for separating the entities is the differing risks of subsequent invasive cancer shown in long-term follow-up series, but molecular analysis suggests that biologically the 2 appear to be essentially similar and that these are neoplastic processes. In view of the subjective nature of separating ALH from classical LCIS and the similar molecular profiles, some experts have suggested that the 2 forms should be grouped together as 'lobular neoplasia'.⁷⁴ However, for the purposes of recording risk of subsequent invasive carcinoma and for Cancer Registry recording, when the degree and extent can be assessed – for example, in excision specimens – it is recommended that these are reported as separate entities. Very mild forms of ALH (Figure 27a) can be found in association with fibrocystic change, involution and otherwise normal breast tissue. No attributable risk has been shown for these mild forms and such lesions are often disregarded.

In cytological terms, the 2 forms of the lesion are identical; lobular neoplasia is characterised by proliferation within terminal duct lobular units (TDLU) of characteristic discohesive, round, cuboidal or polygonal cells with clear or pale cytoplasm. Nuclei are small to moderate in size, round to oval and cytologically bland, with an occasional small inconspicuous nucleolus (type A). Cells in classical LCIS may show mild to moderate variability in nuclear size and care needs to be taken not to overcall this form (type B) as pleomorphic LCIS (see 3.5.3). The cells have a high nuclear to cytoplasmic ratio. Mitotic figures and hyperchromatism are not often seen. There is an even distribution of cells and cellular monotony is the rule. Cytoplasmic clear vacuoles are often, although not invariably, present, sometimes having a central mucin blob which may indent the nucleus (Figure 27b, shown in pagetoid spread, and 27d). Pagetoid spread of cells may be present when the proliferation of neoplastic cells above the basement membrane undermines the normal lining epithelial cells (Figure 27b).

The distension of lobular units may be variable from mild to gross, resulting in either patent lumina or complete obliteration. In ALH, there is minimal expansion of less than half of the acini (Figure 27a), while in LCIS more than half of the acini within the TDLU are distended by an expansion of the typical cells (8 or more cells across each acinus) (Figure 27c).

In more extensive lesions, distinction between lobular neoplasia and DCIS may be difficult, for example when a regular, evenly spaced monotonous population is seen within both ducts and lobules. E-cadherin membrane reactivity (Figure 27d) may be useful in such cases in distinguishing in situ lobular neoplasia from DCIS as the latter typically shows strong membrane positivity, while in the former expression is absent or weak (see Appendix G). However, this marker can also be non-contributory or show varied levels within a case. For rare cases where E-cadherin is heterogeneous with true mixed ductal and lobular populations, or when the features are truly indeterminate, categorisation as both LCIS and DCIS is recommended to imply the precursor risk of DCIS and the bilateral cancer risk of in situ lobular neoplasia. Such cases should also be recorded as DCIS and LCIS on the reporting form.

Figure 27: Examples of ALH and LCIS (with classic cytology): mild ALH (a), ALH with pagetoid duct involvement (b), LCIS (c), lack of E-cadherin expression (d), and florid LCIS with marked expansion of acini (with associated invasive disease in this example) (e).



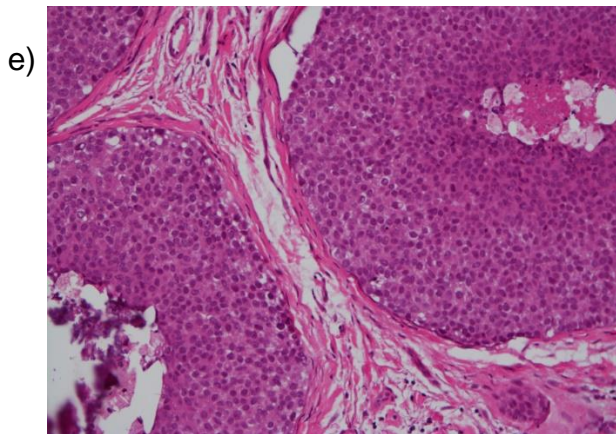


Table 4 illustrates the differences between DCIS and lobular neoplasia.

Table 4: Distinction of DCIS from lobular neoplasia (ALH/LCIS).

| Histological features | DCIS | Lobular neoplasia (classical) |
|---|--|--|
| Cells | Variable, depending on nuclear grade | Small, rounded with granular or hyperchromatic nuclei, inconspicuous nucleoli and high nuclear–cytoplasmic ratio |
| Intracytoplasmic lumina | Rare | Common |
| Growth pattern | Very variable, e.g. solid, comedo, papillary, cribriform | Diffuse monotonous with complete luminal obliteration |
| Cell cohesion | Usually good | Usually poor |
| Degree of distension of involved structures | Moderate to marked | Slight to moderate |
| Pagetoid spread into interlobular ducts | Rare | Often present |
| E-cadherin | Positive | Usually negative or abnormal (see Appendix G) |

5.5.2 Florid variant of lobular carcinoma in situ (Figure 27e)

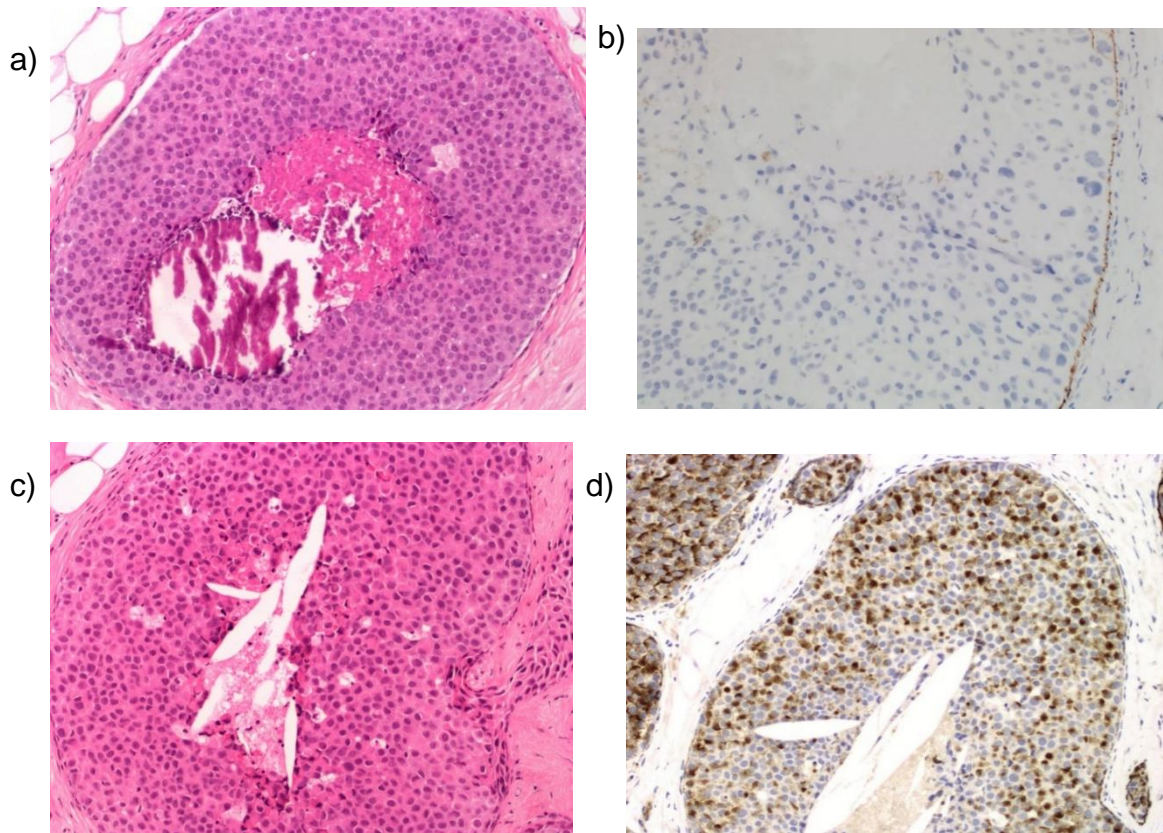
Florid LCIS has formally been included as a variant of LCIS in the 5th edition of the WHO Classification of Tumours of the Breast.¹ In florid LCIS, there is marked expansion of acini and/or ducts by a population of cells with the same cytological appearance as classical LCIS forming a confluent mass-like lesion. There may be associated central necrosis and often microcalcification.⁷⁵ For a diagnosis of florid LCIS, there should be little or no intervening stroma between the markedly expanded acinar units, and/or the dimension of the expanded acinus is at least 40–50 cells in diameter. Lesions that do not meet these criteria should be classified as classical LCIS even if extensive. As with pleomorphic LCIS (see section 4.5.3) there is extremely limited information on the clinical behaviour of florid LCIS; however, given the more aggressive molecular profile and higher upgrade rates to invasive malignancy, management akin to DCIS with wide local excision aiming for clear margins is currently recommended.

5.5.3 Pleomorphic variant of lobular carcinoma in situ (Figures 28a–d)

Pleomorphic LCIS shows the discohesion and architecture of classical LCIS, but the cells are larger and pleomorphic (cytonuclear grade 3, see Figure 28a) with more abundant cytoplasm. These should not be confused with type B cells of classical lobular neoplasia. Central necrosis and calcification are often seen (Figure 28b). Mitoses may be seen and atypical forms may be noted. Pleomorphic LCIS is less frequently ER-positive than classical forms and more often expresses HER2 oncoprotein. There is a paucity of information available on the clinical behaviour of pleomorphic LCIS, but it is widely regarded as a more aggressive form of the disease, which should be managed akin to DCIS based on its biological and molecular profile.⁷⁶ Similar to DCIS, the lesion should be included in the measurement of whole tumour size.

The terminologies ‘non-classical LCIS’ and ‘variant LCIS’ without specification are not recommended.

Figure 28: Examples of pleomorphic LCIS (a, c) showing a similarity of appearance to high-grade DCIS with associated central comedo-type necrosis (a). E-cadherin staining may be absent (b) or may show aberrant patterns such as perinuclear dot-like staining (d).



6 Classifying malignant non-invasive lesions

6.1 Ductal carcinoma in situ

Ductal carcinoma in situ (DCIS) is, in the vast majority of cases, a unicentric (involving a single duct system) proliferation of malignant epithelial cells within parenchymal structures of the breast.^{77,78} It may appear to be present as multiple foci on, even contiguous, histological sections because of the complex interweaving 3-dimensional structure of the breast ductal territories.⁷⁹

It is distinguished from invasive carcinoma by the absence of invasion across the basement membrane, which can be confirmed by immunostaining for myoepithelial markers. Despite the name, most DCIS is generally considered to arise from the terminal duct lobular units. The main points of distinction from lobular neoplasia are described in Table 4. Features in favour of DCIS are the greater cellular cohesion and readily visible cell membranes, typically larger cell size, cribriform or micropapillary architecture, cytoplasmic basophilia and lack of intracytoplasmic lumina.

DCIS varies in cell appearance, growth pattern and extent and is considered to represent a heterogeneous group of in situ neoplastic processes. DCIS is currently classified by cytonuclear grade, which is less variable within a lesion and shows an association with clinical outcome. Historical methods of classifying DCIS based on growth pattern are no longer recommended due to architectural variability often seen within an individual case and thus perceived lack of reproducibility. Lesions of high nuclear grade are recognised to be clinically more aggressive. Distinguishing between subtypes of DCIS is also of value for correlating pathological and radiological appearances, improving diagnostic consistency and assessing the likelihood of associated invasion as well as determining the probability of local recurrence.

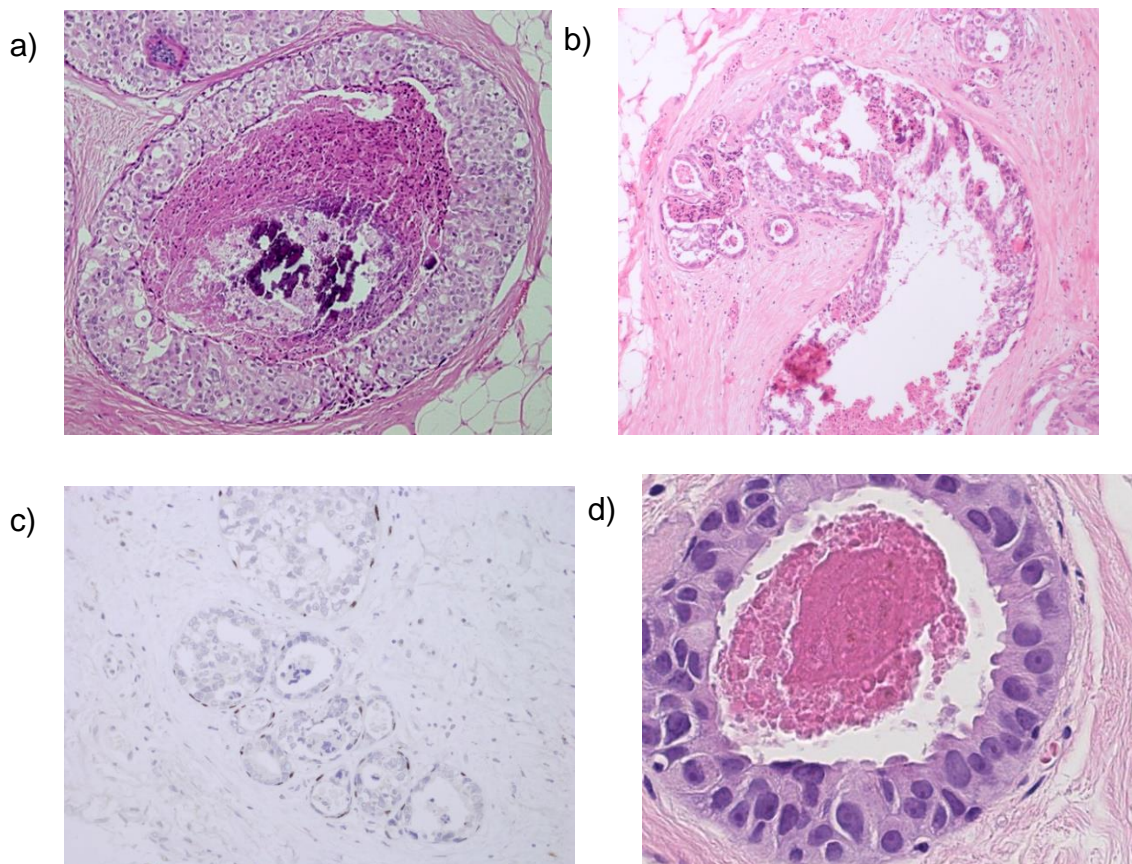
A high power lens (40x) should be used to compare the size of tumour cell nuclei with normal epithelial nuclear size and/or red blood cell size, as for the atypia/pleomorphism score in grading of invasive carcinoma.^{80,81}

Other features such as mitotic count, presence of prominent nucleoli and polarisation of nuclei may also help in refining cytonuclear grade. In particular, a high mitotic count is almost always associated with high grade DCIS.

6.1.1 High nuclear grade DCIS

Cells have pleomorphic, irregularly spaced, large nuclei exhibiting marked variation in size with irregular nuclear contours, coarse chromatin and prominent nucleoli (Figures 29a–d). Nuclei are large and greater than 2.5 times the size of erythrocytes or greater than 2 times the size of normal breast epithelial cells. Mitoses are usually frequent and abnormal forms may be seen. High-grade DCIS may contain solid, micropapillary or cribriform patterns. There may be associated central necrosis, which frequently contains deposits of amorphous calcification. Necrosis can be identified by the presence of ghost cells and is eosinophilic and granular in nature. Karyorrhectic debris should be present for diagnosis and the definition requires the presence of more than 5 pyknotic cells. Necrosis can be subdivided into central (comedo) necrosis and punctate (small foci) types. Unlike low nuclear grade DCIS, there is absent or minimal polarisation of cells covering the micropapillae or lining the intercellular spaces in high-grade lesions.

Figure 29: Examples of high-grade DCIS (a, b) with cancerisation of lobules (b) and of flat type (d). Use of myoepithelial stains can be useful (c) to demonstrate the preservation of myoepithelial cells and help confirm the diagnosis should there be concern about coexisting invasion.



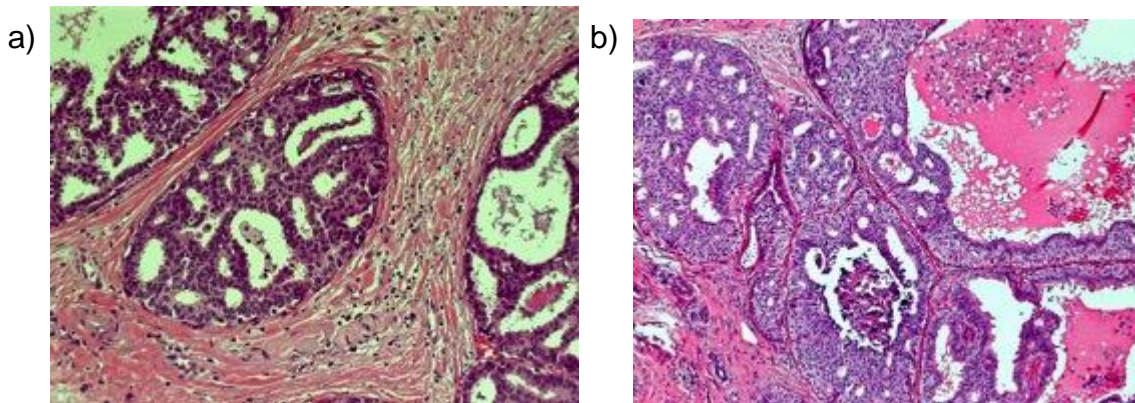
6.1.2 Flat high-grade DCIS

Dilated terminal duct lobular units lined by high-grade nuclei should be regarded as flat high-grade DCIS (Figure 29d) and not as columnar cell change. This is a rare type of DCIS and should be diagnosed with caution; it can be helpful that these lesions are often HER2 positive. It is important to note that, by definition, flat DCIS is always high grade.

6.1.3 Intermediate nuclear grade DCIS

Intermediate grade DCIS is a lesion that cannot be assigned readily to the high or low nuclear grade categories (Figures 30a and b). The nuclei show moderate pleomorphism, less than that in high-grade disease, but lack the monotony of low-grade type (a). The nuclei are larger than those seen in low-grade DCIS and are between 2 and 2.5 times the size of an erythrocyte in diameter and between 1.5 and 2 times the size of breast epithelial nuclei. The nuclear to cytoplasmic ratio is often high, and 1 or 2 nucleoli may be identified. The growth pattern may be solid, cribriform or micropapillary, or a combination (Figure 30b). The cells usually exhibit some degree of polarisation.

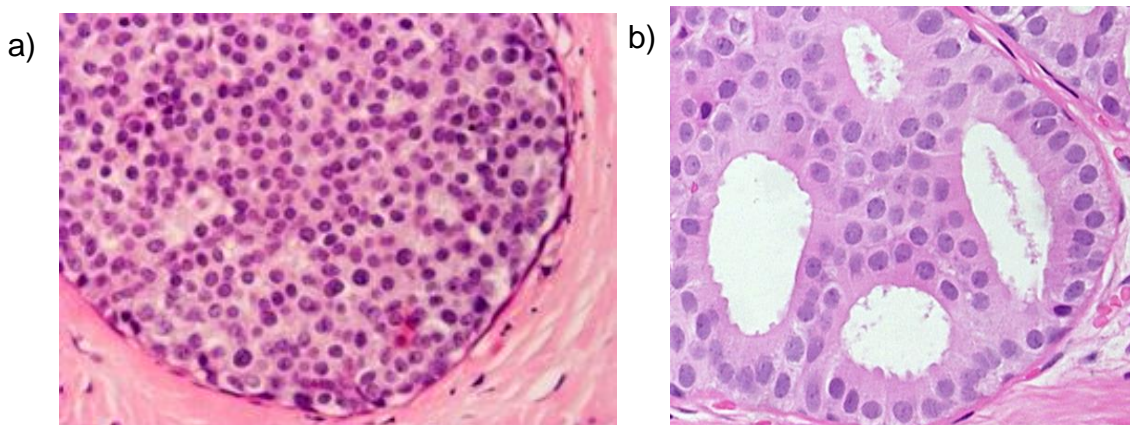
Figure 30. Examples of intermediate grade DCIS.



6.1.4 Low nuclear grade DCIS

Low-grade DCIS (Figures 31a and 31b and Table 2 and accompanying image) is composed of monomorphic, evenly spaced cells with rounded, centrally placed nuclei and inconspicuous nucleoli (Figure 31a). The nuclei are small and are typically up to 2 times the size of an erythrocyte in diameter or less than 1.5 times the size of breast epithelial cell nucleus. Mitoses are few and necrosis is only rarely seen. The cells are generally arranged in cribriform, micropapillary or solid patterns, often with a mixture of architectures seen (Table 2 and accompanying image). There is usually polarisation of cells surrounding luminal spaces and within micropapillae. Low-grade DCIS is distinguished from ADH largely based on extent of the lesion (see section 4.4).

Figure 31: Examples of low-grade DCIS of solid (a) and cribriform (b) types.



6.1.5 Mixed types of DCIS

A small proportion of cases of DCIS exhibit areas of differing nuclear grades. If present, the case should be classified by the highest nuclear grade present.

6.2 Rarer subtypes of DCIS

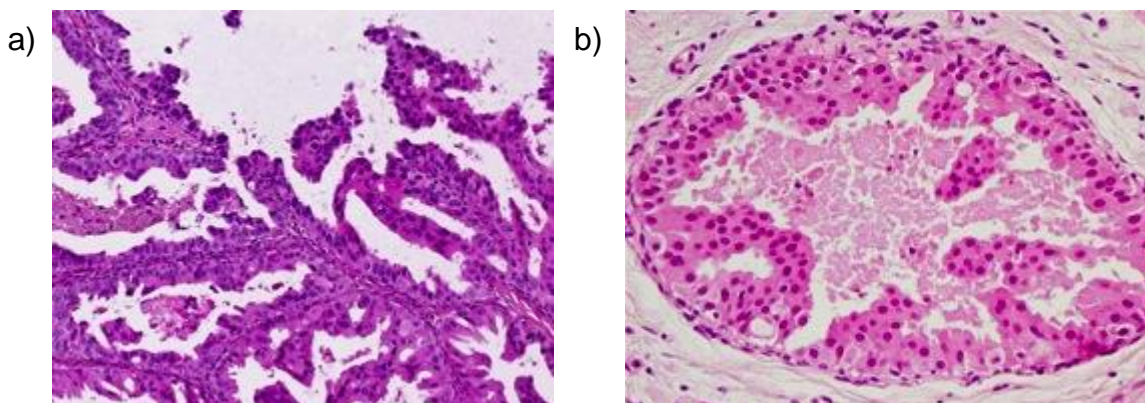
Other rare, but morphologically distinct, subtypes of DCIS are recognised. There is, however, no firm evidence to support the distinction of these uncommon special DCIS types from commoner DCIS forms with regard to clinical presentation and/or behaviour, with the exception of encapsulated papillary carcinoma and solid papillary carcinoma in situ (see 6.3.3 and 6.3.4).

6.2.1 Apocrine DCIS

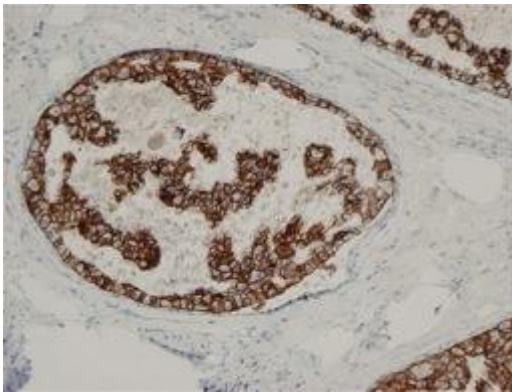
The cells in this form of DCIS (Figures 32a–c) show the typical abundant granular cytoplasm of apocrine lesions but with cytological atypia (Figure 32a). This is most commonly of marked degree, sometimes moderate, and frequently there is central necrosis.⁸² Apical snouting (cytoplasmic protrusions) is not always seen. Variation in nuclear size can be seen in benign apocrine lesions; a diagnosis of apocrine DCIS should be made with caution, particularly in the absence of marked pleomorphism, conspicuous mitoses and/or necrosis (i.e. if not high grade) (Figure 32b).^{25,41} In difficult cases, strong, complete membrane HER2 positivity (i.e. 3+, also see section 8) may also be helpful if present (Figure 32c).

It is difficult to separate atypical apocrine hyperplasia from low-grade apocrine DCIS; the extent of the lesion and altered architectural growth pattern are distinguishing features (see section 4.6.2). Benign apocrine change is frequent in breast biopsy material and is recognised to show nuclear variability, which should not be interpreted as DCIS. Atypical apocrine change, for example within sclerosing adenosis, may also mimic apocrine DCIS or even invasive apocrine carcinoma. Identification of mitoses, periductal inflammation and fibrosis may be helpful as they are rarely seen in atypical apocrine hyperplasia or apocrine proliferations other than DCIS.

Figure 32: Examples of apocrine DCIS showing abundant granular eosinophilic cytoplasm with cytological atypia (a, b), which can show HER2 positivity (c).



c)



6.2.2 Clear cell DCIS

This is an intraductal proliferation of neoplastic cells with optically clear cytoplasm and distinct cell margins forming cribriform and solid structures. Central necrosis may be present. This may be mimicked by poor fixation in other forms of DCIS and care should be taken to achieve optimum fixation of all breast samples, as noted above.

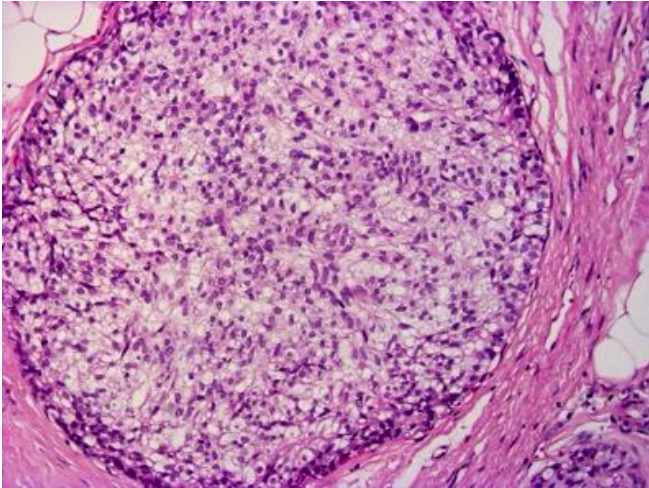
6.2.3 Signet ring DCIS

This is a very rare variant characterised by the proliferation of signet ring cells in solid or papillary growth patterns. The cytoplasm stains positive with diastase resistant periodic acid-Schiff (PAS) or Alcian blue. This may mimic LCIS with prominent intracytoplasmic vacuoles; immunohistochemical staining for E-cadherin will often help distinguish these 2 lesions.

6.2.4 Neuroendocrine DCIS

This lesion has an organoid appearance with prominent argyrophilia, cytologically resembling a carcinoid tumour (Figure 33). The neoplastic cells may be arranged in a solid pattern or may form tubules, pseudorosettes, palisades or ribbons. Eosinophilic cytoplasmic granularity or spindle morphology are all supportive of a neuroendocrine phenotype. The latter may mimic the streaming seen in usual epithelial hyperplasia.⁸³ Immunohistochemical stains for neuroendocrine markers (chromogranin, CD56 and synaptophysin) may be helpful in diagnosis of this subtype of DCIS.⁸⁴ Neuroendocrine DCIS also typically strongly and uniformly expresses ER, which is helpful diagnostically compared to the mosaic pattern typical of usual epithelial hyperplasia. Neuroendocrine differentiation is also commonly seen in solid papillary carcinoma and the 2 may be admixed (see section 5.3.4). Because of the lack of microcalcification, these tumours tend to present symptomatically, most commonly in older patients with blood-stained nipple discharge.

Figure 33: An example of neuroendocrine DCIS with clear cell features.



6.2.5 Cystic hypersecretory DCIS and mucin-secreting DCIS

These uncommon types of DCIS are variants of micropapillary DCIS. The cells produce mucinous secretions, which distend involved duct spaces, thereby giving a cystic appearance.⁸⁵ Microcalcifications are often a very prominent feature.

6.3 Intraductal papilloma with DCIS, papillary DCIS, encapsulated papillary carcinoma and solid papillary carcinoma

Classification of papillary lesions depends on the presence or absence of cytological atypia within the epithelial component and whether there is preservation of a myoepithelial layer lining the fibrovascular cores and/or surrounding the lesion.

6.3.1 DCIS in papilloma

Benign papillomas often contain an associated epithelial proliferation that may be florid. Most commonly the appearances will be those of usual epithelial hyperplasia, often with focal apocrine change. Assessment of the epithelial proliferation within papillomas should be undertaken as for intraductal epithelial proliferation, as above, and the nature of the epithelial proliferation can be assessed by IHC.

However, an atypical epithelial proliferation with solid or cribriform growth patterns may be present focally or throughout the papilloma lesion; the atypical cells typically show mild nuclear pleomorphism. To classify the lesion, the extent of atypia should be determined, and the lesion categorised as:

- atypia within a papilloma if less than 3 mm or
- low-grade DCIS within a papilloma if equal or more than 3 mm in extent.⁸⁶

Intermediate or high nuclear grade DCIS in a papilloma should be regarded as DCIS irrespective of extent.

The term atypical papilloma is not recommended.

Residual benign papilloma can be identified by preservation of a myoepithelial layer between the epithelium and the fibrovascular cores, which are often broad and sclerotic, and around the exterior of the lesion. In contrast, in papillary DCIS (papillary carcinoma in situ) (see below) the myoepithelial cell layer is preserved around the outside (i.e. the duct wall) but absent, at least focally, within the fibrovascular cores.

6.3.2 Papillary DCIS/papillary carcinoma in situ/intraductal papillary DCIS

A number of acceptable terms can be used for this form of DCIS with papillary architecture typically composed of dilated duct spaces containing delicate fibrovascular cores covered by neoplastic epithelium, which may show tall columnar morphology, most commonly of intermediate nuclear grade. Other more typical variants of DCIS are often seen in association.

Papillary DCIS (as distinct from a papilloma in which there is associated DCIS) lacks a myoepithelial layer between the fibrovascular cores and the overlying epithelium, but this is preserved at the periphery of the duct space, which can be confirmed with IHC for myoepithelial markers (see Appendix G).

Table 5: Distinction of papilloma from papilloma with atypia/DCIS, papillary DCIS and encapsulated papillary carcinoma (all the features of a lesion should be taken into account when making a diagnosis; no single criterion is reliable alone).

| Features | Papilloma | Papilloma with atypia/DCIS | Papillary DCIS | Encapsulated papillary carcinoma |
|-------------------------|---|---|---|---|
| Periphery of the lesion | Peripheral myoepithelial cell layer present | Peripheral myoepithelial cell layer present | Peripheral myoepithelial cell layer present | Circumscribed, frequently surrounded by a thick 'capsule' Peripheral myoepithelial cell layer absent |

| | | | | |
|-------------------------|---|---|---|---|
| Fibrovascular cores | Usually broad and extend throughout lesion | Usually broad and present in benign papilloma component | Variable, usually fine | Very variable, usually fine May be lacking in at least part of the lesion |
| Cells covering papillae | 2 cells types Myoepithelial layer always present Single layer of regular luminal epithelium OR features of regular usual type hyperplasia | 2 cell types present in benign papilloma component. Myoepithelial cell layer evident in benign papilloma component. For a low-grade epithelial proliferation within a papilloma, 3 mm extent is used to differentiate between ADH (<3 mm) and low-grade DCIS (\geq 3 mm). A diagnosis of intermediate or high-grade DCIS within a papilloma is made | 1 cell type Myoepithelial cells absent within the lesion 1 or more layers of atypical epithelial cells. Nuclei may be hyperchromatic | Usually 1 cell type Myoepithelial cells absent within and around the lesion Epithelial cells often taller and more monotonous with oval nuclei, the long axes of which lie perpendicular to the stromal core of the papillae. Nuclei may be hyperchromatic Epithelial multi-layering is frequent, often producing cribriform and micropapillary patterns overlying the |

| | | | | |
|--|---|---|---|---|
| | | regardless of extent | | papillae or lining the wall |
| Mitoses | Infrequent, no abnormal forms | May be present within atypical foci or DCIS | More frequent, abnormal forms may be seen | More frequent, abnormal forms may be seen |
| Apocrine metaplasia | Common | May be seen within the benign papilloma component | Not seen | Rare |
| Adjacent tissue | Benign changes may be present, including usual epithelial hyperplasia | Surrounding tissue may show varied histological change including atypia and/or DCIS | Surrounding ducts may bear DCIS | Surrounding ducts may bear DCIS |
| Necrosis and haemorrhage | May be present | Necrosis within atypical proliferation suggests DCIS | May be present | May be present |
| Periductal and intra-lesional fibrosis | May be present | May be present | May be present | Usually present |

6.3.3 Encapsulated papillary carcinoma

Encapsulated papillary carcinoma (Figure 34) is the preferred term for lesions previously also called intracystic or encysted papillary carcinoma. This is a distinctive lesion, which is more common in older women. Encapsulated papillary carcinoma is a lesion with the central appearance of papillary DCIS (papillary carcinoma in situ) typically surrounded by a fibrous wall, giving an encapsulated appearance. Haemosiderin (or haematoidin) pigment and a lymphocytic population are often seen within the pseudocapsule. Although the absence of a myoepithelial component within the papillary lesion (between the epithelium

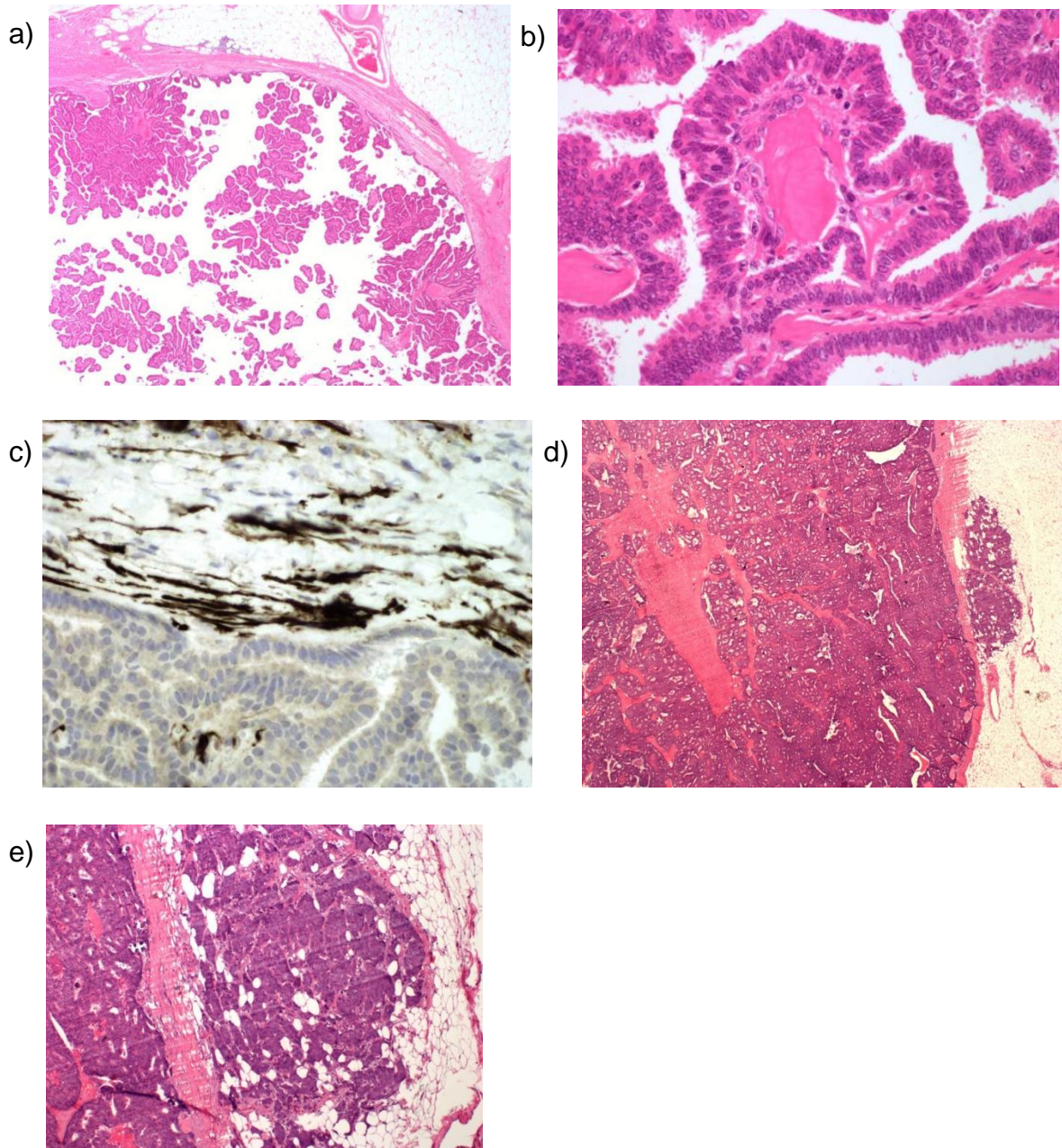
and the fibrovascular cores) is a diagnostic criterion, it is now recognised that encapsulated papillary carcinomas also lack a myoepithelial cell population around the outside of the lesion (Figure 34c).^{87,88} This can be used to distinguish papillary DCIS, which can be shown to lie within a duct structure with a surrounding myoepithelial population, from the encapsulated variant. As for papillary DCIS, there may be associated DCIS in the surrounding tissue, which is recognised to be of significance regarding local recurrence and should be recorded.⁸⁹

In view of the absence of myoepithelial cells surrounding the lesion, this is considered an indolent form of invasive breast carcinoma, but with behaviour akin to DCIS and with an excellent prognosis.⁹⁰ Encapsulated papillary carcinoma is regarded as in situ carcinoma for staging, coding and clinical management purposes. Cytonuclear grade should be recorded as per DCIS (see above). In some centres where hormone receptor status is routinely examined for DCIS, this will be performed on encapsulated papillary carcinoma, but HER2 is not performed unless conventional invasive carcinoma is present.

Invasive carcinoma arising in the setting of papillary DCIS or encapsulated papillary carcinoma should be classified according to its own histological features for tumour type (typically NST but a range of histological types may be seen) and grade etc. and does not represent, per se, the entity of invasive papillary carcinoma.

Invasive carcinoma should only be recorded when irregularly shaped cords or islands of carcinoma extend outside the pseudocapsule of the papillary carcinoma. If such unequivocal invasion is identified, the size of this invasive component only is used for determining prognostic parameters. Measurement of invasive size is simple when a single focus of invasion is present at 1 aspect of the papillary lesion, however it can become difficult when there are multiple foci of invasion around the periphery. A pragmatic approach is advised to avoid overestimating invasive tumour volume. If there are 2 or 3 separate invasive foci around the edge, then it is recommended that this should be recorded as multiple invasive foci and the size of the largest single focus used for staging purposes. If there are more foci of invasion, distributed around the periphery, then the lesion should be measured as a single invasive tumour and the maximum distance across all invasive foci recorded. Whole tumour size includes the maximum dimension of both the in situ/encapsulated component and the invasive disease, as for cases of invasive carcinoma with conventional DCIS.

Figure 34: Encapsulated papillary carcinoma. Low power view showing circumscribed lesion with external fibrous capsule (a). Higher power shows delicate fibrovascular cores lined by columnar cells with moderate atypia (b). Note the lack of myoepithelial cells throughout with smooth muscle myosin stain (c). Encapsulated papillary carcinoma with associated invasive carcinoma NST formed by infiltration of nests of cells beyond the capsule (d and e).



6.3.4 Solid papillary carcinoma

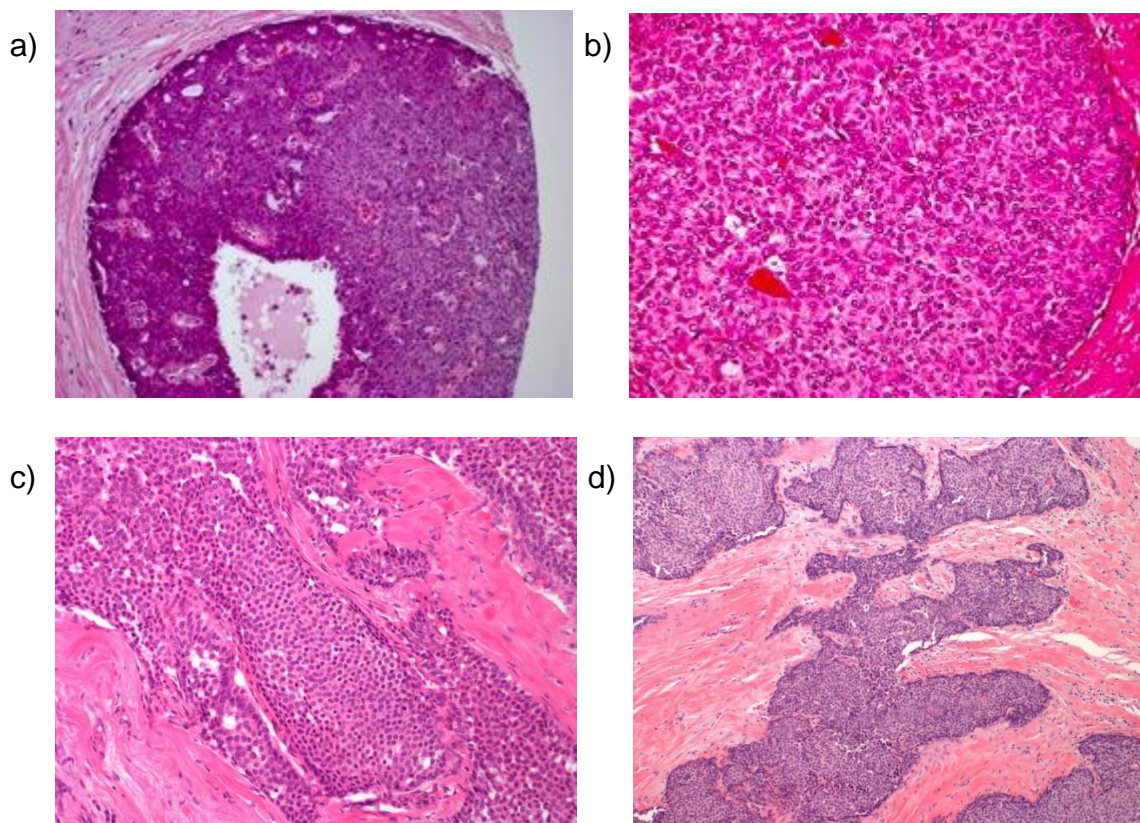
Solid papillary carcinoma may be either in situ or invasive in nature (Figure 35).

Solid papillary carcinoma in situ is composed of smoothly contoured expansile nodules of a solid epithelial proliferation, which may or may not have an external myoepithelial layer. The cells are round to spindle-shaped cells with delicate, sometime inconspicuous, fibrovascular cores, thus the papillary architecture may not be apparent at low power.

Neuroendocrine features and extracellular mucin may be present and there is usually mild to moderate cytonuclear atypia. Invasive carcinoma may be associated with solid papillary carcinoma in situ (as with other forms of papillary carcinoma in situ) and may be of a range of histological types, including mucinous and NST, and should not be classified as either invasive papillary carcinoma or invasive solid papillary carcinoma.

Invasive solid papillary carcinoma is diagnosed when the islands of cells not only lack a myoepithelial layer but have a jagged, irregular contour with smaller infiltrating nests creating a jigsaw pattern within background stromal desmoplasia, or when extracellular mucin separates the edge of the cell nests from adjacent stroma.

Figure 35: Solid papillary DCIS (a, b) with smooth rounded external contours and delicate internal fibrovascular cores. In contrast, invasive solid papillary carcinoma has irregular jagged outlines giving a jigsaw or geographic pattern (c, d).



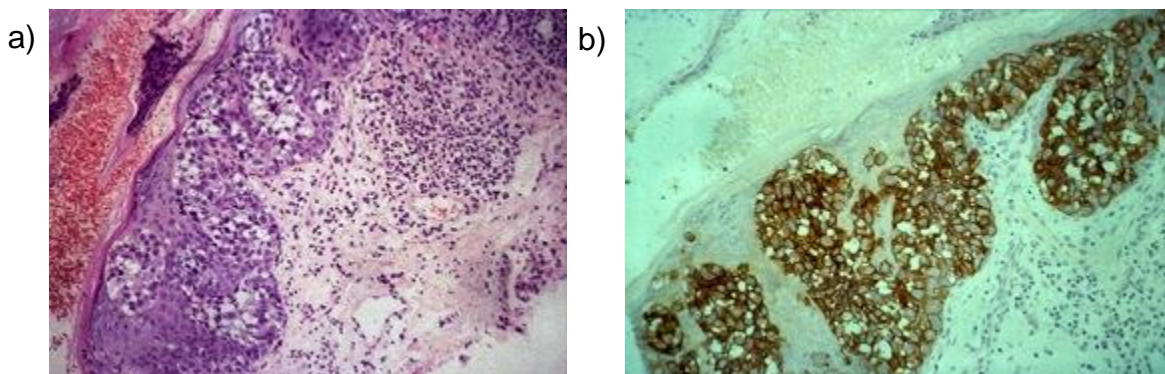
6.4 Paget's disease of the nipple

In this condition (Figure 36), adenocarcinoma cells are present within the epidermis of the nipple (Figure 36a), but not through direct invasion from the dermis.⁹¹ Paget's disease arises in the presence of underlying high-grade DCIS, although, exceptionally rarely, this may not be identified histologically despite thorough sampling. There may be associated invasive disease arising from the DCIS, but this is less common than historically reported. The malignant cells in the epidermis are typically high grade, CK7, CAM 5.2 and HER2

positive (see Appendix G for immunohistochemical guidance and Figure 36b). Distinction from intraepidermal squamous cell carcinoma and melanoma can be made on the basis of morphological and immunocytochemical features (see Appendix G). Normal glandular cells, e.g. Toker cells, may be present in the nipple epidermis and may undergo hyperplasia; care must be taken not to interpret all CK7 positive cells as Paget's disease in the absence of cytological atypia. Toker cells are HER2-negative.

The underlying carcinoma (DCIS plus invasive carcinoma, if present) should be recorded and assessed separately for prognostic factors although the DCIS size/whole tumour should include the Paget's disease cells, if this is in the plane of the maximum dimension.

Figure 36: Paget's disease of the nipple (a) which typically is associated with underlying high-grade DCIS and shows HER2 positivity (b).



6.5 Microinvasive carcinoma

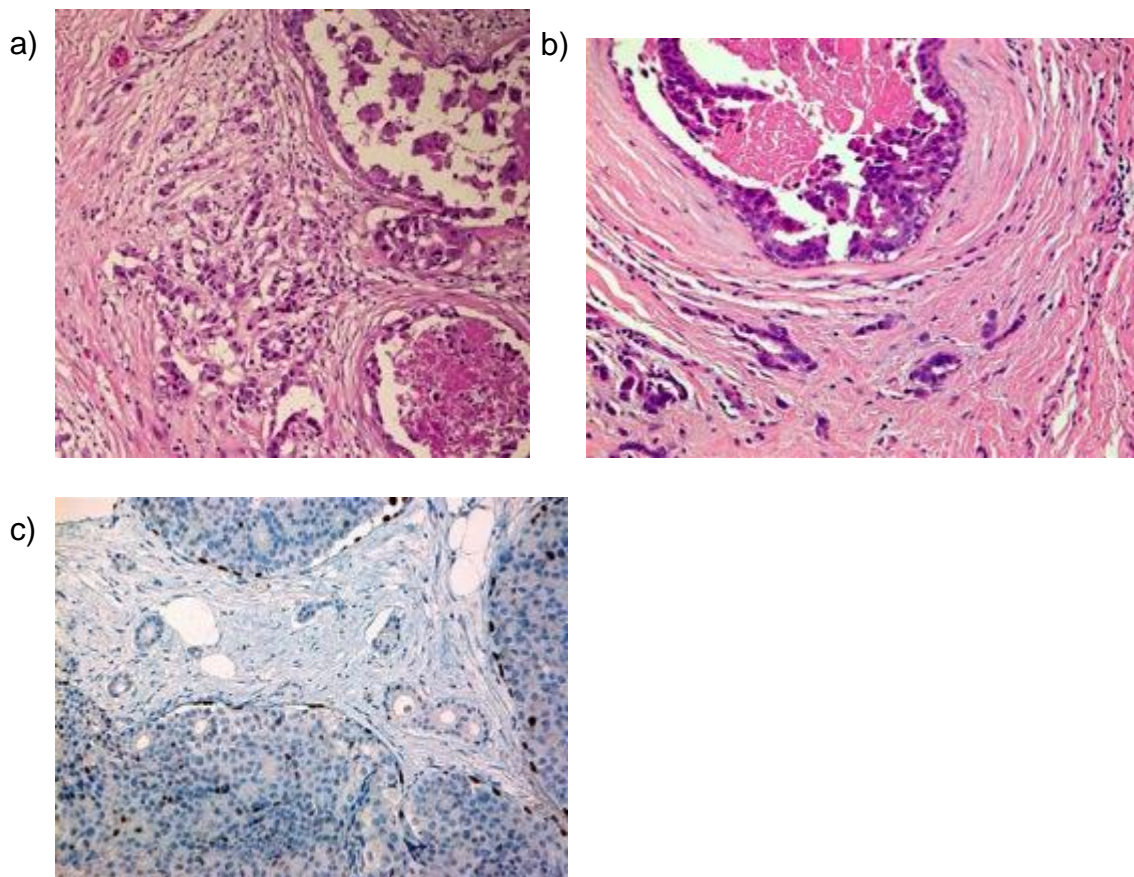
Microinvasive carcinoma (Figure 37) consists of 1 or more separate foci of invasion measuring 1 mm or less in maximum dimension.⁹² This typically occurs in the context of extensive high-nuclear-grade DCIS. Microinvasion is extremely rare in non-high-grade disease but may be seen and may even, rarely, be associated with LCIS.

True microinvasive carcinoma is rare. Suspicious foci are often shown to be cancerisation of lobules or, rarely, true invasive carcinoma in deeper sections. Care should be taken to avoid overdiagnosis of cancerisation of lobules, or of sclerosing lesions, as microinvasive carcinoma. The organoid arrangement of cancerisation of lobules should be sought and deeper H&E sections are often more helpful than immunohistochemical examination. However, myoepithelial markers (e.g. smooth muscle myosin heavy chain [SMMHC] and p63) (Figure 37c) or basement membrane (laminin and collagen IV) markers may assist in the diagnosis (Appendix G). A pancytokeratin marker may also be valuable to highlight single or small irregular clusters of epithelial cells, for example, in the background of abundant lymphoid cells associated with the DCIS.

If there is doubt about the presence of microinvasion, the case should be classified as pure DCIS only. If several foci of microinvasion are present, the number of foci should be recorded.

Excision specimens for large areas of high-grade DCIS should be extensively sampled to look for foci of microinvasive or invasive (>1 mm) disease. The presence of microinvasion should be a prompt to look for further foci of microinvasion or true invasion, as these are commonly associated.

Figure 37: Microinvasive carcinoma (a, b), which can be confirmed through lack of surrounding myoepithelial cells, shown as an absence of p63 staining in (c).



6.6 Epithelial displacement in breast tissue following needle/core biopsy

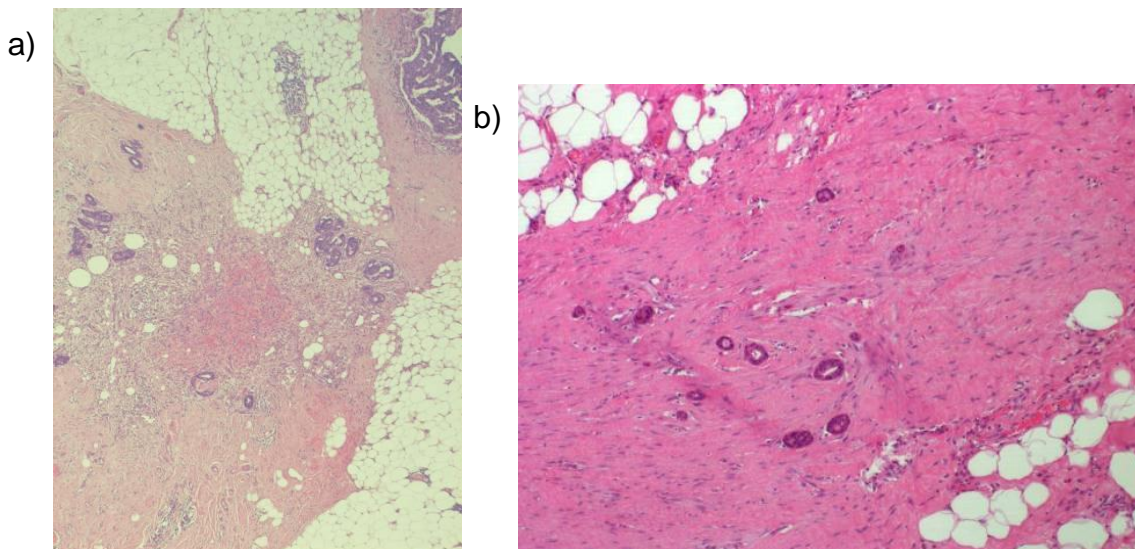
Seeding of the needle tract by benign, hyperplastic and/or malignant epithelial cells may be seen along fine needle aspiration (FNA), core biopsy or VAB tracts and may cause diagnostic problems in subsequent surgical excision or VAE specimens (Figure 38). Indeed, this is particularly often seen in VAE specimens, as there is typically a shorter delay following the initial core biopsy specimen.⁹³

The lesions most commonly associated with epithelial displacement are papillary lesions, from benign ductal papillomas through to encapsulated papillary carcinoma.⁹⁴ However, epithelial displacement from other lesions such as radial scars and even gynaecomastia following liposuction in males has been reported.

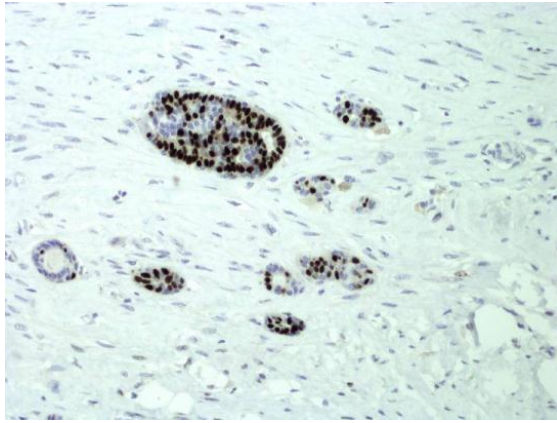
IHC for myoepithelial cells is no value in distinguishing displaced epithelial cells from small invasive foci, since both will lack a surrounding myoepithelial layer. If the displaced cells are from a benign, non-clonal process, IHC for ER and CK5 or CK14 may be helpful when showing heterogeneity of expression (Figure 38c). However, distinguishing displaced cells from invasive carcinoma depends on careful consideration of the history of previous biopsy, the nature of the lesion in that prior specimen, the assessment of the cytology and, most importantly, the presence of associated needle tract changes intimately associated with the epithelial cells. These changes may include the presence of haemorrhage and/or haemosiderin, a fibroblastic proliferation, fat necrosis and foamy macrophages in the immediately adjacent area. Identification of epithelial cells beyond the core biopsy tract changes, particularly if extensive, should raise alarm.

[Level of evidence – GPP.]

Figure 38: Epithelial displacement. The displaced cells are confined to the linear tract of granulation tissue with associated fat necrosis (a, b). If the source is a benign lesion such as a papilloma, ER staining can be helpful as the displaced cells may show heterogeneous staining (c).



c)



7 Classifying invasive carcinoma

Typing invasive carcinomas has prognostic value and provides information on the likely pattern of metastatic spread and behaviour. For example, pure grade 1 tubular carcinoma has an exceptionally good long-term prognosis when compared with other grade 1 NST carcinomas. Lobular and metaplastic carcinomas typically show poor response to chemotherapy.

Caution should be exercised in typing carcinomas in poorly fixed specimens or residual carcinoma deposits present post-neoadjuvant chemotherapy.

Typing of invasive breast carcinoma has been shown in the NHSBSP EQA scheme to be relatively poorly reproducible. The system has previously been revised with emphasis on concordance and recognition of pure special types and definition of the mixed type.

It is also important to note that clinically, all invasive breast cancers are grouped into the following biomarker-defined subtypes/groups which, along with histological grade and lymph node stage, are used for treatment purposes, as per NICE recommendations:⁹⁵

1. ER-positive, HER2-negative, 2. ER-positive, HER2-positive cancers, 3. ER-negative, HER2-positive cancers, and 4. ER-negative, HER2-negative cancers.

7.1 Tumour type categories

7.1.1 Pure special type

A pure special type invasive tumour is a classical example, showing the hallmark histological features, and is one that other histopathologists would recognise as such. The definition requires 90% of the tumour to show the classical features (e.g. a tumour showing 90% mucinous features is classified as being of pure mucinous carcinoma type, etc.).

Special type tumours in general have characteristic, usually favourable, clinical prognostic characteristics, as described later.

7.1.2 Invasive carcinoma of no special type

The invasive tumour shows none, or up to 10%, of a special type tumour morphology. This is the commonest category of invasive breast cancer and historically was described as invasive ductal carcinoma. However, in view of the lack of specific defining histological characteristics the term invasive carcinoma, no special type (NST or no specific type) is preferred (see section 7.2.1 below).

7.1.3 Mixed invasive tumour

This is a relatively common pattern of invasive breast carcinoma, most commonly mixed NST and a special subtype. Typically, there are defined areas of the special type and NST, rather than a diffuse resemblance to the special type through the lesion. The tumour is thus heterogeneous in morphology with some characteristic special type areas (more than 10% but less than 90%); for example, there may be areas of pure tubular differentiation within a tumour otherwise showing NST features. For lesions of mixed subtypes, it is recommended that all elements present are noted, ideally as well as the overall percentage of the special subtype – for example, mixed NST and mucinous carcinoma (70% mucinous).

For histological grade, all components should be considered (for example, regarding tubule/acinar formation), with the final grade based on the higher-grade component. If a mixed tumour shows a morphologically different component or a higher-grade component that was not identified in the preoperative biopsy, repeating receptor assays is recommended.

Cancers with <10% special subtype should be classified as NST, although the focal special subtype can be described in the report. Cancers with >90% specialised type should be classified as special type.

7.1.4 Other primary breast carcinoma

Other primary breast carcinomas should be entered under this heading and include variants such as salivary gland type tumours (e.g. adenoid cystic carcinoma) and secretory carcinoma.

7.1.5 Other malignant tumour

Non-epithelial tumours and secondary malignancies are included in this category. For purposes of classification, malignant phyllodes tumours should be recorded here.

7.1.6 Not assessable

This category should be ticked only if an invasive carcinoma cannot be assigned to any of the previous groups for technical reasons, e.g. the specimen is too small or poorly preserved.

7.2 Morphological types of invasive breast cancer

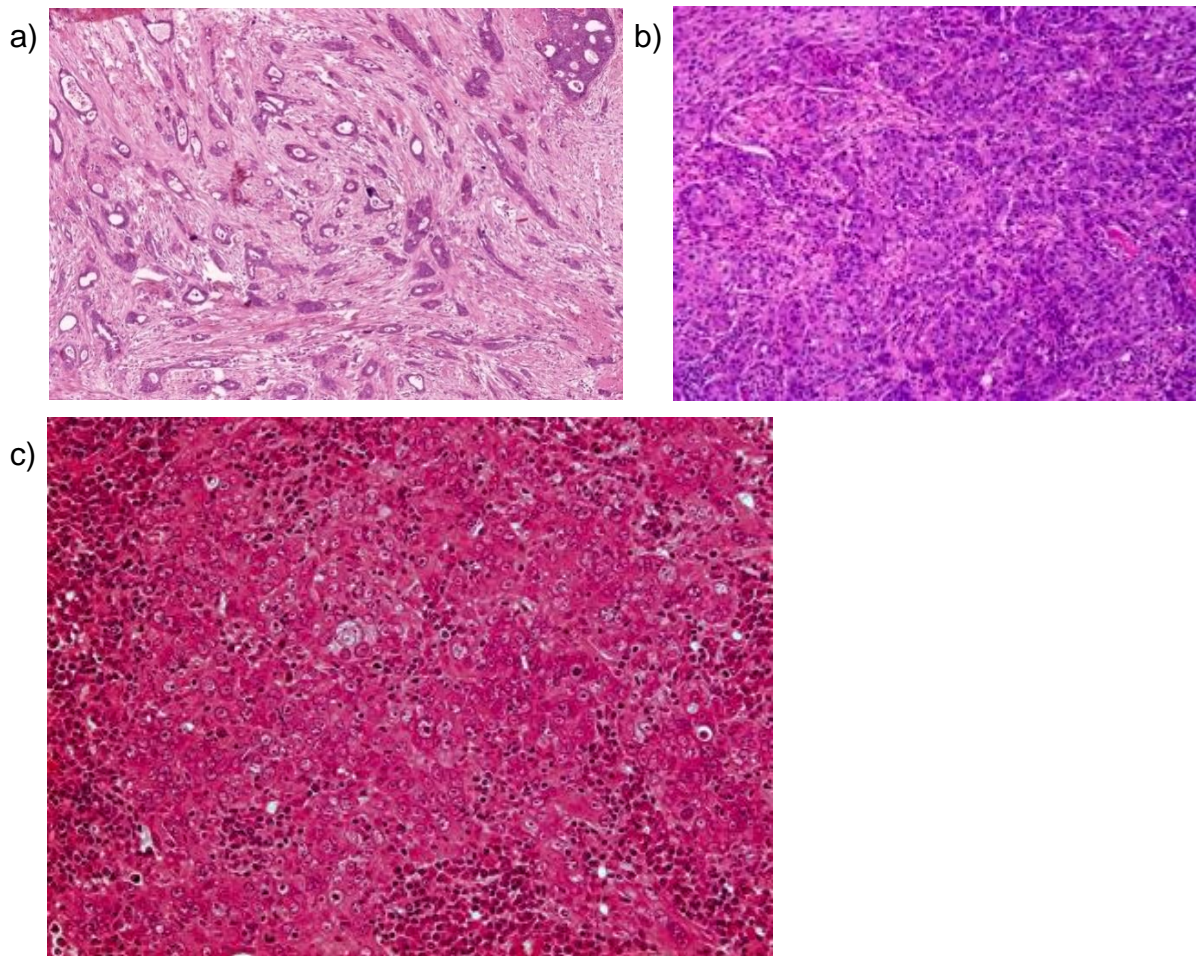
The more common types are described below.

7.2.1 Invasive carcinoma of NST

This group includes invasive carcinomas that cannot be entered into any other category on the form, or classified as any of the less common variants of invasive breast carcinoma (Figures 39a–c). The tumour shows less than or equal to 10% special type characteristics. Invasive carcinomas of NST are the most common invasive breast carcinomas, accounting for up to 75% in published series. They constitute a heterogeneous group in terms of morphological appearances including cytonuclear appearances and growth pattern, presence or absence of a lymphoid reaction, histopathological prognostic parameters and tumour marker biology.

Some high-grade NST invasive carcinomas display a medullary pattern or basal-like pattern. Other carcinomas also previously classified as specific subtypes, such as oncocytic, lipid-rich, glycogen-rich/clear cell and sebaceous carcinomas, are very rare and are felt to lack sufficient clinical evidence for designation as special types; these are also considered part of the spectrum of differentiation seen in NST carcinomas. Similarly, invasive carcinoma with focal neuroendocrine differentiation, carcinomas with pleomorphic or choriocarcinomatous patterns and those with melanocytic features are now considered to be morphological forms of NST, regardless of the extent of pattern.

Figure 39: Examples of invasive carcinoma of no special type. c: An example of NST with medullary pattern. Note the syncytial sheet tumour cell structure.



Invasive carcinoma with medullary pattern

This entity has undergone re-classification several times (Figure 39c). While medullary carcinoma and atypical medullary carcinoma were previously considered specific entities, these lesions were subsequently recorded as having ‘medullary-like features’. Most recently the 2019 WHO guidelines¹ recommend regarding these as NST variants (morphologic pattern). These tumours demonstrate all or some of the following features: a circumscribed or pushing border, a syncytial growth pattern, cells with high-grade vesicular nuclei with prominent nucleoli and prominent lymphoid infiltration. However, there is poor interobserver reproducibility of classification and overlap in features with carcinomas that have basal-like molecular profiles, carcinomas associated with BRCA1 mutations and some NST lesions with lymphoid rich stroma. Therefore, these tumours, as well as ‘basal-like’ carcinomas, are now considered variants of NST carcinoma rather than a distinct morphologic subtype.

7.2.2 Invasive lobular carcinoma

Invasive lobular carcinoma (Figure 40) is composed of small to moderately sized regular cells identical to those seen in lobular neoplasia.⁹⁶ The cells frequently contain intracytoplasmic lumina, although this finding is not specific to lobular carcinoma. Mitoses are typically infrequent. In classical invasive lobular carcinoma, the cells are dissociated from each other to typically form single files. Targetoid patterns around uninvolved ducts may be seen. Associated lobular neoplasia may be present.

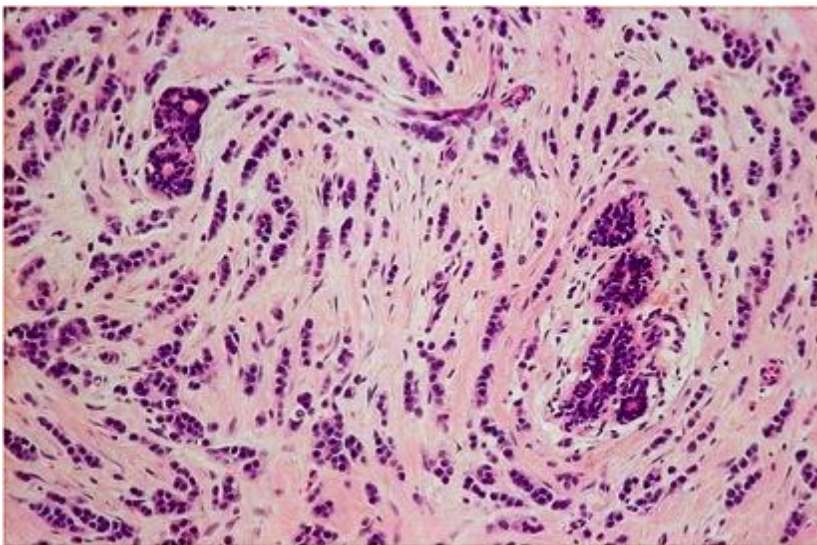
Several variants have been identified in addition to this classical form.

- The pleomorphic variant is uncommon and exhibits the growth pattern of classical lobular carcinoma but the cytological appearances, although retaining lobular characteristics, are more pleomorphic than those seen in classical invasive lobular carcinoma with a grade pleomorphism score of 3. Apocrine or histiocytoid differentiation may be seen in this variant. Pleomorphic invasive lobular carcinoma may also be accompanied by pleomorphic LCIS (see section 5.5.3).
- The solid variant consists of sheets of cells with little interspersed stroma. These lesions lack either tubule formation or cell cohesion (and are typically E-cadherin, beta-catenin and p120 negative), like other lobular carcinomas. Mitotic activity is more frequent than in classical invasive lobular carcinoma and some degree of pleomorphism can be seen.
- The alveolar variant is rare and is formed from small aggregates of 20 or more cells displaying cytonuclear features similar to the classical variant.
- Tubulo-lobular carcinoma is rare and exhibits the classical architectural pattern of lobular carcinoma but together with microtubule formation. This is not equivalent to mixed classical lobular and tubular carcinoma, when the tubules are typically larger and angulated. Tumours that show mixtures of typical tubular and classical lobular carcinomas should be classified as mixed (see above).
- Lobular mixed carcinoma consists of mixtures of the above subtypes of lobular carcinoma where all/both components are of lobular pattern. This variant should not be mistaken for mixed NST and lobular carcinoma.

At least 90% of the tumour should exhibit 1 or more of the above patterns to be classified as invasive lobular carcinoma.

The majority of invasive lobular carcinomas typically show no E-cadherin, beta-catenin and p120 membrane reactivity. However, 15% of cases express E-cadherin and interpretation is not without pitfalls and limitations.^{1,97} Positive staining for E-cadherin should not, therefore, be used to re-classify a tumour as NST that shows typical invasive lobular carcinoma features on H&E examination. E-cadherin positivity does not of itself indicate that the lesion is 'ductal', just as membrane negativity alone does not indicate a lobular lesion.

Figure 40: Classical invasive lobular carcinoma.



7.2.3 Tubular carcinoma

Tubular carcinoma (Figures 41a–e) is composed of round, ovoid or angulated single-layered tubules, haphazardly distributed in a cellular fibrous, fibroblastic or fibro-elastotic stroma.⁹⁸ The neoplastic cells are small, uniform and may show cytoplasmic apical snouts. Neoplastic tubules typically infiltrate fat peripherally. Tubular carcinoma may co-exist with flat epithelial atypia, low-grade DCIS and lobular neoplasia (the so-called low-grade neoplasia family). Specifically for this tumour type, nuclei should not show high-grade atypia and, by definition, a lesion with cells of pleomorphism score of 3 should not be defined as being of tubular type. Tubular carcinomas have an excellent prognosis.⁹⁹

At least 90% of the tumour should exhibit the classical growth pattern to be classified as tubular. However, if any co-existent carcinoma is solely of invasive cribriform type then the tumour should be typed as tubular if the tubular pattern forms over 50% of the lesion.

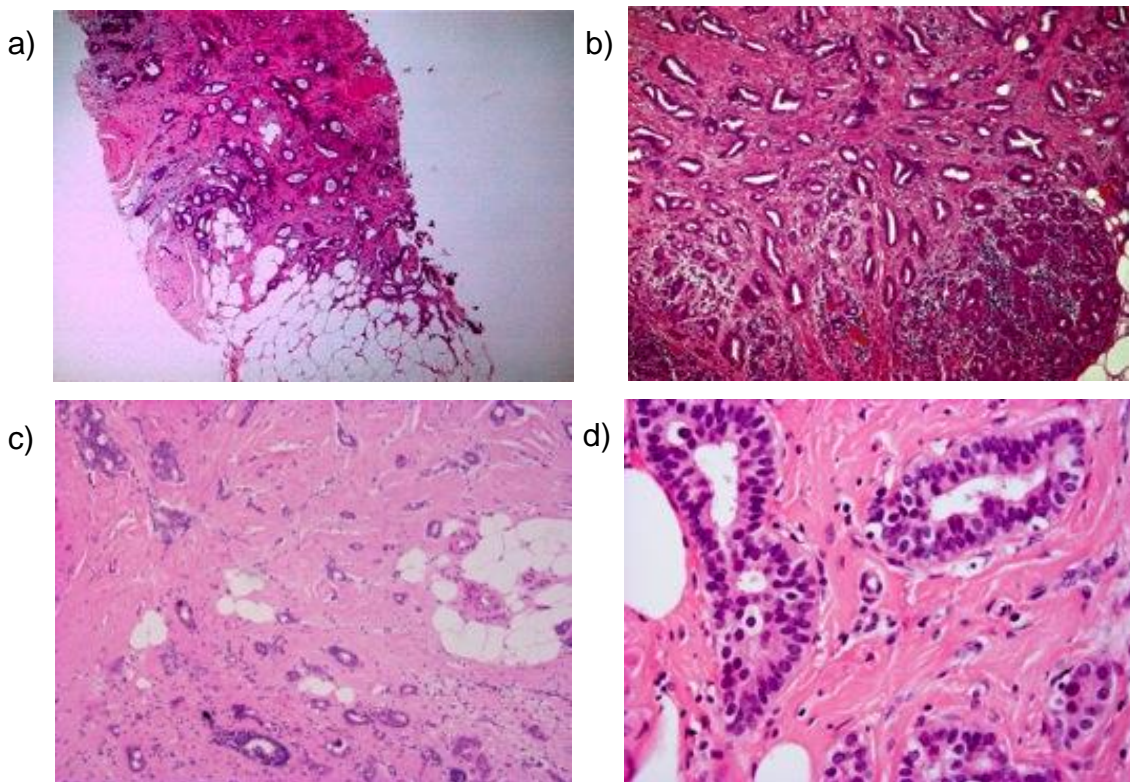
7.2.4 Invasive cribriform carcinoma

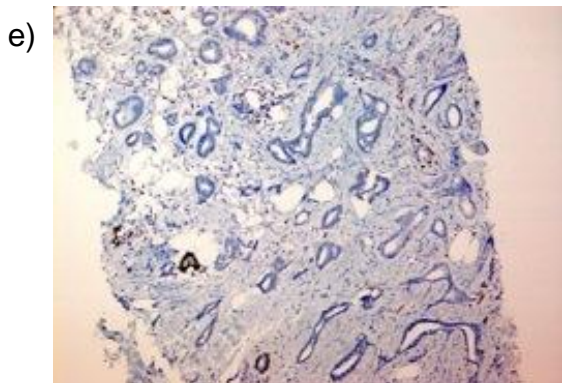
Invasive cribriform carcinoma is composed of masses of small to moderately sized regular cells, as seen in tubular carcinoma. The invasive islands, however, exhibit a cribriform

rather than a tubular appearance. Apical snouting is often present. Lumina may contain mucin with accompanying microcalcifications. As for tubular carcinoma, the nuclei should not show high-grade degrees of atypia. In a rare variant of invasive cribriform carcinoma, the stroma contains haemosiderin with osteoclast-like giant cells. Invasive cribriform carcinomas should also be distinguished from pure cribriform DCIS and from other ER negative carcinomas with a cribriform growth pattern such as adenoid cystic carcinoma.

More than 90% of the tumour should exhibit the cribriform appearance to be defined as invasive cribriform carcinoma, except in cases where the only co-existent pattern is tubular carcinoma when over 50% should be of cribriform appearance to be classified as invasive cribriform type. If a diagnosis of invasive cribriform carcinoma is preferred, the 'tubular' box should be completed on any relevant forms, and appropriate comment made under 'Comments/Additional Information'.

Figure 41: Examples of invasive tubular carcinoma (a–d). Lack of surrounding myoepithelial cells can be useful when the diagnosis is uncertain (e, p63 staining).

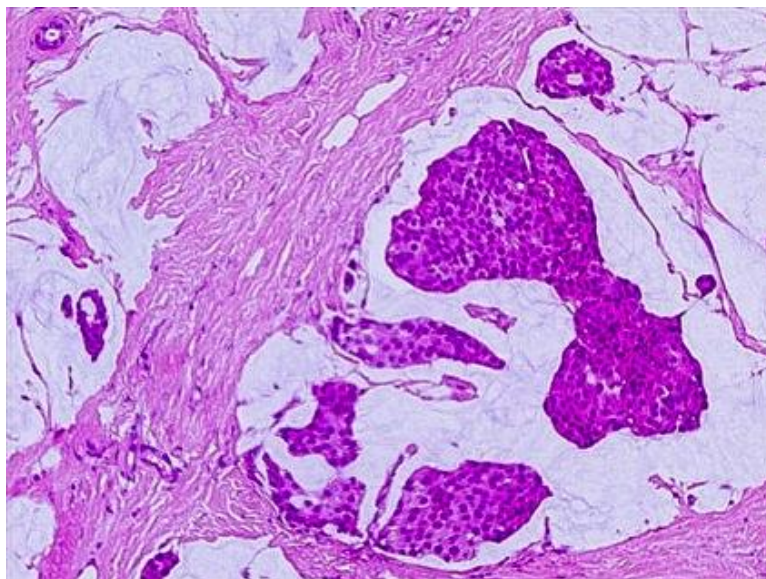




7.2.6 Mucinous carcinoma

Mucinous carcinoma is a type of invasive breast carcinoma characterised by clusters of tumour cells suspended in pools of extracellular mucin that is often partitioned by delicate fibrous septae containing capillary blood vessels (Figure 42). The tumour clusters vary in size and shape. Nuclear grade is typically low or intermediate, but a high nuclear grade may be identified. Variants of mucinous carcinoma have been described, including a hypocellular variant (type A) with large amount of extracellular mucin and a hypercellular variant (type B) with large epithelial 'clumps' or sheets that often show neuroendocrine differentiation. Occasionally pure mucinous carcinoma may have foci with a micropapillary or papillary pattern. Psammomatous calcifications may be present.

Figure 42: An example of a mucinous carcinoma.

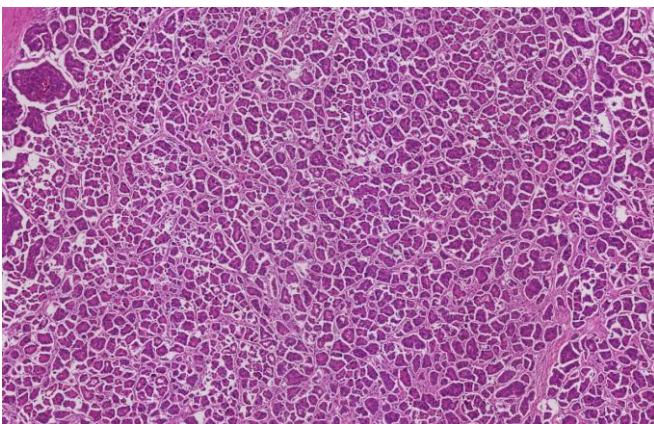


7.2.7 Invasive micropapillary carcinoma

Invasive micropapillary carcinoma is composed of aggregates of cuboidal to columnar neoplastic cells that are hollow and devoid of fibrovascular cores, lying within empty stromal spaces (Figure 43). These may give the impression of vascular spaces at low

power but are not lined by endothelial cells. The neoplastic cells display reverse polarity (an inside-out pattern) such that the apical pole of the cell faces outwards to the stromal space rather than inwardly to the central hollow or lumen. This can be demonstrated using epithelial membrane antigen (EMA) IHC (also seen with E-cadherin and HER2). This feature can help differentiate these tumours from other types of carcinomas with widespread artefacts due to poor fixation. Invasive micropapillary carcinomas are usually of histological grade 2 or 3 and have a propensity for lymphovascular invasion.¹⁰⁰ This pattern may be seen admixed with NST carcinoma and >90% of the tumour should have an invasive micropapillary pattern for classification as this subtype.

Figure 43: An example of invasive micropapillary carcinoma.



7.2.8 Invasive papillary carcinoma

This is a rare tumour characterised by papillae formed by malignant epithelial cells related to fibrovascular cores.¹⁰¹ The tumour has an infiltrative edge in contrast to the rounded contour observed in encapsulated papillary carcinoma (see section 6.3.3). This lesion should be distinguished from metastasis to the breast from, for example ovarian serous carcinoma, pulmonary papillary adenocarcinoma and thyroid papillary carcinoma.

This term should not be used for invasive carcinomas associated with an in situ or encapsulated papillary carcinoma, which should be classified according to the histology of the invasive foci alone.

Please see separate section 6.3.4 on papillary lesions for invasive solid papillary carcinoma.

7.2.9 Carcinoma with apocrine features

Carcinoma with apocrine features is a rare type of invasive breast carcinoma, characterised by large cells with abundant eosinophilic granular cytoplasm and enlarged nuclei with prominent nucleoli.⁴¹ The cells show distinct cell borders and the nuclei are

enlarged, round to oval, with marked or moderate atypia and prominent nucleoli. Apocrine carcinoma is typically androgen receptor and GCDFP15 positive, but its recognition should be based on the histological appearances rather than solely on the immunoprofile. Most apocrine carcinomas are ER and progesterone receptor negative; approximately 30% of cases are HER2 positive.^{102,103}

7.2.10 Metaplastic carcinoma

Metaplastic carcinoma (Figure 44) is a collective term for an extremely heterogeneous group of tumours. The malignant epithelium may have a spindle cell or squamous appearance and can show mesenchymal differentiation, e.g. with chondroid, osseous, or rarely rhabdomyoid, elements. These tumours may be entirely composed of metaplastic elements or may be a mixture of metaplastic elements and conventional invasive carcinoma (typically NST). Accompanying DCIS may also be present. Variants of metaplastic carcinoma include indolent lesions such as low-grade adenosquamous carcinoma and fibromatosis-like carcinoma (Figure 44a) through to aggressive lesions such as squamous cell carcinoma, spindle cell carcinoma including myoepithelial carcinoma (Figure 44b), as well as metaplastic carcinoma with mesenchymal differentiation (matrix-producing) subtypes. A wide range of markers is often required to identify an epithelial phenotype in these lesions (see Appendix G). It is recommended that a mention of all components is made, if multiple patterns are present, as there is some evidence that those tumours with more than 3 elements have a poorer prognosis.¹⁰⁴

Low-grade adenosquamous carcinoma comprises a mixture of well-formed glandular structures and small solid nests of squamous cells with a background population of spindle cells.¹⁰⁵ Fibromatosis-like metaplastic carcinoma is composed of bland spindle cells with minimal atypia and low mitotic activity (Figure 44a).^{106–108} Owing to the lack of cytological atypia and low mitotic activity, this tumour may be misdiagnosed as benign, but positive cytokeratin IHC in the spindled cells confirms the diagnosis (see Appendix G).¹⁰⁹ Both these metaplastic carcinoma types have a better prognosis than other variants of metaplastic carcinoma.

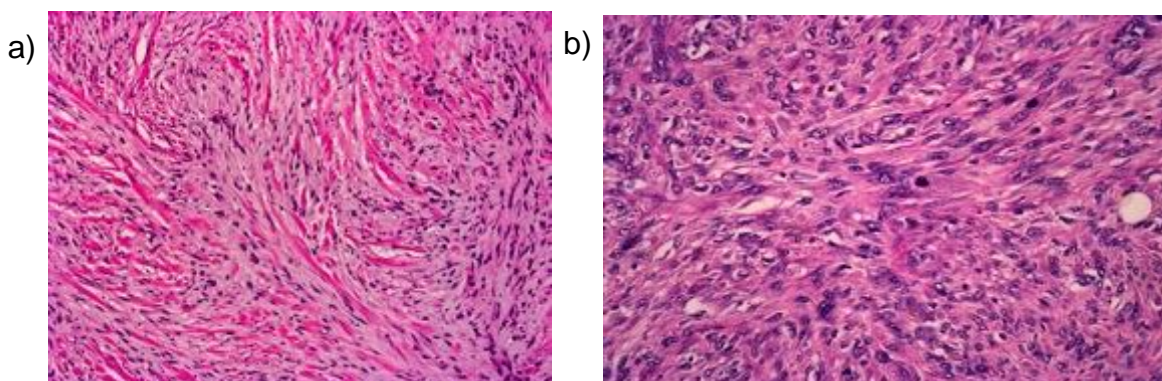
Metaplastic squamous cell carcinoma is usually identified as a cystic lesion lined by atypical squamous cells.¹¹⁰ The cells infiltrating the underlying stroma typically show a squamous and spindle cell morphology, with an accompanying inflammatory reaction. Metaplastic squamous cell carcinoma may be pure or admixed with conventional NST carcinoma as a mixed lesion. Care should be taken to distinguish primary breast lesions

from metastatic squamous carcinomas or from infiltration by primary squamous cell carcinoma of the skin.

Spindle cell carcinoma shows a greater degree of cytological atypia and more conspicuous mitotic frequency than seen in fibromatosis-like metaplastic carcinoma and has a more aggressive behaviour.¹¹¹ Areas of conventional NST carcinoma, foci of DCIS and squamous differentiation may be identified. A peripheral inflammatory infiltrate is frequently present. Myoepithelial carcinoma is included in this category.

Metaplastic carcinoma with mesenchymal differentiation (matrix-producing metaplastic carcinoma) is composed of mesenchymal elements, e.g. osteoid and/or chondroid areas, typically along with areas of recognisable carcinoma (NST).¹¹² The mesenchymal elements show varying degrees of differentiation and may appear frankly sarcomatous. Thorough sampling may be required to demonstrate the more overtly carcinomatous component. In rare cases carcinomatous elements cannot be identified and a wide range of cytokeratin IHC markers facilitates the diagnosis.

Figure 44: Examples of metaplastic spindle cell carcinoma of low-grade fibromatosis-like type (a) and high-grade metaplastic breast carcinoma type (b).



7.2.11 Rare types of breast carcinoma

Many other rare types of breast carcinoma exist. Some of these lesions resemble metastatic tumours and some mimic benign entities. These entities include the following.

- Salivary gland-like tumours, which comprise a spectrum of carcinomas with close resemblance to the salivary gland counterparts but arising as primary breast lesions.¹¹³ These include adenoid cystic carcinoma, acinic cell carcinoma, mucoepidermoid carcinoma and polymorphous carcinoma. These tumours are often bland-looking and have triple negative phenotype, which can be helpful in diagnosis.
- The most common salivary-like breast tumour is adenoid cystic carcinoma, which is formed from neoplastic cells arranged in cribriform, tubular and solid islands

composed of cells with epithelial and myoepithelial differentiation. Pseudo-luminal spaces filled with stromal matrix (hyaline globules) and true lumina with mucin are seen. The dual population can be demonstrated with IHC for diagnosis and negative ER reactivity is also helpful, as this is a 'triple negative' breast carcinoma.¹¹⁴ Most adenoid cystic carcinomas harbour a *MYB-NFIB* fusion gene. The classical type of adenoid cystic carcinoma is the most common but a solid-basaloid and a rare form with high-grade transformation are also recognised.

- Secretory carcinoma is a rare type of breast carcinoma characterised by relatively bland tumour cells, with intracytoplasmic vacuoles and extracellular secretions, arranged in a variable and often heterogeneous architecture. These lesions are most commonly triple negative, or weakly ER-positive, with strong expression of S100 protein. Secretory carcinoma is associated with a specific molecular alteration in the form of an *ETV6-NTRK3* fusion gene.¹¹⁵
- Mucinous cystadenocarcinoma is a very rare breast carcinoma characterised by a complex cystic morphology with spaces lined by atypical columnar-shaped mucin-secreting cells, similar to ovarian and pancreaticobiliary mucinous cystadenocarcinoma.
- Tall cell carcinoma with reversed polarity is another rare tumour type characterised by variable morphology but with nuclear features similar to that of the tall cell variant of thyroid papillary carcinoma. This has a predominantly solid papillary pattern with an absence of peripheral myoepithelial cells, but the columnar epithelial cells show a reversed nuclear polarity (nuclei located towards the luminal surface) and mutation of the *IDH2* gene.¹¹⁶
- Neuroendocrine tumour of the breast is composed of cellular solid nests and trabeculae of, typically moderately sized, cells with neuroendocrine features (either polygonal with granular cytoplasm, plasmacytoid or spindled etc).¹¹⁷ These should be distinguished from metastatic carcinoid tumour, which may be assisted if DCIS is present and by the typically strong uniform ER expression in these non-high-grade tumours.
- Neuroendocrine carcinoma is a very rare invasive carcinoma with high-grade morphology and neuroendocrine features.¹¹⁷ This is more commonly of small cell type than large cell pattern and mimics pulmonary small cell carcinoma. Associated conventional invasive or in situ breast carcinoma may be present (and helpful for

diagnosis) and these lesions can be ER-positive in around 50% of cases. Diffuse uniform reactivity for neuroendocrine markers is seen.

7.2.12 Other rare malignant tumours in the breast

Some rare tumours can be identified in the breast and these need to be distinguished from mammary carcinomas, as the management can be different. Such lesions include melanoma, lymphoma, sarcomas (primary or metastatic) and carcinomas metastatic to the breast. Pathologists should have a low threshold for requesting IHC if the morphology of the tumour is not typical of breast carcinoma or shows features suggesting another malignancy. Additional features, such as pigment or a prominent vasoformative architecture should be sought. The patient's clinical history should be clarified to determine if there is any known previous extramammary tumour. IHC is often essential to confirm the diagnosis (see Appendix G).

Pathologists should be aware that some immunohistochemical markers are expressed in more than 1 tumour type (e.g. SOX10 is expressed in melanoma and in triple negative breast carcinomas; CK7 is not specific to mammary carcinomas; CD138 can be expressed in plasma cell tumours and in mammary carcinomas. CD34 can be positive in vascular tumours as well as in the stroma of phyllodes tumours. ER is expressed in breast carcinoma and in carcinomas of gynaecological origin, as well as at a low level in a myriad of other tumours. In essence, a panel of markers should generally be used as none is 100% sensitive or specific.

Making a diagnosis of 1 of these rare tumours in a non-operative biopsy is very likely to trigger a different management to a primary invasive breast carcinoma and will be based on the nature of the lesion, whether it is primary or metastatic and the tumour type (lymphoma, melanoma or sarcoma). Such management will include referral to the relevant MDT.

Breast implant-associated anaplastic large cell lymphoma

BIA-ALCL is a rare complication associated largely with textured implants.¹⁸ It is a non-Hodgkin lymphoma characterised by the presence of a monoclonal population of large anaplastic cells that are uniformly CD30-positive, ALK-negative and variably express T cell markers and EMA.

It frequently presents as a late onset accumulation of seroma fluid between the implant and fibrous capsule in women, with a mean time to onset of 8–10 years post-implant. The neoplastic cells comprise medium to large, atypical cells with abundant eosinophilic

cytoplasm, with irregular nuclei and prominent nucleoli. The neoplastic cells are strongly positive for CD30, with 43–90% of cases also positive for EMA and all are ALK-negative. However, CD30 expression needs to be interpreted with care as this has been detected on activated T and B cells, NK cells, monocytes and lymphocytes. Thus, detection of CD30 expression alone is insufficient to make a diagnosis and this expression must be seen in a cell population with the characteristic cytological features of ALCL.

Diagnosis is usually made on examination of cytology fluid. We recommend preparations of May Grunwald-Giemsa, Papanicolaou or H&E-stained smears (according to local preference) with additional material made into cytoblocks. The primary analysis will be morphological. Samples that are acellular or composed entirely of inflammatory cells (neutrophils and 'bland' macrophages) can be reported as negative without further IHC. Samples containing 'atypical' macrophages and/or large atypical lymphoid blasts should have CD30 and CD68/CD163 assessment undertaken. If these atypical cells are CD30 positive and CD68 negative, the remaining panel for ALCL should be requested. If CD30 is negative and CD68/CD163 are positive this confirms 'atypical' macrophages, hence no ALCL panel is required. Please refer to Jones *et al.*, 2019.¹⁸ It is a requirement that all cases of BIA-ALCL in the UK are reported to the Medicines and Healthcare products Regulatory Agency (MHRA).

8 Core data items

8.1 Basic data items

8.1.1 Side

Indicate left or right breast. For specimens from both sides, or from different sites within 1 breast, a separate form should be completed for each.

8.1.2 Pathologist

The name of the reporting pathologist(s) should be recorded. In breast-screening-related cases, the consultant histopathologist must be registered at the breast screening office, otherwise their name will not be recognised by the computer.

8.1.3 Date

Record the date of surgery, date of receipt by laboratory and date of authorisation.

8.1.4 Specimen radiograph seen

Indicate if you have seen a specimen radiograph.

8.1.5 Mammographic abnormality present

Determine whether you are satisfied that the mammographic abnormality is present in the specimen. This may necessitate consultation with the radiologist responsible for examining the specimen radiograph.

8.1.6 Histological calcification

If relevant to the case, use this box to indicate if calcification observed radiologically was seen on histological sections and, if so, whether it is present in benign or malignant changes, or both. It is worth remembering that breast calcification may be due to calcium oxalate salts (Weddellite), which can be detected in histological sections using polarised light.

8.1.7 Specimen type

- Therapeutic wide local excision (wire-guided or palpable).
- Excision biopsy.
- Diagnostic localisation specimen.
- Segmental excision (to include wedge excisions, partial mastectomy and re-excision specimens for clearance of margins).
- Mastectomy (to include completion, risk-reducing, skin-sparing).
- Subcutaneous mastectomy.
- Re-excision specimens.
- Further margins (including cavity shaves/bed biopsies).
- Duct excision specimens, to include microdochectomy/microductectomy/Hadfield's procedure/total duct excision.
- Sentinel lymph node.
- Axillary node sample.
- Axillary lymph node clearance (level I, II or III).
- VAE.

8.1.8 Specimen weight

Record the weight of all surgical excision specimens, including shave and re-excision specimens. Weight is more reproducible than 3-dimensional measurement to determine

volume, even taking into account the different densities of fat and fibrous tissue, which vary in proportion in breast specimens. Specimen weight is also used as the means of determining the likely cosmetic disadvantage to women undergoing benign biopsy in the NHSBSP.

[Level of evidence – GPP.]

8.1.9 Benign/malignant lesion present

Tick the appropriate 'Yes' box if any benign or malignant lesion is present and 'No' if none is identified. Both benign and malignant may be ticked as 'Yes'.

8.2 Tumour classification and prognostic factors

8.2.1 Tumour size

The accurate measurement of tumour size is important as it is a prognostic factor, a component of prognostic indices and the T stage. Accurate identification of the tumour extent is also necessary to assess resection margins. Analysis from the NHSBSP EQA scheme shows poor concordance on tumour size, not explicable by slide-to-slide variation. As such poor concordance is on ready-prepared slides, the potential to arrive at an inaccurate size measurement when one takes into account the additional difficulties of specimen dissection must be even greater. What follows, therefore, are some practical suggestions for measuring tumour size accurately.

Invasive tumour size

This section should refer to the maximum dimension of the invasive tumour (see Figure 45). The maximum dimension of any invasive tumour should be measured in the fresh and/or fixed state macroscopically. In the case of ovoid tumours, care should be taken that the largest dimension is measured and blocked, bearing in mind that this may not be the plane initially incised, or precisely in any one of the medial/lateral, superior/inferior or deep (posterior)/superficial (anterior) directions. If a specimen radiograph is available, then the plane of maximum dimension should be assessed before slicing. For large, circumscribed tumours, the macroscopic measurement (in mm) may be sufficiently accurate, but for diffuse tumours it may be more problematic to define the precise borders of the tumour and microscopic size should be recorded.

Tumour size should be recorded in millimetres and the invasive tumour size entered in the field 'maximum dimension (invasive component)' on the reporting form. Satellite lesions should not be included in the measurement of the maximum invasive tumour dimension,

nor should foci of lymphovascular invasion or epithelial displacement/seeding as a result of prior needling procedure. On occasions, it may be difficult to be certain whether foci of invasive carcinoma close to each other within a section represent the main mass in continuity but out of the plane of the histological section or a satellite focus separate from the main mass. Helpful features to make that assessment include the presence of normal breast parenchymal structures between the 2 deposits and the distance between the foci. It is impossible to define a distance between the foci that can be used to decide whether one is a satellite deposit from another. However, if the foci are 5 mm or more apart the chances of the deposits representing 1 tumour appearing as separate foci due to plane of slicing are low.

Microscopic measurement of tumour size is considered the 'gold standard'. A pragmatic approach should be taken, for example if tumour is seen in several pieces of tissue, and common sense should be applied when definitive size measurement cannot be given. If the invasive tumour has been completely removed by the core, VAB or diagnostic excision, the pathologist should review the relevant previous specimen and provide an estimate of invasive carcinoma size from that. Review of previous specimens to estimate invasive tumour size is also necessary if a small focus of invasive carcinoma was present in a prior specimen but no further invasive carcinoma, only additional DCIS, is seen in the therapeutic excision. The estimate of the invasive tumour size from a previous diagnostic tissue sample is likely to be inaccurate; it should be noted, however, that the carcinoma in these instances of removal by core or VAB is likely to be small (certainly <10 mm). In rare circumstances where tumour size cannot be assessed either microscopically or macroscopically, imaging size (MRI, ultrasound or mammographic, in that order of accuracy) can be used as the best available record of true tumour size. Finally (and least accurately), clinical size can be used.

Figure 45a: How to measure invasive and whole tumour sizes in various scenarios. In e, the satellite focus of invasive tumour is not included in the measurement. In f, the best estimate of the total size of the invasive component is given. Please note that d and e illustrate examples of multiple invasive foci where the invasive foci are 5 mm or more distant (see also sub-section ‘Disease extent’, later in this section).

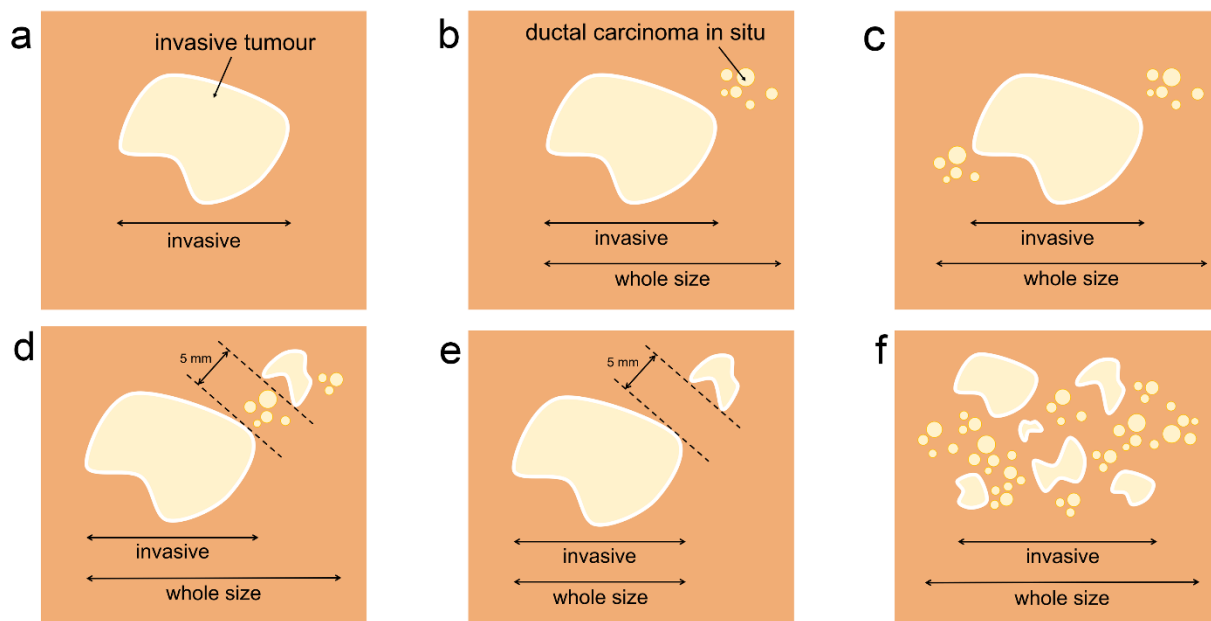
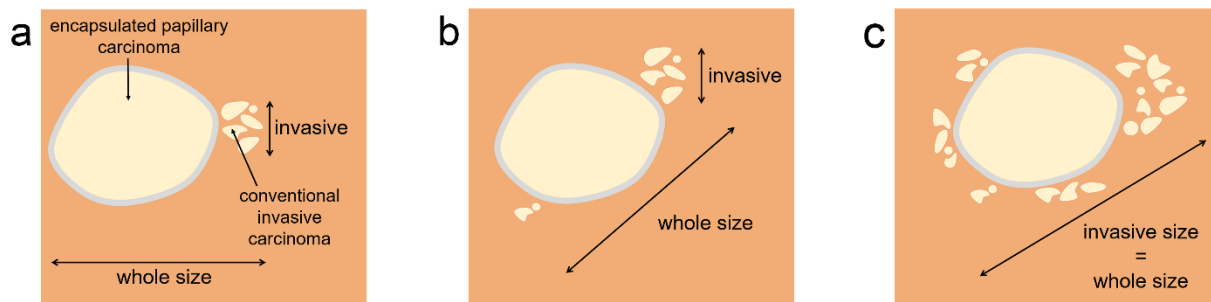


Figure 45b: How to measure invasive and whole tumour sizes in cases of encapsulated papillary carcinoma. In b, the size of the largest invasive focus is used as the invasive measurement. In c, where encapsulated papillary carcinoma is present in the centre of widespread conventional invasion, the invasive size measurement includes the entire extent of conventional invasion.



If there is a discrepancy between the macroscopic size and the microscopic size, the latter should be recorded as long as the true maximum dimension has been included in the slides. For example, an ovoid tumour 11 x 8 x 8 mm may be underestimated histologically as 8 mm, if the plane of block selection is through the centre rather than the long axis. Care should also be taken if the specimen is sampled as serial slices and the long axis of the tumour is perpendicular to the histological sections processed. Correlation between macroscopic size and imaging size is helpful. Similarly, when tumour is seen in multiple tissue slices, correlation with imaging size may be helpful to avoid overestimation of the

tumour size, as tissue slice thickness and the involvement of the 'end' slices by the tumour may be variable.

To assist accurate size measurement, a simple option is to dot the periphery of the tumour on the slide under the microscope (taking care to include the most peripheral cells or the furthest points of any stellate spurs of tumour protruding into the parenchyma) with a marker pen (Figure 46) and then measure the greatest distance between the points with a ruler or a dome magnifier with measuring reticule (Figure 47) applied directly over the histological slide. Measurement of histological size from the tissue sections can also be made using the Vernier stage micrometer.

It is anticipated that, with greater use of digital pathology systems, tumour size measurement will become easier and more accurate, as it will allow digital measurement of linear distance between 2 points.

Tumour size measurement following 'removal at biopsy' or post-neoadjuvant therapy

- Primary chemotherapy or prior core biopsy, or previous diagnostic excision biopsy, may result in partial tumour removal or complete ablation. If the invasive tumour has been completely removed by the core, VAB or diagnostic excision, the pathologist should review the relevant previous specimen and provide an estimate of invasive carcinoma size from that.
- Review of previous specimens to estimate invasive tumour size is also necessary, if a small focus of invasive carcinoma was present in a prior specimen but no further invasive carcinoma, only additional DCIS, is seen in the therapeutic excision.
- The estimate of the invasive tumour size from a previous diagnostic tissue sample is likely to be inaccurate; it should be noted, however, that the carcinoma in these instances of removal by core or VAB is likely to be small (certainly <10 mm).
- If therapeutic samples are sent in more than 1 portion, it can be difficult to measure the largest extent of the whole lesion and a degree of pragmatism is required. If tumour is present in several pieces of tissue, the maximum dimension in each should be added to give an estimated total size.
- Discussion with the radiologist and correlation with MRI, ultrasound and mammographic features (in that order of accuracy) should be undertaken. If there is (residual) DCIS in a therapeutic excision, but the invasive carcinoma has been

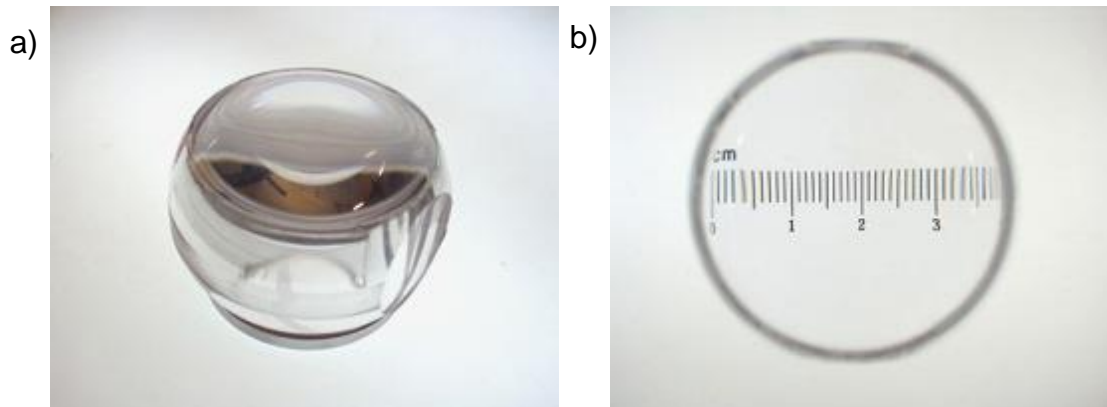
removed by previous sampling, it should be noted that radiological assessment of size of invasive focus may be impossible.

[Level of evidence – A. Invasive tumour size is a recognised important prognostic factor which is used in treatment planning, for staging purposes (TNM) and as a quality target in the NHSBSP. Accurate size measurement is expected.]

Figure 46: Marking the microscope slide can aid size measurement.

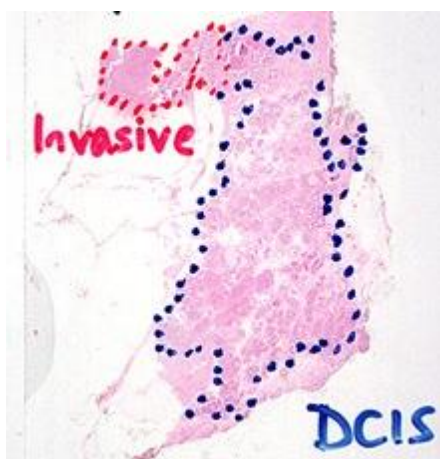

Figure 47: A simple lens measuring device can aid size measurement.



Whole tumour size – invasive tumour and surrounding DCIS/pleomorphic LCIS

The largest dimension of the whole tumour to include the invasive and in situ (DCIS or pleomorphic LCIS, but not classical LCIS) should be included in this section (see Figure 45). The term extensive intraductal component is no longer in use; this information is captured in the whole tumour size measurement.

Both the invasive tumour and the whole tumour size, including the in situ carcinoma (DCIS or pleomorphic LCIS) should be measured using the principles described above (and see Figure 45). The measurement of DCIS associated with invasive carcinoma should be

recorded in the whole tumour size field on the reporting form, including tumours which are predominantly composed of DCIS but have multiple foci of invasion.

If a tumour is insufficiently delineated to be measured accurately, a comment should be made in the 'comments/additional information' field on the reporting form.

[Level of evidence – B. Whole tumour size is used in treatment planning. Accurate size measurement is expected.]

In situ carcinoma size

This section should be completed for pure DCIS or pleomorphic LCIS where no invasive disease is seen. Classical LCIS may be extensive and/or multifocal and measurement unreliable, unnecessary and unhelpful. Pleomorphic LCIS, however, has a high incidence of associated ipsilateral invasive carcinoma and is reportedly less likely to be multifocal/bilateral, i.e. behaves more like DCIS. Pleomorphic LCIS should, therefore, be measured as for DCIS and the resection margin clearances also provided. The clinical value of size measurement of the high-risk florid LCIS is unclear.

Particular care should be taken in the measurement of DCIS; in 2-dimensional slides the total size of the in situ change may be underestimated due to the branching structure of normal breast duct territories. Of special note is the extension of DCIS into the major ducts running towards the nipple.

The measurement of the size of pure DCIS lesions (or pleomorphic LCIS) should be recorded on the reporting form in the field under non-invasive tumour 'SIZE (ductal only)', not in the whole tumour size field under invasive carcinoma.

[Level of evidence – A. DCIS size is a recognised predictive factor for local recurrence which is used in treatment planning. Accurate size measurement is expected.]

Disease extent

The field for disease extent on the form have been a source of confusion in the past due to debates about the definition of multicentric or multifocal disease. The field is now given as localised or multiple invasive foci. The field is present to record the presence or absence of multiple foci of invasive tumour within the specimen, clearly separate from each other and not connected by associated DCIS.

It is not intended that a tumour with multiple areas of invasion within extensive DCIS be classified as multiple (see Figure 45f).

It should be noted that DCIS is almost always a unifocal disease, although it may be extensive, but may not appear so due to the complex nature of duct systems and 2-dimensional histological examination (see section 6.1 on DCIS).

The designation of multiple foci should be reserved for multiple separate areas of invasive tumour. As noted above (see tumour size section) it can sometimes be difficult to determine whether 2 adjacent foci represent satellite foci or 1 lesion mimicking this process due to plane of sectioning. A pragmatic approach is required; the presence of intervening normal tissue and increasing distance between foci are features that indicate that these are more likely to be multiple foci than a localised process. A distance of 5 mm or greater is often used to define a separate focus (see Figures 37d and e).

Multiple synchronous primary tumours of different types should be categorised as multiple.

[Level of evidence – B. Tumour extent and presence of multiple invasive foci has implications for treatment planning. Accurate assessment is expected.]

8.2.2 Histological grade

Histological grading provides powerful prognostic information (see Appendix I).^{81,118} It requires some commitment and strict adherence to the accepted protocol. The method used is that described originally by Elston and Ellis (Nottingham grade) and involves the assessment of 3 components of tumour morphology: tubule/acinar/glandular formation, nuclear atypia/pleomorphism and frequency of mitoses. Each is scored from 1 to 3 (see Appendix I).⁸¹ Adding the scores gives the overall histological grade, as shown below. All invasive breast carcinomas should have histological grade assessed and reported.¹¹⁹

Some degree of variation in appearance may occur from 1 part of a tumour to another; this is particularly true of tumours of mixed type. Assessment of tubular differentiation is made on the overall tumour and so account is taken of any variation. Nuclear appearances (pleomorphism score) and mitotic count should be assessed in the 'worst' area of the tumour (often the periphery).

For assessment of grade in a mixed tumour, all components should be considered (for example regarding tubule/acinar formation), with the final grade based on the higher-grade component. If a mixed tumour shows a morphologically different component or a higher-grade component that was not identified in the preoperative biopsy, repeating receptor assays is recommended.

Do not expect equal numbers of cancers to fall in each grade category; ratios for grades 1, 2 and 3 are approximately 2:3:5 in symptomatic breast cancer and 3:5:2 in screen-detected breast cancer.⁸¹ If audit of grade distribution shows a significant difference from that expected, fixation and grading protocols should be carefully reviewed.

Tubule/acinar formation

All parts of the tumour are scanned, and the proportion occupied by tumour islands showing clear acinar or gland formation or defined tubular structures with a central luminal space is assessed semi-quantitatively. This assessment is generally carried out during the initial low power scan of the tumour sections.

Score

1. >75% of tumour forming tubular structures.
2. 10–75% of tumour.
3. <10% of tumour.

In the assessment of tubule formation, only structures in which there are clearly defined central luminal spaces, surrounded by polarised tumour cells, should be counted. This does, however, include larger islands of tumour with central gland formation, as may be seen in mucinous carcinoma. In the assessment of tubule formation, any luminal spaces within the tumour islands in invasive micropapillary carcinoma should be included, however the clear spaces around the islands should not.

Nuclear atypia/pleomorphism

Individual pathologists differ markedly in their approach to nuclear grading; it should be noted that breast specialists tend to allocate higher nuclear grades than non-specialists.¹²⁰ Very few cancers possess the bland nuclei warranting an atypia/pleomorphism score of 1, and obvious atypia/pleomorphism should attract a score of 3. The minimum proportion of tumour nuclei which should show marked nuclear atypia/pleomorphism before a score of 3 is allocated has not been defined, but the finding of an occasional enlarged or bizarre nucleus should not be used to give a score of 3.

Score¹²¹

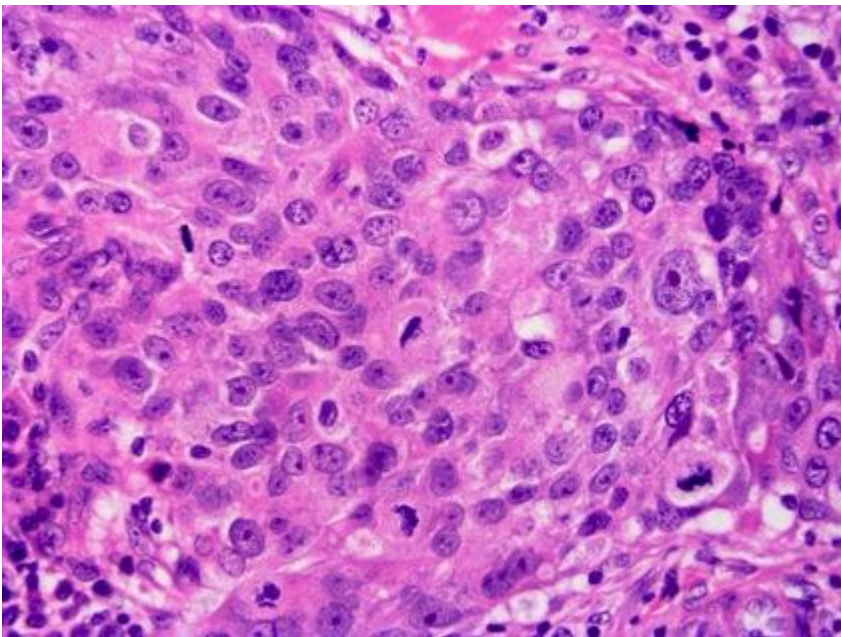
1. Nuclei are small with regular outlines and uniform nuclear chromatin and are typically up to 2 times the size of an erythrocyte in diameter or less than 1.5 times the size of normal breast epithelial cells.

2. Cells often have open vesicular nuclei, visible nucleoli and moderate variability in both size and shape. The nuclei are larger than those seen in grade 1 tumour nuclei and are between 2 and 2.5 times the size of an erythrocyte in diameter and between 1.5 and 2 times the size of normal breast epithelial cells.
3. Nuclei are vesicular, often with prominent nucleoli, exhibiting marked variation in size and shape, occasionally with very large and bizarre forms. Nuclei are large and greater than 2.5 times the size of erythrocytes or greater than 2 times the diameter of normal breast epithelial cell.

Mitoses

Accurate mitosis counting requires high-quality specimen fixation (Figure 48), as well as tumour blocks of optimal thickness (3–4 mm) for good tissue processing. Care must be taken to not interpret apoptosis as mitotic figures and only true mitotic figures should be counted.¹²²

Figure 48: Prompt fixation aids mitotic figure identification.



Scoring mitoses

The mitosis score depends on the number of mitoses per 10 high power fields. The size of high power fields is very variable, so it is necessary to standardise the mitotic count using Table 6. The field diameter of the microscope should be measured using the stage graticule or a Vernier scale and the scoring categories should be read from the corresponding line of Table 6 and Figure 49. Field diameter is a function of the objective lens and the eyepiece, so if either of these is changed this exercise must be repeated. The

field diameter can also be calculated simply by dividing field number by objective magnification; for example, if the eyepieces give field number 22 when using a x40 objective lens, the field diameter (in mm) is $22/40 = 0.55$ mm.

A low power scan of the whole tumour should be performed to identify the areas of highest mitotic activity, where a minimum of 10 high power fields should be counted. Proliferation is often highest at the periphery of the tumour.^{123,124} If the mitotic frequency score falls very close to a score cut point, further groups of 10 high power fields should be assessed to establish the correct (highest) score. If there is no evidence of heterogeneity, mitotic scoring should be carried out at a part of the tumour periphery chosen at random. Only fields with a representative tumour burden should be used. The low power scan of the tumour can be used to provide an assessment of the typical tumour to stromal ratio. Only definite mitotic figures (in any phase of the growth cycle) should be counted. Hyperchromatic nuclei and/or apoptotic nuclei should not be scored. Poor quality fixation can result in underscoring of mitotic frequency.

Table 6: Mitotic counts by X40 lens microscopic field diameter.

| | | Number of mitoses corresponding to | | |
|---------------------|-------------------------------|------------------------------------|---------|------------|
| Field diameter (mm) | Field area (mm ²) | Score 1 | Score 2 | Score 3 |
| 0.40 | 0.126 | up to 4 | 5 to 9 | 10 or more |
| 0.41 | 0.132 | up to 4 | 5 to 9 | 10 or more |
| 0.42 | 0.139 | up to 5 | 6 to 10 | 11 or more |
| 0.43 | 0.145 | up to 5 | 6 to 10 | 11 or more |
| 0.44 | 0.152 | up to 5 | 6 to 11 | 12 or more |
| 0.45 | 0.159 | up to 5 | 6 to 11 | 12 or more |
| 0.46 | 0.166 | up to 6 | 7 to 12 | 13 or more |
| 0.47 | 0.173 | up to 6 | 7 to 12 | 13 or more |
| 0.48 | 0.181 | up to 6 | 7 to 13 | 14 or more |
| 0.49 | 0.189 | up to 6 | 7 to 13 | 14 or more |
| 0.50 | 0.196 | up to 7 | 8 to 14 | 15 or more |

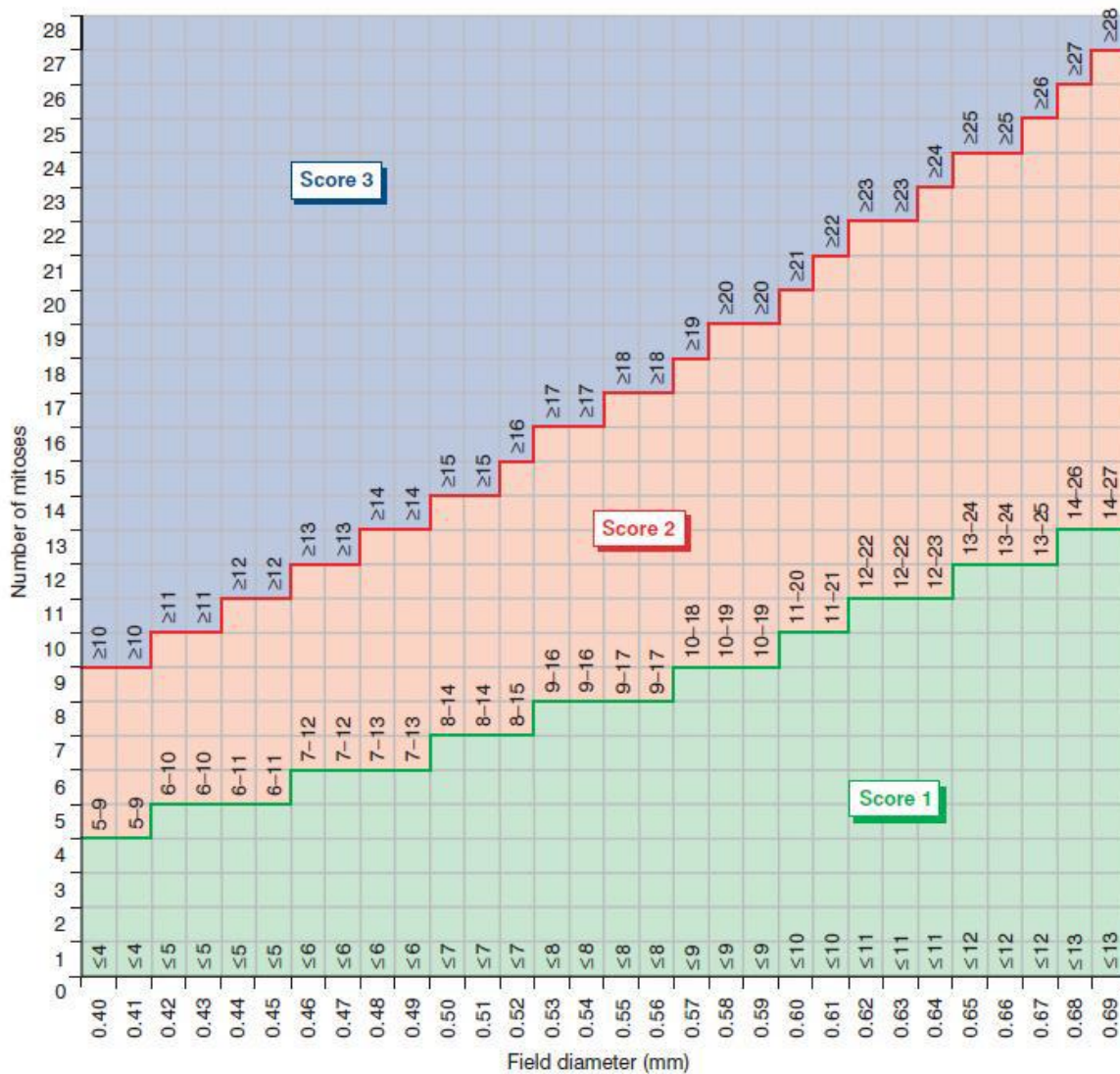
| | | | | |
|------|-------|----------|----------|------------|
| 0.51 | 0.204 | up to 7 | 8 to 14 | 15 or more |
| 0.52 | 0.212 | up to 7 | 8 to 15 | 16 or more |
| 0.53 | 0.221 | up to 8 | 9 to 16 | 17 or more |
| 0.54 | 0.229 | up to 8 | 9 to 16 | 17 or more |
| 0.55 | 0.238 | up to 8 | 9 to 17 | 18 or more |
| 0.56 | 0.246 | up to 8 | 9 to 17 | 18 or more |
| 0.57 | 0.255 | up to 9 | 10 to 18 | 19 or more |
| 0.58 | 0.264 | up to 9 | 10 to 19 | 20 or more |
| 0.59 | 0.273 | up to 9 | 10 to 19 | 20 or more |
| 0.60 | 0.283 | up to 10 | 11 to 20 | 21 or more |
| 0.61 | 0.292 | up to 10 | 11 to 21 | 22 or more |
| 0.62 | 0.302 | up to 11 | 12 to 22 | 23 or more |
| 0.63 | 0.312 | up to 11 | 12 to 22 | 23 or more |
| 0.64 | 0.322 | up to 11 | 12 to 23 | 24 or more |
| 0.65 | 0.332 | up to 12 | 13 to 24 | 25 or more |
| 0.66 | 0.342 | up to 12 | 13 to 24 | 25 or more |
| 0.67 | 0.353 | up to 12 | 13 to 25 | 26 or more |
| 0.68 | 0.363 | up to 13 | 14 to 26 | 27 or more |
| 0.69 | 0.374 | up to 13 | 14 to 27 | 28 or more |
| 0.70 | 0.385 | up to 13 | 14 to 27 | 28 or more |

As whole slide imaging (digital pathology) is being widely adopted, a standard area will replace high power field as the unit of measurement for counting mitotic figures.¹ The field of view of digital images depends not only on the magnification but also on the size of the viewing monitor/area used for counting. An alternative to Table 6, showing the number of mitoses corresponding to each score per standard area, is provided below (Table 7).

Table 7: Mitotic counts by standard areas (mm²)

| Standard area (mm ²) | Number of mitoses corresponding to | | |
|----------------------------------|------------------------------------|---------|------------|
| | Score 1 | Score 2 | Score 3 |
| 2 mm ² | up to 7 | 8–14 | 15 or more |
| 3 mm ² | up to 11 | 12–22 | 23 or more |
| 4 mm ² | up to 14 | 15–29 | 30 or more |

Figure 49: Mitotic count cut points for 10 high power fields by high power lens diameter.



Overall grade

The use of terms such as well differentiated or poorly differentiated in the absence of a numerical grade is inappropriate for invasive breast cancer. The scores for tubule

formation, nuclear pleomorphism and mitoses are added together and the overall grade assigned, as below:

Grade 1 = Score of 3, 4 or 5

Grade 2 = Score of 6 or 7

Grade 3 = Score of 8 or 9

Grading is not restricted to invasive carcinoma of NST but should be undertaken on all histological subtypes. There is significant variation in prognosis within certain subtypes by grade of lesion, e.g. lobular carcinoma, and grading provides additional information.¹¹⁹ It is recommended that a Nottingham grade should be provided for all invasive carcinomas, including adenoid cystic carcinomas and other rare subtypes.

'Not assessable' should be ticked if for any reason the grade cannot be determined, e.g. specimen poorly preserved or too small.

Grading systems other than that described above should not be used.

For audit and other purposes, it is mandatory to record individual components of grade.

[Level of evidence – A. Invasive tumour grade is a recognised important prognostic factor which is used in treatment planning. Accurate assessment is expected.]

Assessment of grade on other specimens

Histological grade should be assessed on core biopsies using the approach described above. This is of particular value if the patient has preoperative systemic treatment. There is moderate, about 70%, agreement of grade on core biopsy with the corresponding surgical specimen.^{125,126} Usually the histological grade in the surgical specimen is used in preference to the core grade for clinical management. However, if assessment of grade in the surgical specimen is compromised, for example by poor fixation or preoperative systemic treatment, it is reasonable to use the mitotic count score from the core biopsy. Another alternative is to assess the mitotic count in any nodal metastases if interpretation of grade is difficult in the primary carcinoma.

[Level of evidence – C. Histological grade as determined on the diagnostic needle core biopsy is widely used as a criterion when considering recommending neoadjuvant chemotherapy.]

8.2.3 Lymphovascular invasion

The presence of lymphovascular invasion (Figure 50) is an adverse feature that provides independent prognostic information about both risk of local recurrence and survival.^{127–129} It is, therefore, important to record whether or not it is present. Because it is difficult to distinguish between lymphatic and venous channels, findings should be categorised as ‘lymphovascular spaces’ rather than as specific channels. This is supported by evidence identifying that most tumour emboli are present in lymphatic channels.

It can be difficult to distinguish true lymphovascular invasion from shrinkage artefact; this is minimised by optimal tissue fixation and processing. A clear rim of endothelium should be present to diagnose lymphovascular space invasion (Figure 50). The presence of unequivocal tumour in lymphovascular spaces should be recorded; if there is doubt, but it is considered to be very likely, it should be recorded as possible. Only lymphovascular invasion identified in breast tissue associated with the primary breast carcinoma should be recorded. Lymphovascular invasion identified elsewhere, for example in axillary tissue, should be described but not recorded formally as lymphovascular invasion. Perineural invasion should not be recorded as lymphovascular invasion.

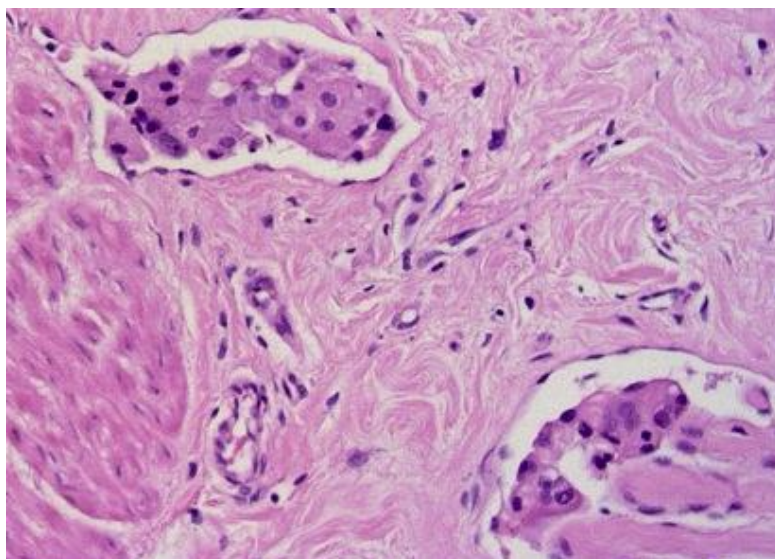
There are various features that may be helpful in trying to identify lymphovascular invasion and to recognise whether tumour cells are in definite lymphovascular spaces. These are:

- groups of tumour cells in spaces around the main tumour mass; ensure that any spaces are lined by endothelial cells and are not fat spaces (Figure 50)
- the presence of adjacent vascular channels that may be of varying sizes
- the presence within the space of erythrocytes and/or thrombus
- shrinkage artefact results in nests of cells having typically the shape of the space in which they lie; endothelial cells will not be seen.

The best method for assessing lymphovascular invasion is the use of good quality, optimally fixed and processed H&E-stained sections. Immunostaining for endothelial markers does not generally contribute further, but can be considered for difficult critical cases. Lymphatic endothelial specific immunohistochemical markers, such as D2-40, can assist in detection specifically of lymphatic vessel invasion.¹³⁰

[Level of evidence – B. Lymphovascular invasion status is a recognised important prognostic factor which is used in treatment planning. Accurate assessment is expected.]

Figure 50. An example of lymphovascular invasion.



8.2.4 Lymph node stage

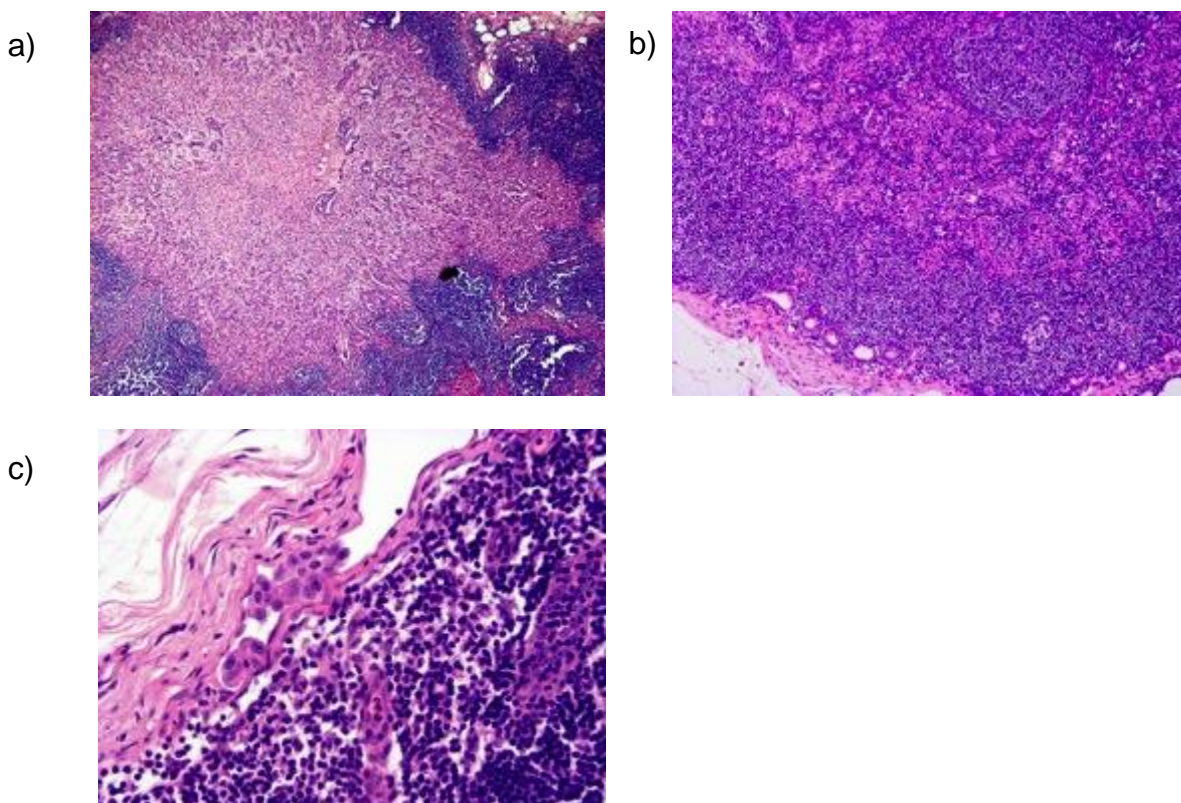
Lymph node stage is an important prognostic factor. All lymph nodes must be examined histologically, as noted in section 2. Data from axillary nodes must be recorded separately from nodes from other sites. Examination of levels is not routinely necessary. It may be performed if small groups of suspicious cells are identified, if initial sections do not achieve a full-face section, and to determine the maximum size of any metastatic deposits.

Histological reports should include:

- the total number of lymph nodes identified
- the number of lymph nodes involved with metastatic disease, both macro (Figures 51a and 51b) and micrometastases. Of note, nodes with isolated tumour cell clusters (Figure 51c) are not regarded as involved/positive for metastasis
- specific axillary levels and nodes, e.g. the apical node, may have been identified by the surgeon and can be recorded independently, but they should also be included in the total lymph node numbers
- in cases with only 1 involved node, the metastasis should be measured and designated as a macro- or micrometastasis
- if multiple nodes are positive with at least 1 of them a macrometastasis, the whole case is considered as macrometastatic disease. In such circumstances, the number of positive nodes should include nodes both micro- and macrometastasis but not nodes with only isolated tumour cell clusters

- the presence of extracapsular spread extending from an involved lymph node can be noted under 'Comments/additional information'. There is some evidence that this is a prognostic factor in those with node positive disease¹³¹
- significant extranodal/axillary soft tissue metastatic tumour deposits without obvious nodal structures are regarded as involved lymph nodes for the purposes of assessing the overall number of involved lymph nodes
- for integration into systems like the Nottingham Prognostic Index (NPI), a stratification system based on number of involved nodes is used: Stage 1 = Node negative; Stage 2 = 1–3 nodes positive; Stage 3 = 4 or more nodes positive.¹³² This includes both macro- and micrometastatic disease, but not isolated tumour cell clusters.

Figure 51: Examples of lymph node metastatic deposits; (a) and (b) are macrometastases, (c) an isolated tumour cell cluster.



Reporting and definitions of micrometastatic disease and isolated tumour cell clusters

The system outlined in Appendix F is adapted from the UICC/TNM 8 classification of malignant tumours.

- IHC may be helpful, if there are cells suspicious of carcinoma seen in the H&E section, but is not routinely necessary. If this is required, clone AE1/AE3 is recommended.¹⁹ Reactivity of dendritic reticulum cells and some lymphoid cells may lead to false positive results when using some cytokeratin antibodies and assessment must therefore be based on immunoreactivity and morphological correlation (see Appendix G).
- Micrometastasis is defined as 1 or more deposits of metastatic carcinoma within the lymph node, or the node capsule, that are more than 0.2 mm in size but none of which is larger than 2 mm in greatest dimension. Lymph nodes involved by micrometastases are regarded as positive.
- Cases with only isolated tumour cell clusters (ITCS) in regional lymph nodes are classified as node negative (pn0). ITCS are single tumour cells or small clusters of cells not more than 0.2 mm in greatest dimension (Figure 51c) or single tumour cells, or clusters of fewer than 200 cells in a single histological cross section. These may be detected by routine H&E, by IHC, or molecular methods but which may be verified on H&E stains. ITCS do not typically show evidence of metastatic activity (e.g. proliferation or stromal reaction).
- There are rare cases which may be difficult to categorise reproducibly at the border between micrometastasis and ITCS.^{133,134}
- Any lymph node involvement >0.2 mm but ≤2 mm in any of the 3 dimensions is categorised as a micrometastasis. The 0.2 mm size cut-off relates to the maximum diameter of the largest tumour cell cluster. There may be instances of nodal involvement with the largest cluster measuring <0.2 mm in diameter but containing >200 cells, and vice versa, i.e. clusters >0.2 mm in diameter with <200 cells. Size should be considered first and the cell count applied only if the largest cluster is <0.2 mm.¹²⁴
- If a patient has received neoadjuvant therapy, even very small metastases have prognostic significance. It is considered likely that micrometastases and/or ITCS in the setting of neoadjuvant therapy may represent larger metastases that have responded to neoadjuvant therapy resulting in residual tumour cells in an area of response.¹³⁵ It is, therefore, advised that any residual tumour cells identified in a lymph node examined after neoadjuvant treatment should be considered as positive.

- Lymph nodes previously containing tumour often show fibrosis and scarring post-neoadjuvant therapy. Care should be taken in the interpretation of lymph node fibrosis as areas of diffuse hyaline change or lymphocyte depletion may sometimes be seen in otherwise normal nodes. Small areas of fibrosis or fibroplasia, especially if not wedge-shaped and subcapsular or without other associated post-treatment changes, should not be regarded as representing response in a metastasis (unless carcinoma cells are still present). Response of nodal metastasis to neoadjuvant therapy may occasionally be seen as sheets of macrophages, sometimes with hemosiderin, i.e. similar changes to those seen in relation to the primary carcinoma.
- In addition to reporting the total number of nodes, the number involved and the size of the largest metastasis, the number of nodes that show fibrosis (with or without viable tumour) should also be reported as this may be used for determining radiotherapy extent (see section 8.2.6 and Figure 52f). Use of H&E levels and IHC is not routinely necessary in assessment of lymph nodes but may prove helpful in problematic cases, especially post-neoadjuvant therapy when interpretation may be difficult (see Appendix G).

[Level of evidence – A. Invasive tumour stage is a recognised important prognostic factor which is used in treatment planning, for formal staging purposes (TNM) and as a quality target in the NHSBSP. Accurate assessment is expected.]

8.2.5 Excision margins

Please refer to section 2 on specimen handling for more detail around specimen types and how to handle these specimens.

Assessment of adequacy of excision requires close correlation between the surgical excision procedure and pathological examination. In particular, it is essential that the pathologist is made aware of the depth of tissue excised and whether the surgeon has excised all the tissue from the subcutaneous to the pectoral fascia.

There remains controversy regarding the minimum width of uninvolved tissue that defines ‘complete’ excision, although narrower margins are now widely accepted as adequate compared to previously. There is local variation in definition of ‘complete excision’, and this is different for pure DCIS and invasive carcinoma in some centres. For this reason, it is recommended that the pathologist reports the measurement to all inked margins of DCIS and invasive carcinoma rather than quoting ‘complete’ excision in histology reports. Many employ statements such as ‘all (other) margins are >5 mm distant’ as a way around the

need to specify the distance of both DCIS and invasive carcinoma to all aspects of the specimen.

DCIS or invasive carcinoma found in cavity shaves or specific margin re-excision specimens should be added to the dimension of the main tumour if they are deemed to be in continuity; otherwise, it should be measured and stated to be a separate focus, indicating multiple invasive foci. In either instance, the distance from the carcinoma to the new external margin, i.e. the new clearance, should be measured and reported.

[Level of evidence – A. Tumour excision status is a recognised important prognostic factor relating to risk of local recurrence and is used for treatment planning. Accurate assessment is expected.]

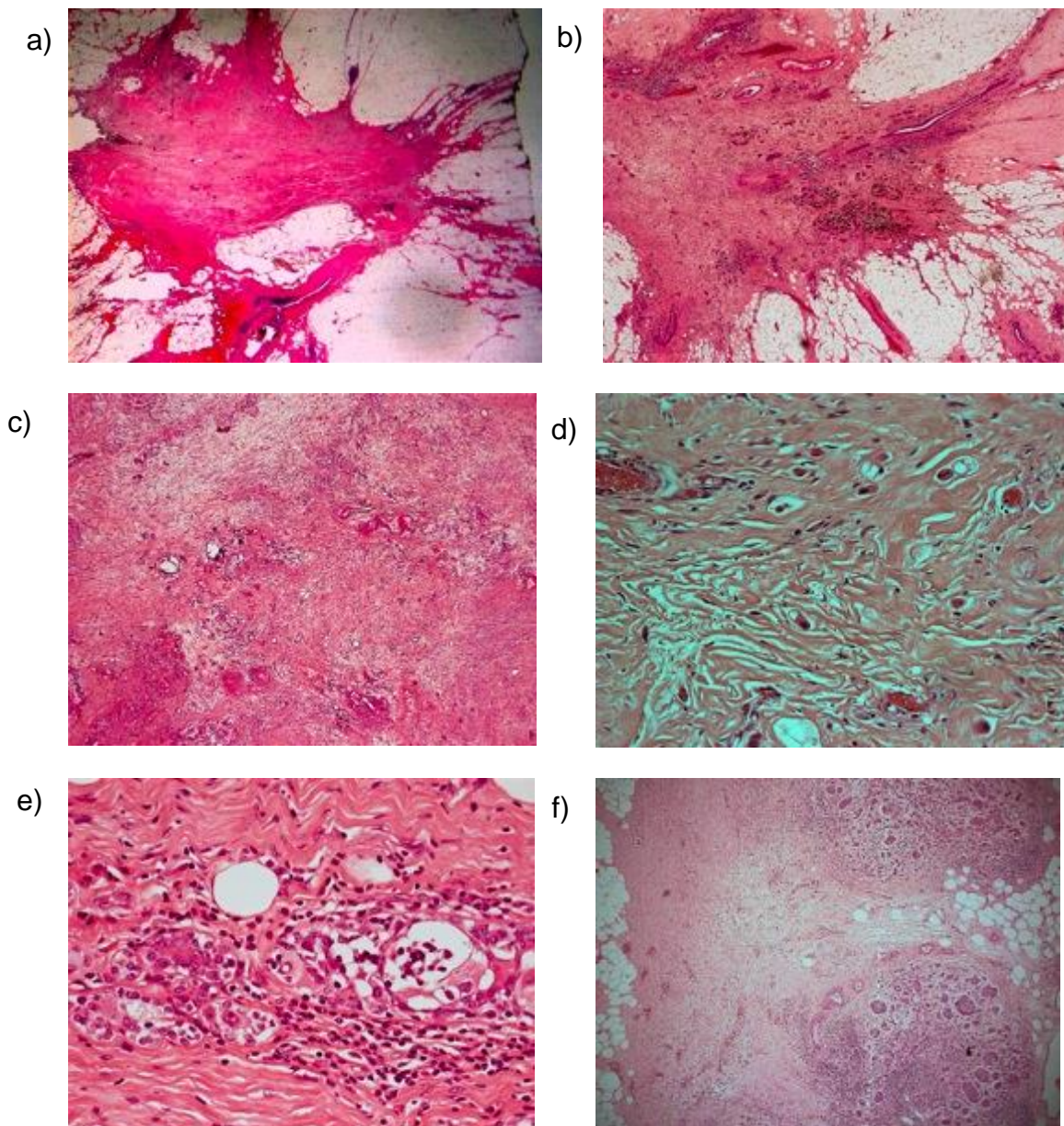
8.2.6 Assessment of treatment effects including post-neoadjuvant therapy

Some patients receive neoadjuvant therapy prior to surgery. This may be chemotherapy, with or without targeted therapy, or endocrine therapy. This permits an assessment of tumour responsiveness to the therapy and may result in tumour down-staging, i.e. a reduction in tumour size and/or nodal involvement.

Histological appearances

If there has been minimal or no response to neoadjuvant therapy, the protocol of histological examination of the surgical specimens is not significantly different to that of excised breast carcinomas from patients not receiving neoadjuvant therapy (Figures 52a–f). However, if there has been a good (or complete) pathological response to neoadjuvant therapy (more typical with chemotherapy than endocrine treatment), identification of the site of disease can be difficult, not only macroscopically but also microscopically and specimen handling and sampling is more complex.¹³⁶ This is histologically typically seen as an area of fibrosis, sometimes oedematous or myxoid, with a central nidus in which there is an absence of breast epithelial structures (Figures 52a–c).¹³⁷ Sometimes islands or sheets of foamy macrophages may be prominent and other chronic inflammatory cells seen in aggregates. Haemosiderin deposition may be present and areas of necrosis seen, but the latter is unusual (Figure 52b).

Figure 52: Examples of post-neoadjuvant chemotherapy changes (a–d) showing stellate fibrosis (a, b), dense fibrosis and elastosis with sparse tumour cells present (c). Tumour cells may be very sparse and difficult to identify (d). The normal epithelium may show reactive changes (e). Lymph nodes may show fibrosis (f) with or without residual tumour cells present.



Residual carcinoma may be clearly evident with routine H&E stains and cause no diagnostic difficulties. However, some lesions, particularly if there has been a significant response, may cause problems in microscopic assessment. Scattered residual invasive carcinoma may mimic macrophages, and vice versa, both in the breast tissue and in lymph nodes (Figure 52d). Conversely, invasive carcinoma cells may be larger, more pleomorphic and atypical after therapy. The architecture of the tumour may also appear to change and NST lesions may mimic invasive lobular carcinomas after primary chemotherapy treatment.

Notably, even when no residual invasive component can be identified, residual in situ carcinoma, typically DCIS, may be seen. However, benign breast epithelium may show chemotherapy changes in the form of enlargement of nuclei with prominent nucleoli and care should be taken not to over-diagnose DCIS in this setting (Figure 44e). DCIS is typically close, or within, the tumour bed of fibrosis and the atypical cells make up the majority of cells in the spaces. Chemotherapy changes are usually more widespread and discontinuous within the ducts or lobules. If the original DCIS/invasive carcinoma was HER2 positive, this marker can be helpful in difficult cases.

Historically different criteria have been applied for categorisation of a tumour as pCR (see below) including absence of invasive carcinoma or absence of invasive carcinoma and of DCIS. It is mandatory that reports clearly indicate what disease elements remain after neoadjuvant therapy, but it should be noted that residual DCIS alone with complete response of invasive carcinoma appears to confer an equivalent prognosis to eradication of both in situ and invasive elements.¹³⁸

Where no overt tumour is seen, but odd scattered cells with apparent nuclear atypia or whose nature is otherwise uncertain are present, a low threshold for immunohistochemical evaluation is recommended to confirm the nature of the cell type and to reveal low volume residual disease. Carcinoma cells retain cytokeratin expression post therapy, while macrophages will continue to express CD68. There is evidence that AE1/AE3 is preferable to other cytokeratin markers in the immunohistochemical examination of sentinel lymph nodes outside the setting of primary systemic therapy. However, dendritic reticulum and inflammatory cells (which may give positive reactivity with Cam5.2 and other pan-cytokeratin formulations) may be especially difficult to assess in a background of neoadjuvant chemotherapy changes.¹⁹ IHC may also assist the assessment of margin status in difficult cases of breast conserving surgery specimens, but is not mandatory.

Assessment of response to treatment

- pCR is currently recognised as the key prognostic measure with respect to subsequent patient outcome after neoadjuvant therapy. The historical definitions of pCR have varied. Some definitions focus on absence of any invasive component while others require complete effacement of all disease (DCIS, invasive, within lymphovascular channels and lymph nodes). It has been reported that disease-free survival is superior in patients with no residual invasive or in situ disease in either the breast or lymph nodes compared to patients with residual DCIS only.¹³⁹ However, the CTNeoBC pooled analysis of 12 major international neoadjuvant trials did not find a significant

difference in event-free survival or overall survival in patients with or without residual DCIS.¹³⁸ While pCR as defined as neither invasive nor in situ residual disease in either breast or lymph nodes may be the best discriminator of patients with a favourable outcome, this is not the globally applied definition, in which residual DCIS does not exclude classification as pCR.¹⁴⁰

- Histology reports should clearly indicate what disease elements remain after neoadjuvant therapy.
- Those patients with focal residual disease (i.e. partial response) fare better than those with gross invasive disease after neoadjuvant therapy but there is no globally agreed method for categorisation of partial/lesser degrees of response to neoadjuvant therapy. Several systems have been described.^{141–144}
- The residual cancer burden (RCB) score is increasingly being advocated as the method of choice in assessing tumour response to neoadjuvant chemotherapy. In several ongoing neoadjuvant chemotherapy clinical trials, the RCB is required as an endpoint; this is routinely reported in some UK units. The determination of the RCB includes an assessment of the residual tumour in 2 dimensions, the cellularity of the tumour and the number of lymph node metastases along with the size of the largest of these. A combination of these features gives the RCB score, which can be grouped into categories 0 to III, according to patient outcome. The algorithm for this, as well as examples of percentage cellularity and methodology, can be found on the [MD Anderson website's residual cancer burden calculator](#).¹⁴⁵ Studies have shown good reproducibility of RCB scores and groups.¹⁴⁶ However, the calculation of the RCB is not mandatory as the clinical utility of this, outside clinical trials, is yet to be determined.
- While calculation of RCB may not be mandatory, it is strongly recommended that the pathologist should give an indication of the degree of neoadjuvant chemotherapy response, both in breast and lymph nodes.

The system described below has the merit of simplicity and takes account of chemotherapy induced nodal change in addition to changes in the primary tumour and includes the components that the pathologist should assess:

Tumour response

- Complete pathological response, either (a) no residual carcinoma or (b) no residual invasive tumour but DCIS present.¹⁴⁷

- Partial response to therapy, either (a) minimal residual disease/near total effect typically (e.g. <10% of tumour remaining in the tumour bed seen as an area of residual fibrosis delineating the original tumour extent) or (b) 10–50% of tumour remaining or (c) >50% of tumour remaining. Comparison with the previous core biopsy sample may be helpful.
- No evidence of response to therapy.

Occasionally lymphovascular invasion alone is present with no residual invasive or in situ malignancy. This is not regarded as pCR. Pathologists should state this in their reports as it is a strong poor prognostic factor.¹⁴⁷

Nodal response

- No evidence of metastatic disease and no evidence of changes in the lymph nodes.
- Metastatic tumour not detected but evidence of response/down-staging, e.g. fibrosis.
- Metastatic disease present but also evidence of response, such as nodal fibrosis (Figure 44f).
- Metastatic disease present with no evidence of response to therapy.

It should be noted that there is also only limited clinical evidence for this system (albeit pragmatic)

9 Assessment of hormone receptors

9.1 Introduction

The steroid receptor (ER or both oestrogen and progesterone receptor [PR]) status of a breast cancer is used to determine whether or not a patient will benefit from endocrine therapy, either as adjuvant therapy or for metastatic disease.¹⁴⁸ Treatment with at least 5 years of anti-endocrine agents for women with ER-positive invasive carcinoma significantly reduces disease recurrence and mortality rates.¹⁴⁸ Women with ER-positive DCIS also benefit from adjuvant tamoxifen or aromatase inhibitor therapy with a reduction in disease recurrence reported following endocrine treatment.^{149–151}

IHC is the recommended method for assessing steroid receptor status.¹⁵² Any laboratory undertaking IHC must ensure that staining methodology is properly validated and results

are reproducible, allowing correct semiquantitative assessment. These guidelines have been formulated to give advice.

Assessment of ER status is essential for all invasive carcinomas.^{153,154}

The inclusion of PR in national datasets is controversial and the writing group has debated whether this receptor should be added to the RCPATH dataset, without definite conclusion. The latest American Society of Clinical Oncology (ASCO)/CAP guideline update notes that 'randomized trials in the adjuvant setting have revealed no difference in the degree of benefit from adjuvant endocrine treatment according to PR status' and acknowledges that 'only ER should be used as a predictor of benefit from adjuvant endocrine therapy'.¹⁵⁵ One view, therefore, is that PR testing as routine is of limited practical clinical value.

However, while PR is not a predictive factor for response to adjuvant endocrine therapy, it does provide prognostic information in those women with ER-positive tumours. It may also act as a quality control marker; for example ER-negative, PR-positive tumours are, at the least, very rare and this combination of hormone receptors should prompt review of quality of ER stained section and controls. For these reasons, ASCO/CAP and NICE recommend that PR is assessed in all invasive carcinomas.

In line with ASCO/CAP and NICE, PR testing could be considered as good practice for UK laboratories and included as a part of the biomarker panel, especially if resources permit.¹⁵³ However at present, given the lack of consensus agreement, it has not been included in the RCPATH dataset as a mandatory item.

Some multigene assays give a score for ER, PR and HER2. These should not be used for clinical decision-making. If there is a discordance with the immunohistochemical result, this is useful as a quality control measure and should be investigated.

[Level of evidence – A. ER status predicts response to endocrine therapies.]

9.2 Pre-analytic measures

9.2.1 Specimens

ER status should be assessed in all invasive primary breast carcinomas and in recurrent and metastatic tumours whenever biopsy tissue is available.^{153,154}

Bilateral carcinomas and histologically distinct ipsilateral tumours (i.e. lesions considered to be separate synchronous primaries) should each be assessed. It is deemed reasonable not to assess multiple ipsilateral tumours if they are histologically similar (i.e. regarded as

satellite foci). There is no consensus on testing residual invasive tumour following neoadjuvant therapy, although some recommend this approach.

A number of studies have shown that ER can be reliably assessed on core biopsy.^{156,157}

The agreement between core biopsy and surgical specimen is less for PR.¹⁵⁷

Steroid hormone receptor testing is usually performed on the diagnostic needle core biopsy specimen but repeat testing on the surgical excision specimen should be considered if the following are noted on the core biopsy:

- only scanty tumour cells are seen and the lesion has not been adequately sampled in the core biopsy
- low level atypical granular positive nuclear staining is present
- the carcinoma is morphologically heterogeneous in the resection and this heterogeneity was not present in the core biopsy
- there is poor tumour cell cytomorphology or cell damage, such as crushing artefact
- the result does not match that expected for the type and grade of the tumour
- a negative result with no internal control, or a low positive result (1–10% positive staining cells), taking into account tumour grade and morphology.

Histological tissue is the preferred specimen for ER and PR testing, however, fine needle aspirates may be used in circumstances where that is the only specimen available. FNA material should be fixed and cell block preparations used for this purpose.

9.2.2 Fixation and processing

Poor fixation will affect immunohistochemical staining; it is, therefore, essential that fixation protocols are precisely followed. The time from removal of the specimen to placing in an adequate volume of fixative should be kept to a minimum, ideally less than 1 hour. To obtain optimal fixation for operative specimens, it is recommended that specimens are received as soon as possible after surgery and sliced to allow rapid and even penetration of the fixative (please also see section 2.4). Established fixatives include either 10% neutral buffered formalin or 10% formal saline. Fixatives containing alcohol are not recommended. A minimum of 6 hours of fixation is recommended for core biopsies and 24 to 48 hours for excision specimens. There is evidence that prolonged fixation can result in reduced staining and should, therefore, be avoided. Centres using rapid fixation and processing must validate their methodology for ER and PR assessment. Prolonged

buffering has also been identified as a problem and some manufacturers do not recommend overnight runs for quantitative IHC. Sections should ideally be stained within 1–2 days of cutting and drying; the use of sections cut for more than 6 weeks is strongly discouraged. In the case of metastatic bone lesions that require ER and PR assessment, decalcification techniques may influence immunohistochemical assessment in a detrimental manner; ethylenediaminetetraacetic acid (EDTA)-based methods are the least detrimental.^{158,159}

9.2.3 Methods

Automated IHC platforms that have ‘on-board’ retrieval technologies are recommended. Duration of antigen retrieval is critical; too short a heating time can be a major cause of false negative ER staining and extended antigen retrieval has been shown to be a cause of false positive reactivity.^{160–162}

Well-characterised validated antibodies should be used. Updated recommendations of suitable clones and methods can be found on the UK NEQAS website.¹⁶³

A sensitive detection method should be employed. Polymer-based detection systems appear to be the method of choice and provide more sensitive results with cleaner staining results.

If changes are made either to the duration of antigen retrieval or to the detection system, as new reagents become available, it is important that all antibody titres are optimised to ensure clear nuclear staining with no cytoplasmic or background reactivity.

Nuclear counterstaining should not obscure weak positive staining.

The assay should be revalidated if any meaningful modification is made to the methodology, e.g. a change to antigen retrieval method or fixation.¹⁶⁴

9.3 Algorithm for steroid hormone receptor testing

IHC is the method of choice for assessing ER and PR status.

9.3.1 Scoring and reporting of results in invasive carcinoma

Only nuclear staining is considered and all of the invasive component should be assessed. Such quantitative scoring of ER positivity is recognised to be clinically relevant for predicting response to endocrine therapy and, for this reason, is mandated as a dataset requirement.

Hormone receptor status for invasive carcinoma should be recorded as positive or negative based on the percentage of tumour cells staining. Current consensus is that the recommended cut-off point for positivity versus negativity for ER and PR status is $\geq 1\%$ of tumour cells.¹⁵⁵

For ER only, staining in 1–10% of tumour cells should be reported as ER low positive.¹⁵⁵

For both ER (and PR if performed) the percentage of positive invasive carcinoma nuclei should be included in the report either as the absolute percentage, or in banded categories e.g. in 10% intervals. In addition, the average staining intensity, as weak, moderate or strong, or the score, using 1 of the methods detailed below, should be included in the report. The status of internal controls should also be reported if the tumour is negative or weakly positive.

There are several different scoring systems and there is no internationally accepted scoring method. The most widely used methods are based on a combination of intensity and estimation of the percentage of cells showing staining and are detailed in Table 8.

Table 8: The Allred/quick score and histochemical score (H score) methods for hormone receptor IHC semi-quantitative scoring.

| Allred score (0–8 quick score)¹⁵² | |
|---|----------------------------|
| Score for proportion | Score for intensity |
| 0 = no staining | 0 = no staining |
| 1 = <1% nuclei staining | 1 = weak staining |
| 2 = 1–10% nuclei staining | 2 = moderate staining |
| 3 = 11–33% nuclei staining | 3 = strong staining |
| 4 = 34–66% nuclei staining | |
| 5 = 67–100% nuclei staining | |
| The scores are summed to give a maximum of 8. | |
| The cut-off for positivity using Allred score ≥ 3 . | |
| H score¹⁶⁵ | |
| The percentage of weakly stained nuclei is multiplied by 1, the percentage of moderately stained nuclei is multiplied by 2, and the percentage of strongly stained nuclei is multiplied by 3; the total of these 3 is the H score, with a range of 0–300. | |

- Use of the Allred score assessment method can, in a small proportion of cases, conflict with the 1% cut point for positivity/negativity recommended above. All cases showing $\geq 1\%$ of tumours cells positive should be classified as receptor positive regardless of their Allred score. All cases showing $< 1\%$ of tumours cells positive should be classified as receptor negative regardless of their Allred score.
- Using modern immunohistochemical methods the distribution of ER score in invasive breast cancer is bimodal. Most carcinomas are either completely negative or convincingly positive with staining in $> 70\%$ of cells. Only a few percent of cases show staining between these 2 levels.¹⁶⁶
- Accurately defining the biological and clinical significance of a low percentage of ER staining, particularly the ER low positive (1–10%) category, is difficult as there are so few of these tumours.¹⁶⁷ Data suggests that these tumours show molecular heterogeneity and show greater similarity to ER negative than ER-positive tumours and the benefit of endocrine therapy for patients with these tumours is uncertain.¹⁶⁸ However, at present, the 1% cut-off is recommended for selecting patients for adjuvant endocrine treatment. A higher cut-off is often used for primary endocrine treatment or for the prediction of a pCR to neoadjuvant therapy.

There is evidence that a 10% cut-off is better for defining ER negativity in the context of identifying triple negative tumours to select patients for genetic testing for BRCA1 and BRCA2.¹⁶⁹ The distribution of PR staining and scores in breast cancer is also bimodal, but the proportion of tumours with low percentages of staining is higher.

9.3.2 Reporting and scoring results in DCIS

Assessment of ER status in patients with DCIS (without associated invasive tumour) is not a mandatory dataset requirement. However, it may be assessed if endocrine treatment is being considered. There is no consensus on cut-offs, unlike for invasive carcinoma. At the present time, it is recommended that the same scoring method and cut point for positivity used for invasive carcinoma be used for assessment of DCIS. There are currently no data to support the additional value of PR in DCIS.

9.4 Good practice and quality assurance measures

9.4.1 Validation of assay

All centres providing steroid hormone receptor testing must ensure that all elements of the process are comprehensively standardised and must participate in the relevant module of

the UK NEQAS quality assurance scheme. Validation of the test should also be carried out using UK NEQAS methodology.

9.4.2 Controls

These are particularly important and must be used. A composite block containing receptor rich, receptor poor and negative tissues or cell lines should be used, ideally on the same test slide and of material which is similarly fixed and processed to the test tissue. Control sections should be ideally cut at the same time as the test material. Long-term storage of pre-cut control sections is strongly discouraged and, if used, they should be stored in the refrigerator and appropriately validated. Tissues to be tested should have normal breast tissue present wherever possible as well as cancer; this acts as a good internal positive control and is particularly important if fixation is suboptimal. Negative controls should always be included. If there are any problems with the external controls or with the staining of internal normal tissue, staining should be repeated. If external cell lines are employed for on-slide controls, the laboratory should still use composite tissue blocks for troubleshooting and incoming quality control of new reagent batches.

9.4.3 Quality control considerations in specific scenarios

Particular attention should be paid to verify the test results for invasive carcinomas when ER is negative, low positive (1–10%) or when staining is weak. These cases are uncommon and interpretation of results at low levels of staining is subject to greater issues of reproducibility than diffuse staining.¹⁷⁰ Careful evaluation of the control tissue is important. If the controls did not stain as expected, i.e. analytic issues are suspected, then repeat testing should be considered. The type and grade of the carcinoma should be taken into account because better differentiated carcinomas (e.g. grade 1, lobular, mucinous, tubular type) are unlikely to be negative.

9.4.4 Case load

As semiquantitative predictive tests, ER and PR require a greater degree of technical and interpretive accuracy than routine IHC analyses which are purely diagnostic (positive or negative) and used as part of a panel. False positive and false negative results can lead to direct patient harm as a consequence of lack of benefit and unnecessary side effects from use of inappropriate treatment and denial of benefit from appropriate treatment, respectively.

Audits enable comparison between laboratory services but are not designed to replace the requirement for internal quality control and adequate quality assurance. Submission of

itemised pathology data as part of the Cancer Outcomes and Services Dataset (COSD) became mandatory for English NHS trusts from 1 January 2016. It is, therefore, anticipated that national collection of ER/PR status will improve from this date, as these are required COSD data items for breast cancers. This should enable more robust statistical analysis of variance in ER status.

It is difficult to set a minimum target of numbers to be reported for ER. However, there is evidence of higher consistency of predictive testing quality when assays are performed by high volume reference laboratories. Hence, testing centres with lower numbers of cases requiring ER and/or PR IHC should consider using a reference laboratory service.

9.4.5 Audit and benchmarking

Regular and ongoing audit should be undertaken. Laboratories should audit their overall positive rate for ER. It is important to ensure that the sample size is adequate. The positivity rate in the UK and Republic of Ireland from the UK NEQAS ICC and in situ hybridisation (ISH) breast biomarker audit of 199,300 patients was 80.8% for ER.

Table 9 shows the combined breast ER/PR receptor rate by HER2 IHC (adapted from Dodson *et al.*, 2018.)¹⁶⁶

Table 9: Distribution of ER and PR status by HER2 category.

| | ER neg/PR neg | ER neg/PR pos | Total ER neg | ER pos/PR neg | ER pos/PR pos | Total ER pos | Total |
|--------------------------|---------------|---------------|---------------|---------------|---------------|---------------|---------------|
| HER2 IHC 0 n (%) | 4,269 (36.7) | 235 (33.9) | 4,504 (36.5) | 2,725 (26.3) | 12,569 (30.2) | 15,295 (29.4) | 19,798 (30.8) |
| HER2 IHC 1+ (%) | 2,183 (18.7) | 155 (22.4) | 2,338 (18.9) | 2,929 (28.2) | 15,434 (37.1) | 18,363 (35.3) | 20,701 (32.2) |
| HER IHC 2+ (%) | 119 (9.6) | 63 (9.1) | 1,182 (9.6) | 1,502 (14.5) | 5,621 (13.5) | 7,123 (13.7) | 8,305 (12.9) |
| HER2 IHC 3+ n (%) | 2,955 (24.4) | 177 (25.5) | 3,132 (25.4) | 1,719 (16.6) | 2,368 (5.7) | 4,087 (7.9) | 7,219 (11.2) |
| Total * | 11,645 (18.1) | 693 (1.1) | 12,338 (19.2) | 10,377 (16.1) | 41,613 (64.7) | 51,990 (80.8) | 64,328 (100) |

*Percentage figures shown for the totals are proportions of the cases in the whole analysis.

It should be noted that the overall ER and PR positivity rates will vary, depending on whether the tumour is primary or metastatic and whether the patient presented with

symptomatic disease or the breast cancer was identified through the breast screening programme. Audits and benchmarking should take these factors into account.

9.5 Quality assurance for oestrogen receptor evaluation

All UK clinical laboratories using immunohistochemical assays for ER and PR as predictive or prognostic markers must participate in an appropriate EQA programme, such as that run by the UK NEQAS ICC and ISH.

UK NEQAS ICC and ISH monitor the performance of all UK clinical laboratories performing breast hormonal receptor staining. Because of the direct impact that the results of assays for hormonal receptors have on patient management, more stringent performance monitoring mechanisms are employed than for other assays.

10 Assessment of human epidermal growth factor receptor 2

10.1 Introduction

Overexpression of the human epidermal growth factor receptor 2 (HER2) protein, mainly due to HER2 gene amplification, in breast cancer is associated with aggressive histological features and poor prognosis.¹⁷¹ Randomised clinical trials and population studies have demonstrated substantial survival benefits in patients with HER2 positive breast cancer treated with anti-HER2 targeted therapy in both adjuvant and neoadjuvant and early and metastatic settings but not in HER2-negative patients.^{172–175} This, and evidence of higher response rates to neoadjuvant chemotherapy in HER2 positive tumour patients, has emphasised the need for accurate assessment of HER2 status in all invasive breast cancer patients.

In addition to this guidance, readers are also advised to refer to the *UK Recommendations for HER2 assessment in breast cancer: an update*.¹⁷⁶

Current data indicate that the frequency of HER2 positivity is between 13–20% in early breast cancer.

[Level of evidence – A. HER2 status predicts response to HER2-targeted therapies.]

10.2 Pre-analytical measures

10.2.1 Specimens

HER2 status should be assessed in all invasive primary breast carcinomas and in recurrent and metastatic tumours whenever biopsy tissue is available.¹⁵³ Bilateral carcinomas and histologically distinct ipsilateral tumours (i.e. lesions considered to be separate synchronous primaries) should each be assessed. It is deemed reasonable not to assess multiple ipsilateral tumours if they are histologically similar (i.e. regarded as satellite foci). There is no consensus on testing residual invasive tumour following neoadjuvant therapy, although some recommend this approach.

Excellent concordance between core biopsy and surgical specimens has been shown using IHC and ISH and it is recommended that HER2 testing is performed on the needle core biopsy specimen.^{157,177} Repeating the assay on a surgical specimen should be considered if:

- HER2 assessment is uninterpretable on the core biopsy due to technical artefacts (i.e. suboptimal processing or staining) or there is doubt about the core biopsy handling
- invasive tumour on the core is too small for reliable assessment or invasive disease is only present in the excision specimen. There is insufficient data to define the amount of invasive tumour tissue in core biopsy sufficient for analysis; however, this can be left to the reporting pathologist's discretion.
- if the tumour in the resection specimens is morphologically distinct from that in the core biopsy, for example of a clearly different histological type or histological grade (e.g. low grade on the core and high grade on the excision, but not just reflecting minor difference in the mitotic count or proportion of solid areas).¹⁷⁸
- a repeat may also be undertaken on concurrent metastatic nodal disease if it is morphologically distinct from the primary breast tumour
- if the core biopsy staining is heterogeneous and shows a focus of strong HER2 positivity in <10% of the invasive carcinoma in the core biopsy, HER2 testing may be repeated on the excision specimen. If this pattern is detected on the excision specimen, a different tumour block or a nodal metastasis can be tested, to determine the percentage of positive/amplified tumour present in a larger tumour sample.
- the core biopsy HER2 status remains in the equivocal category after IHC and ISH; for example, repeat assessment is advised if the core biopsy was scored as 2+ on HER2

IHC with borderline negative ISH (ratio of number of HER2 to chromosome 17 centromere copies of 1.8 to 1.99 or HER2 gene copy number 4–6).

If a cytological specimen is the only material available, or in metastatic disease, HER2 status may be assessed on this, preferably on cell block preparations.¹⁷⁹

- In the case of metastatic bone lesions that require HER2 assessment, decalcification techniques may influence immunohistochemical assessment in a detrimental manner; EDTA-based methods are the least detrimental.^{158,180} In decalcified specimens, assessment of ISH may be prudent, unless IHC is definitive.

10.2.2 Fixation and processing

Good fixation of specimens used for HER2 testing should be ensured and the cold ischaemic time (time from removal from the patient to placing in fixative [cold ischaemic time]) should be as short as possible, preferably less than 1 hour. Tumour samples should be fixed in 10% neutral buffered formalin; fixatives containing alcohol can result in staining of normal tissue and use of Bouin's fixative will preclude testing by fluorescence in situ based methods. At least 6 hours' fixation is recommended for core biopsies. Surgical specimens should be incised for optimal fixation (see macroscopy section) and fixed for at least 24 hours but not more than 72 hours. Prolonged fixation is typically more likely if core biopsies are taken before, but not processed, over a weekend or bank holiday weekend/long weekend. Centres using rapid fixation and processing must validate their methodology for HER2 assessment.

Sections should be stained within 1–2 days of cutting and drying. Excessive section drying time has been shown to cause a loss of HER2 expression. It is, therefore, recommended that freshly cut sections are either dried at 60°C for 1 hour or 37°C overnight.¹⁸¹

10.3 Algorithm for HER2 testing

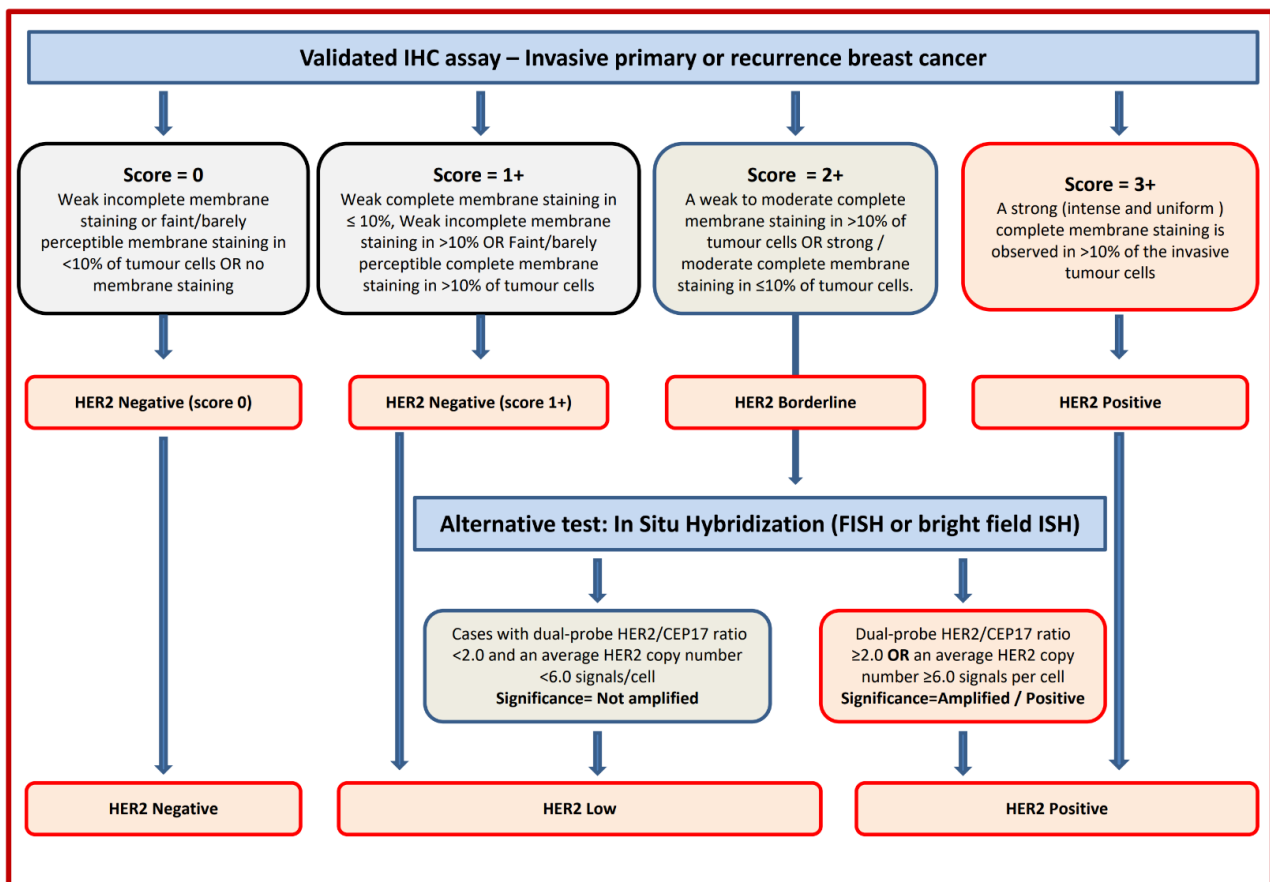
10.3.1 Principles

IHC for detection of protein overexpression and ISH for detection of gene amplification status are the techniques recommended for determining HER2 status. High concordance between IHC and gene amplification status is reported.^{182,183}

The current UK recommendations for HER2 testing are for a 2-tier system using IHC with reflex ISH testing if required, using the model shown in Figure 53, or a 1-tier ISH strategy (the latter particularly if the quality of tissue fixation is questionable).¹⁸⁴ Fluorescence ISH (FISH) technique or bright field, chromogenic ISH (CISH), are acceptable techniques. ISH

can be conducted using a single probe to enumerate HER2 copies per nucleus or as a dual-probe technique which allows determination of the HER2: chromosome 17 centromeric region (CEP17) ratio and HER2 gene copy number; the inclusion of a CEP17 probe is recommended.

Figure 53: Recommended HER2 scoring algorithm for IHC and ISH. *Insufficient data is available to comment on moderate complete membrane staining in $\leq 10\%$ of tumour cells or strong incomplete membrane staining in $>10\%$ of tumour cells. A repeat on another specimen/tissue block is advisable. **Membrane staining must be intense and uniform and resemble chicken-wire. Ignore incomplete or pale membrane staining in the percentage estimation.



Other HER2 testing techniques (polymerase chain reaction, enzyme-linked immunosorbent assay, Southern blotting, mRNA assays and DNA microarray) (for example results from commercial multigene assays) should not be used for patient management.

For assessment of both HER2 IHC and ISH preparations, training and experience in interpretation of histological characteristics of breast tissue is essential. Recognition of different histological tumour types is required. In particular, HER2 status should only be determined on the invasive portion of the tumour, and neither IHC nor ISH should be

reported in isolation. If it is difficult to differentiate invasive from in situ disease in the index tumour block submitted for ISH, IHC markers for myoepithelial cells can be used.

10.3.2 Assessment and scoring IHC

Only membrane staining of the invasive tumour should be considered when scoring HER2. Cytoplasmic staining and staining of in situ disease should not be scored and normal epithelium should be negative. The HER2 IHC scoring method is a semi-quantitative system based on the intensity of reaction product and percentage of membrane positive cells, giving a score range of 0 to 3+ (Figure 53). Samples scoring 3+ are regarded as unequivocally positive, and those scoring 0/1+ as negative. Borderline scores (2+) are regarded as equivocal and mandate further assessment using ISH (Figure 45). The HER2 test should be reported as indeterminate and repeated whenever possible, if technical issues prevent 1 or both tests (IHC and ISH) from being reported as positive, negative or equivocal. Examples include: inadequate specimen handling, artefacts (e.g. crush or marked edge artefacts) that make interpretation difficult, analytic testing failure or if controls are not as expected (i.e. sample shows strong membrane staining of normal breast tissue). In such a case, an alternative test, or another specimen if available, should be used to determine HER2 status.

10.3.3 Assessment and scoring in situ hybridisation

The UK recommendation is to use dual-probe ISH and report the HER2/Ch 17 signal ratio, HER2 copy number and Ch17 copy number.¹⁸⁴

A selection of normal cells should be assessed to confirm successful hybridisation, detection and visualisation, before assessment of the invasive carcinoma. Then, the number of Ch17 and HER2 signals is scored, recorded and the mean HER2 to Ch17 copy ratio is calculated for 20–60 cells, where possible using at least 3 distinct tumour fields. In most cases, where either clear amplification is observed or the ratio is below 1.5, scoring of 20 tumour cells is sufficient. Only cells in which the nuclear borders can be identified should be counted. Over-digested, damaged and truncated nuclei should not be scored. Only cells with a minimum 1 copy of HER2 and CEP17 should be scored. The location of the areas assessed should ideally be recorded. In cases where tumour heterogeneity is seen, or if the ratio is close to 2.0, or if the average copy number is between ≥ 4.0 and < 6.0 signals/cell, more cells should be scored (at least 60), for details see below. A minimum of 10% of cases should be double-reported to ensure consistency between observers.

The ISH report should include: the number of cells scored, the average HER2 and CEP17 copy number and the HER2/CEP17 ratio. Unusual features should be noted. For heterogeneous cases (see below) all these details should be reported for each subclone. If there is a problem in specimen handling and/or processing (i.e. non-adherence to the guidelines), this should be documented in the report.

- Cases with dual-probe HER2/CEP17 ratio <2.0 and with an average HER2 copy number <6.0 signals/cell are considered as HER2 negative (Figure 53).
- Tumours showing a ratio ≥ 2.0 and/or a mean HER2 gene copy number ≥ 6 are considered to be positive.
- Cases with HER2 gene copy number ≥ 6 and HER2/CEP17 ratio <2 are regarded as positive.
- Classification of cases with a HER2/CEP17 ratio ≥ 2.0 but HER2 gene copy number <4 are controversial. These characteristics are found in a small but significant number of cases. ASCO-CAP US guidelines recommend such cases (FISH Group 2) are regarded as negative.¹⁸⁵ In a retrospective analysis of neoadjuvant chemotherapy-treated patients with invasive breast cancers that were IHC 2+, HER2 CEP17 ratio ≥ 2.0 but with HER2 copy number <4 , an essentially similar response to neoadjuvant therapy as in all others with HER2 CEP17 ratio ≥ 2.0 was, however, reported.¹⁸⁶ At present therefore, no formal change is to be made to this UK guidance and tumours with HER2/CEP17 ratio >2.0 are all considered HER2 positive. Invasive breast cancers that are 3+ positive with IHC more frequently show pCR to neoadjuvant chemotherapy than cases with 2+ IHC that are classified as showing *Her2* gene amplification.
- Cases with a HER2/CEP17 borderline negative ratio result (i.e. between 1.8 and 1.99) on a needle core biopsy sample, should have repeat assessment on the surgical excision specimen. There is a lack of published evidence to support further testing for cases exhibiting mean HER2 copies/cell between 4 and 6 with a HER2/CEP17 ratio below 1.8 and it is recommended that such rare cases be reported as HER2 negative and repeat testing be performed on the surgical specimen.
- The HER2 ISH test should be reported as indeterminate and a repeat/alternative test (on the same or another specimen) is requested in the following situations: controls are not as expected, nuclear resolution is poor, if a significant proportion of signals are unscorable due to weak signals or $>10\%$ of signals occur over cytoplasm,

autofluorescence is strong or the observer cannot find and count at least 2 areas of invasive tumour.

10.3.4 Heterogeneity of HER2 ISH

Genomic heterogeneity refers to the coexistence of more than 1 population of tumour cells with distinct HER2 amplification characteristics within the same tumour. Intra-tumoral heterogeneity can be seen as a clustered form where distinct populations/clones of amplified and non-amplified tumour cells coexist, or as a mosaic form which includes the presence of isolated amplified cells in a predominantly non-amplified tumour, or a diffuse mixture of amplified and non-amplified cells across the tumour.¹⁷⁶ While such heterogeneity is generally uncommon in breast cancer, the following approach has been proposed to manage heterogeneous HER2 gene amplification in breast cancer and is recommended.¹⁷⁶

- In all cases where ISH is performed, the entire slide should be scanned before counting and areas of apparent heterogeneity should be identified during this scan and/or by reference to an IHC stained slide. The number of CEP17 and HER2 signals should be counted in 20–60 non-overlapping invasive cancer cell nuclei, as described above.
- In the clustered pattern of HER2 heterogeneity, if the second population of cells with increased HER2 signals/cell is >5% of all tumour cells, separate counting of at least 20 non-overlapping cells should be performed within this population. The HER2/CEP17 ratio and HER2 copy number should be calculated and reported separately for the amplified and non-amplified areas. This should be reported as HER2 positive (but with heterogeneous amplification). Retesting of the excision specimen and/or an axillary lymph node metastasis should be considered, particularly in cases showing a low percentage of amplified clone as this clone may be enriched in the node metastasis or elsewhere in the primary tumour.
- In the mosaic heterogeneous pattern, counting additional cells (at least 60 non-overlapping cells in the area of invasion with IHC 2+ staining) is advised and the average copy number and ratio are used to define HER2 status. If the final ratio is <2.0 and the HER2 copy number is <6.0, the sample is considered HER2 negative. Re-testing on the excision or axillary metastasis, if present, should be considered.

- In the scattered pattern of heterogeneity, 60 cells in areas containing more amplified cells should be counted; tumour HER2 status is defined based on the average HER2 gene copy number and the HER2/CEP17 ratio.

In borderline cases, i.e. those with a HER2/CEP17 ratio of 1.80–2.20, additional cells should be counted (optimally a minimum of 60 per case); ideally, this should include a dual count (from a second observer; either internally or in a second centre). The optimal approach to improving accuracy in this range is to increase the number of cells counted to 60–120 and/or repeat the test. A ratio of 1.80–1.99, after counting further cells and/or repeating the test, should be reported as borderline but not amplified and include a clear statement that the carcinoma is regarded as HER2 negative (taking the mean HER2 copy number into consideration [mean <6 copies/cell]). In essence, if the ISH test result remains borderline and close to the ISH ratio threshold for positivity (HER2 copy number 4.0 to <6.0 and/or a ratio 1.8 to <2.0), there is a high likelihood that repeat testing on the same, or even on a different tumour block/sample, may result in different results (i.e. just the other side of a cut-point) by chance alone. Thus, whether to repeat on a different specimen in this situation will depend on the adequacy of the specimen, rather than nearness to the cut-points for defining *Her2* positivity.

While these guidelines are sufficient for the majority of cases, there are occasions when difficult cases should be referred to expert centres for guidance. Variation increases with highly amplified samples and is not critical where the ratio of HER2/CEP17 exceeds 4. Where possible, count all signals, but if this is not possible, for example if clusters are present, then try to estimate the number of signals. Count doublets as a single signal. Where resources permit, representative images can be captured and archived. Difficult cases should be assessed by a second observer.

10.3.5 Impact of heterogeneity of IHC and ISH

Although a cut-off of >10% of the invasive tumour area using IHC is used to define positivity, rare cases showing complete intense membrane staining in <10% of tumour cells are seen and should be considered in the borderline category. In such cases, a repeat of the HER2 IHC test should be undertaken on another specimen or a different tumour block in surgical specimens to determine the percentage of positive tumour present. If this repeat IHC assessment shows a similar pattern, ISH may be performed. Variation in immunostaining between the periphery and centre of tumours can be due to a fixation gradient.

Defining HER2 positivity using ISH may be complex in cases with intratumoural heterogeneity (see above). Such genetic heterogeneity affects a proportion of breast cancer (11–40%) and is more frequently seen in HER2 positive tumours.¹⁷⁶ Although no clinical data is available to guide on the likely response to anti-HER2 therapy of genetically heterogeneous tumours harbouring HER2-amplified subclones, it would be valuable to standardise the definition of genetic heterogeneity to facilitate future study of its clinical relevance.

10.4 Good practice and quality assurance measures

10.4.1 Appropriate laboratory methods

For both IHC and ISH-based HER2 testing, comprehensive standardisation of methodology, including monitoring of scoring procedures and the inclusion of validated controls, is mandatory. In the UK, participation and satisfactory performance in the [UK NEQAS ICC and ISH HER2 IHC and ISH modules](#) is a mandatory requirement.

Standardisation of HER2 IHC staining is best achieved by using a commercial kit/assay with strict adherence to the kit/assay protocol and scoring methodology. Local modifications of techniques can lead to false positive and negative results. Laboratories using bright field ISH should perform an initial validation against FISH.

Inter-observer variation in the assessment of IHC staining can lead to misclassification of HER2 status. Each individual assessor should standardise scoring against known positive, negative and borderline cases. It is also preferable to assess comparability of scoring with a colleague on a regular basis.

Published data suggest that inter-observer variation is significantly lower for FISH than for IHC. However, especially when developing a new service, care needs to be taken. Laboratories should perform validation studies by dual observer scoring when training new staff until there is concordance of 95%. Each staff member should perform a minimum of 100 ISH tests in parallel with an experienced ISH scorer to attain a minimum concordance of 95% on diagnostic results (amplified and non-amplified status) and numerical results (for both HER2 and CEP17). Continued monitoring of scoring offers advantages in quality control and training.

10.4.2 Validation of standardised assay method

Any laboratories intending to start HER2 testing, by IHC or ISH, should refer to [UK NEQAS](#) for advice on methodology and validation.

10.4.3 IHC principles and use of controls

The inclusion of controls, ideally on-slide control(s), and their detailed scrutiny are essential to ensure test accuracy. Controls whose HER2 status has been validated and produce results close to important decision-making points are recommended. Tissue-based (or cell-based) controls should also be used on all slides, ideally showing 3+, 2+, 1+ and 0 patterns. Control material should be similarly fixed and processed to the test tissue. If you are using an external source of controls (tissue or cell lines), these should be validated in-house. The laboratory should ideally also have a composite block of verified in-house tissue, e.g. for incoming quality control and troubleshooting, which will be similarly fixed and processed to the test tissue. Notably, if submitting cell lines to UK NEQAS as part of the HER2 scheme, the inclusion of a tumour tissue is necessary as part of the submission to demonstrate the quality of the tissue produced in-house.

- Control sections should ideally be cut at the same time as the test material. Long-term storage of pre-cut control sections is discouraged but, if used, should be validated in the laboratory; for example, they should be stored in a refrigerator and validated over the period of time that they would be in use.
- Excessive antigen retrieval should be monitored by evaluating normal breast epithelial cells as an internal control. Should membrane staining be identified in the normal cell population, excessive antigen retrieval may have occurred and retesting of the entire run should be considered. Any such tests should certainly be interpreted with caution. If there is doubt between a 1+/2+ result and a 2+/3+ result, either the IHC should be repeated or amplification status should be assessed using ISH. If membrane staining of normal epithelial cells is seen in a number of cases from the same staining run, consideration should be made to repeat staining of the whole run. If the morphology of a cell line control is overtly affected, it may indicate over-retrieval.
- Crushing and edge artefact particularly affect core biopsies. ISH, or repeat IHC on the surgical specimen, may be needed. The potential gradient effects of suboptimal fixation, particularly in larger surgical specimens, must also be considered in interpretation of staining.
- It is essential that assay procedures be standardised so that staining is reliable. As there can be variation between batches of reagents, it is vital that controls are assessed critically for every run. New batches of antibody should also be tested before

commencing routine application. Use of standardised operating procedures, including routine use of control materials, is necessary.

[Level of evidence – GPP.]

10.4.4 ISH principles and use of controls

ISH testing for HER2 should meet the following criteria:

- comprehensive standardisation of methodology
- validated controls: the inclusion of a chromosome 17 probe to allow for correction of the HER2 signal number for chromosome 17 aneusomy (seen in ~30% of cases and reportedly commoner in tumours that show discrepant HER2 expression and in tumours with discordant HER2-protein and gene copy number measurements) is recommended.

10.4.5 Turnaround

Short turnaround times for HER2 testing that do not delay the management of patients are essential. Turnaround time is recognised to be variable between different centres and can be addressed at the level of cancer networks and local services (Figure 53).

It is also important to emphasise the role of improved communication between pathologists/laboratories performing the test and clinicians to ensure proper handling of specimens (i.e. pre-fixation time and fixation type), short turnaround time and ensure proper interpretation of the test results.

10.4.6 Caseload

Laboratories providing a testing service should be carrying out a minimum of 250 assays per year for immunohistochemical detection of HER2. This target level has been set to ensure higher consistency of assay quality and continuing expertise of assay providers.

Centres with low numbers of cases (<250 per year) should consider using a reference laboratory service.

Similar principles apply to ISH testing; it is recommended that laboratories testing <100 cases per year (<150 including gastric carcinomas) consider referral of their workload to a reference laboratory. A smaller caseload has been set for ISH assay, as it is generally accepted to be a more discriminant test at the positive–negative borderline, has greater ease of methodological standardisation and has less observer variation.

10.4.7 Audit

Regular and ongoing audit should be undertaken. Laboratories should audit their overall positive rate for HER2 using a combination of IHC and ISH. It is important to ensure that the sample size is adequate. Of note, the average proportion of invasive breast cancer cases recorded as HER2 positive is 14.5% (UK NEQAS ICC and ISH combined 5-year national audit data), with 14.2% of primary carcinomas and 18% of metastatic cases being HER2 positive (Table 10). Of these cases approximately 22% cases are reported as borderline (2+) on IHC, of which 15–16% are reported as HER2 ISH amplified. More recent data show a slightly lower overall positive rate of 13.1%.¹⁶⁶ The proportion of HER2 positive breast cancers found in screen-detected breast cancer cases is recognised to be lower than in symptomatic practice.

Audit of HER2 assay turnaround time is also important, as it is critical to patient pathway.¹⁸⁸

Table 10: Proportion of HER2 positive primary and metastatic breast cancers.

| | 0 (%) | 1+ (%) | 2+ (%) | 3+ (%) | ISH + (%) | Overall HER2 positive (%) |
|--------------------------|-------|--------|--------|--------|-----------|---------------------------|
| Overall | 33.1 | 33.6 | 21.7 | 11.6 | 14.7 | 14.5 |
| Primary carcinoma | 32.9 | 34.0 | 21.7 | 11.5 | 14.6 | 14.2 |
| Metastatic lesion | 36.6 | 27.4 | 21.1 | 14.9 | 16.2 | 18.0 |

10.5 Quality assurance for HER2 receptor evaluation

All UK clinical laboratories using immunohistochemical assays or ISH to assess HER2 status as a predictive or prognostic marker must participate in an appropriate EQA programme, such as that run by the UK NEQAS ICC and ISH.

11 Comments/additional information

Any relevant information should be entered here as free text. Please also state whether any further special investigations have been undertaken, such as additional receptor assessment or growth fraction analysis. Many centres now use combinations of prognostic factors in the form of a prognostic index to assist clinical management. Guidance on prognostic classifiers such as the NPI is given in Appendix H.

12 Non-core data items

Please refer to items in italics in the proforma. These are as follows.

12.1 Macroscopic data items

It is considered good practice to include the presence of a specimen radiograph, mammographic abnormality, previous core biopsy site and histological calcification in the report for better clinico-pathological correlation.

Note: the information above is not always available to the pathologist.

12.2 Histological grade components

Provision of an overall grade is a mandatory/core data item. However, provision of the individual grade components are non-core items. This information can sometimes be helpful in evaluating grade discrepancies, for example between core biopsies and resections or if prompt formalin fixation is a problem for resection specimens resulting in persistent low mitotic counts.

12.3 Lymph node stage

The presence of extracapsular spread, perinodal fat involvement and summary of lymph node stage can be used in research settings but are not essential for patient management.

12.4 Biomarker status

- Allred score.
- H score.
- On-slide positive control material.
- PR status.

- % positive tumour cells.
- Average intensity of staining.
- HER2 ISH ratio.
- HER2 copy no.
- Proliferation (Ki67) index.

Note: please refer to sections 9 and 10 and Appendix G for more detailed explanations.

13 Criteria for audit

The following are recommended by the RCPATH as key assurance indicators (see [Key assurance indicators for pathology services, November 2019](#)) and key performance indicators (see [Key performance indicators – Proposals for implementation, July 2013](#)).

- Cancer resections must be reported using a template or proforma, including items listed in the English COSD which are, by definition, core data items in RCPATH cancer datasets. English trusts are required to implement the structured recording of core pathology data in the COSD by January 2014.
- Standard: 95% of reports must contain structured data.
- Histopathology cases that are reported, confirmed and authorised within 7 and 10 calendar days of the procedure.
- Standard: 80% of cases must be reported within 7 calendar days and 90% within 10 calendar days.

The following standards are also suggested:

- Completeness of histopathology core items recorded. The standard is that reports should contain 100% of the core items.

14 References

1. Classification of Tumours Editorial Board. *WHO Classification of Tumour Series: Breast Tumours (5th edition)*. Lyon, France: International Agency for Research on Cancer, 2019.
2. UK National Breast Pathology. *Interpretive EQA Scheme*. Accessed October 2022. Available at: www.nccbp.com
3. Pinder SE, Shaaban A, Deb R, Desai A, Gandhi A, Lee AHS *et al*. NHS Breast Screening multidisciplinary working group guidelines for the diagnosis and management of breast lesions of uncertain malignant potential on core biopsy (B3 lesions). *Clin Radiol* 2018;73:682–692.
4. Association of Breast Surgery at BASO 2009. Surgical guidelines for the management of breast cancer. *Eur J Surg Oncol* 2009;35:1–22.
5. Buesa RJ, Peshkov MV. How much formalin is enough to fix tissues? *Ann Diagn Pathol* 2012;16:202–209.
6. Zarbo RJ. Histologic validation of vacuum sealed, formalin-free tissue preservation, and transport system. *Recent Results Cancer Res* 2015;199:15–26.
7. Bussolati G, Chiusa L, Cimino A, D'Armento G. Tissue transfer to pathology labs: under vacuum is the safe alternative to formalin. *Virchows Arch* 2008;452:229–231.
8. Kizhakkoottu S, Jayaraj G, Sherlin HJ, Don KR, Santhanam A. Inking of gross specimens: a systematic review. *Arkh Patol* 2021;83:49–52.
9. Singleton M, Firth M, Stephenson T, Morrison G, Baginska J. Radiation-guided breast sentinel lymph node biopsies – is a handling delay for radiation protection necessary? *Histopathol* 2012;61:277–282.
10. Hodi Z, Ellis IO, Elston CW, Pinder SE, Donovan G, Macmillan RD *et al*. Comparison of margin assessment by radial and shave sections in wide local excision specimens for invasive carcinoma of the breast. *Histopathol* 2010;56:573–580.
11. Association of Breast Surgery. *Association of Breast Surgery consensus statement: Margin width in breast conservation surgery*. Accessed February 2022. Available at: <https://associationofbreastsurgery.org.uk/media/64245/final-margins-consensus-statement.pdf>

12. Thomson JZ, Evans AJ, Pinder SE, Burrell HC, Wilson AR, Ellis IO. Growth pattern of ductal carcinoma in situ (DCIS): a retrospective analysis based on mammographic findings. *Br J Cancer* 2001;85:225–227.
13. Wang K, Ren Y, He J. Cavity shaving plus lumpectomy versus lumpectomy alone for patients with breast cancer undergoing breast-conserving surgery: A systematic review and meta-analysis. *PLoS One* 2017;12:e0168705.
14. Tang SS, Kaptanis S, Haddow JB, Mondani G, Elsberger B, Tasoulis MK *et al.* Current margin practice and effect on re-excision rates following the publication of the SSO-ASTRO consensus and ABS consensus guidelines: a national prospective study of 2858 women undergoing breast-conserving therapy in the UK and Ireland. *Eur J Cancer* 2017;84:315–324.
15. Sikand K, Lee AH, Pinder SE, Elston CW, Ellis IO. Sections of the nipple and quadrants in mastectomy specimens for carcinoma are of limited value. *J Clin Pathol* 2005;58:543–545.
16. Baslaim MM, Al Malik OA, Al-Sobhi SS, Ibrahim E, Ezzat A, Ajarim D *et al.* Decreased axillary lymph node retrieval in patients after neoadjuvant chemotherapy. *Am J Surg* 2002;184:299–301.
17. Gandhi A, Coles C, Makris A, Provenzano E, Goyal A, Maxwell AJ *et al.* Axillary surgery following neoadjuvant chemotherapy – Multidisciplinary guidance from the Association of Breast Surgery, Faculty of Clinical Oncology of the Royal College of Radiologists, UK Breast Cancer Group, National Coordinating Committee for Breast Pathology and British Society of Breast Radiology. *Clin Oncol (R Coll Radiol)* 2019;31:9:664–668.
18. Jones JL, Hanby AM, Wells C, Calaminici M, Johnson L, Turton P *et al.* Breast implant-associated anaplastic large cell lymphoma (BIA-ALCL): an overview of presentation and pathogenesis and guidelines for pathological diagnosis and management. *Histopathology* 2019;75:787–796.
19. Xu X, Roberts SA, Pasha TL, Zhang PJ. Undesirable cytokeratin immunoreactivity of native nonepithelial cells in sentinel lymph nodes from patients with breast carcinoma. *Arch Pathol Lab Med* 2000;124:1310–1313.
20. Giuliano AE, Hunt KK, Ballman KV, Beitsch PD, Whitworth PW, Blumencranz PW *et al.* Axillary dissection vs no axillary dissection in women with invasive breast cancer and sentinel node metastasis: a randomized clinical trial. *JAMA* 2011;305:569–575.

21. Association of Breast Surgery. *Association of Breast Surgery consensus statement: Management of the malignant axilla in early breast cancer*. Accessed February 2022. Available at: <https://associationofbreastsurgery.org.uk/media/64197/final-axilla-consensus-statement.pdf>
22. Liu LC, Lang JE, Lu Y, Roe D, Hwang SE, Ewing CA *et al*. Intraoperative frozen section analysis of sentinel lymph nodes in breast cancer patients: a meta-analysis and single-institution experience. *Cancer* 2011;117:250–258.
23. Tew K, Irwig L, Matthews A, Crowe P, Macaskill P. Meta-analysis of sentinel node imprint cytology in breast cancer. *Br J Surg* 2005;92:1068–1080.
24. Wells CA, El-Ayat GA. Non-operative breast pathology: apocrine lesions. *J Clin Pathol* 2007;60:12:1313–1320.
25. D'Arcy C, Quinn C. Apocrine lesions of the breast: part 1 of a two-part review: benign, atypical and in situ apocrine proliferations of the breast. *J Clin Pathol* 2019;72:1–6.
26. Asirvatham JR, Falcone MM, Kleer CG. Atypical apocrine adenosis: Diagnostic challenges and pitfalls. *Arch Pathol Lab Med* 2016;140:1045–1051.
27. Feeley L, Quinn CM. Columnar cell lesions of the breast. *Histopathology* 2008;52:11–119.
28. Abdel-Fatah TM, Powe DG, Hodi Z, Reis-Filho JS, Lee AH, Ellis IO. Morphologic and molecular evolutionary pathways of low nuclear grade invasive breast cancers and their putative precursor lesions: Further evidence to support the concept of low nuclear grade breast neoplasia family. *Am J Surg Pathol* 2008;32:513–523.
29. Collins LC. Precursor lesions of the low-grade breast neoplasia pathway. *Surg Pathol Clin* 2018;11:177–197.
30. Fraser JL, Raza S, Chorny K, Connolly JL, Schnitt SJ. Columnar alteration with prominent apical snouts and secretions: A spectrum of changes frequently present in breast biopsies performed for microcalcifications. *Am J Surg Pathol* 1998;22:1521–1527.
31. Senetta R, Campanino PP, Mariscotti G, Garberoglio S, Daniele L, Pennecci F *et al*. Columnar cell lesions associated with breast calcifications on vacuum-assisted core biopsies: Clinical, radiographic, and histological correlations. *Mod Pathol* 2009;22:762–769.

32. Tan BY, Acs G, Apple SK, Badve S, Bleiweiss IJ, Brogi E *et al.* Phyllodes tumours of the breast: a consensus review. *Histopathology* 2016;68:5–21.
33. Bacchi CE, Wludarski SC, Lamovec J, Ben Dor D, Ober E, Salviato T *et al.* Lipophyllodes of the breast. A reappraisal of fat-rich tumors of the breast based on 22 cases integrated by immunohistochemical study, molecular pathology insights, and clinical follow-up. *Ann Diagn Pathol* 2016;21:1–6.
34. Lerwill MF, Lee AHS, Tan PH. Fibroepithelial tumours of the breast—a review. *Virchows Arch* 2022;480:45–63.
35. Wen B, Mousadoust D, Warburton R, Pao JS, Dingee C, Chen L *et al.* Phyllodes tumours of the breast: Outcomes and recurrence after excision. *Am J Surg* 2020;219:790–794.
36. Genco IS, Purohit V, Hackman K, Ferreira L, Tugertimur B, Hajiyeva S. Benign and borderline phyllodes tumors of the breast: Clinicopathologic analysis of 205 cases with emphasis on the surgical margin status and local recurrence rate. *Ann Diagn Pathol* 2021;51:151708.
37. Tse G, Koo JS, Thike AA. Phyllodes tumour. *Breast Tumours (5th edition)*. Lyon, France: International Agency for Research on Cancer, 2019.
38. Collins LC, Schnitt SJ. Papillary lesions of the breast: selected diagnostic and management issues. *Histopathology* 2008;52:20–29.
39. Tay TKY, Tan PH. Papillary neoplasms of the breast-reviewing the spectrum. *Mod Pathol* 2021;34:1044–1061.
40. Lewis JT, Hartmann LC, Vierkant RA, Maloney SD, Shane Pankratz V, Allers TM *et al.* An analysis of breast cancer risk in women with single, multiple, and atypical papilloma. *Am J Surg Pathol* 2006;30:665–672.
41. Quinn CM, D'Arcy C, Wells C. Apocrine lesions of the breast. *Virchows Arch* 2022;480:177–189.
42. Putti TC, Pinder SE, Elston CW, Lee AH, Ellis IO. Breast pathology practice: most common problems in a consultation service. *Histopathology* 2005;47:5:445–457.
43. Foschini MP, Eusebi V. Microglandular adenosis of the breast: a deceptive and still mysterious benign lesion. *Hum Pathol* 2018;82:1–9.
44. Wen YH, Weigelt B, Reis-Filho JS. Microglandular adenosis: a non-obligate precursor of triple-negative breast cancer? *Histol Histopathol* 2013;28:1099–1108.

45. Kravtsov O, Jorns JM. Microglandular adenosis and associated invasive carcinoma. *Arch Pathol Lab Med* 2020;144:42–46.
46. Comer JD, Cui X, Eisen CS, Abbey G, Arleo EK. Myofibroblastoma of the male breast: a rare entity with radiologic-pathologic correlation. *Clin Imaging* 2017;42:109–112.
47. Johnson RE, Murad MH. Gynecomastia: pathophysiology, evaluation, and management. *Mayo Clin Proc* 2009;84:1010–1015.
48. Rahmani S, Turton P, Shaaban A, Dall B. Overview of gynecomastia in the modern era and the Leeds Gynaecomastia Investigation algorithm. *Breast J* 2011;17:246–255.
49. Kornegoor R, Verschuur-Maes AH, Buerger H, van Diest PJ. The 3-layered ductal epithelium in gynecomastia. *Am J Surg Pathol* 2012;36:762–768.
50. Speirs V, Shaaban AM. The rising incidence of male breast cancer. *Breast Cancer Res Treat* 2009;115:429–430.
51. Cardoso F, Bartlett JMS, Slaets L, van Deurzen CHM, van Leeuwen-Stok E, Porter P *et al*. Characterization of male breast cancer: results of the EORTC 10085/TBCRC/BIG/NABCG International Male Breast Cancer Program. *Ann Oncol* 2018;29:405–417.
52. Ruddy KJ, Winer EP. Male breast cancer: risk factors, biology, diagnosis, treatment, and survivorship. *Ann Oncol* 2013;24:1434–43.
53. Chamseddine RS, Wang C, Yin K, Wang J, Singh P, Zhou J *et al*. Penetrance of male breast cancer susceptibility genes: a systematic review. *Breast Cancer Res Treat* 2022;191:31–38.
54. Hultborn R, Hanson C, Köpf I, Verbiené I, Warnhammar E, Weimarck A. Prevalence of Klinefelter's syndrome in male breast cancer patients. *Anticancer Res* 1997;17:4293–4297.
55. Fox S, Speirs V, Shaaban AM. Male breast cancer: an update. *Virchows Arch* 2021;doi: 10.1007/s00428-021-03190-7
56. Hittmair AP, Liningier RA, Tavassoli FA. Ductal carcinoma in situ (DCIS) in the male breast: a morphologic study of 84 cases of pure DCIS and 30 cases of DCIS associated with invasive carcinoma--a preliminary report. *Cancer* 1998;15:83:2139–49.

57. Anderson WF, Devesa SS. In situ male breast carcinoma in the Surveillance, Epidemiology, and End Results database of the National Cancer Institute. *Cancer* 2005;104:1733–41.
58. Shaaban AM, Ball GR, Brannan RA, Cserni G, Di Benedetto A, Dent J *et al.* A comparative biomarker study of 514 matched cases of male and female breast cancer reveals gender-specific biological differences. *Breast Cancer Res Treat* 2012;133:949–958.
59. Zhong E, Cheng E, Goldfischer M, Hoda AS. Papillary lesions of the male breast: A study of 117 cases and brief review of the literature demonstrate a broad clinicopathologic spectrum. *Am J Surg Pathol* 2020;44:68–76.
60. Humphries MP, Sundara Rajan S, Honarpisheh H, Cserni G, Dent J, Fulford L *et al.* Characterisation of male breast cancer: a descriptive biomarker study from a large patient series. *Sci Rep* 2017;28:45293.
61. Carder PJ, Speirs V, Ramsdale J, Lansdown MR. Expression of prostate specific antigen in male breast cancer. *J Clin Pathol* 2005;58:69–71.
62. Biserni GB, Di Oto E, Moskovszky LE, Foschini MP, Varga Z. Preferential expression of NY-BR-1 and GATA-3 in male breast cancer. *J Cancer Res Clin Oncol* 2018;144:199–204.
63. Gonzalez RS, Wang J, Kraus T, Sullivan H, Adams LA, Cohen C. GATA-3 expression in male and female breast cancers: comparison of clinicopathologic parameters and prognostic relevance. *Hum Pathol* 2013;44:1065–1070.
64. Liu N, KJ Johnson, CX Ma. Male breast cancer: An updated surveillance, epidemiology, and end results data analysis. *Clin Breast Cancer* 2018;18:997–1002.
65. Wang K, Wang QJ, Xiong YF, Shi Y, Yang WJ, Zhang X *et al.* Survival comparisons between early male and female breast cancer patients. *Sci Rep* 2018;11:8900.
66. Wang Y, Chen K, Yang Y, Tan L, Chen L, Zhu L *et al.* Incidence and survival outcomes of early male breast cancer: a population-based comparison with early female breast cancer. *Ann Transl Med* 2019;7:536.
67. Yadav S, Karam D, Riaz BI, Xie H, Durani U, Duma N *et al.* Male breast cancer in the United States: Treatment patterns and prognostic factors in the 21st century. *Cancer* 2020;126:26–36.

68. Pinder SE, Reis-Filho JS. Non-operative breast pathology: columnar cell lesions. *J Clin Pathol* 2007;60:1307–1312.
69. Said SM, Visscher DW, Nassar A, Frank RD, Vierkant RA, Frost MH *et al.* Flat epithelial atypia and risk of breast cancer: A Mayo cohort study. *Cancer* 2015;15:1548–1555.
70. Page DL, Dupont WD, Rogers LW, Rados MS. Atypical hyperplastic lesions of the female breast. A long-term follow-up study. *Cancer* 1985;55:2698–2708.
71. Tavassoli FA, Norris HJ. A comparison of the results of long-term follow-up for atypical intraductal hyperplasia and intraductal hyperplasia of the breast. *Cancer* 1990;1:65:518–529.
72. Page DL, Schuyler PA, Dupont WD, Jensen RA, Plummer WD Jr, Simpson JF. Atypical lobular hyperplasia as a unilateral predictor of breast cancer risk: a retrospective cohort study. *Lancet* 2003;11:361:125–129.
73. Page DL, Kidd TE Jr, Dupont WD, Simpson JF, Rogers LW. Lobular neoplasia of the breast: higher risk for subsequent invasive cancer predicted by more extensive disease. *Hum Pathol* 1991;22:1232–1239.
74. Haagensen CD, Lane N, Lattes R, Bodian C. Lobular neoplasia (so-called lobular carcinoma in situ) of the breast. *Cancer* 1978;42:737–769.
75. Fadare O, Dadmanesh F, Alvarado-Cabrero I, Snyder R, Stephen Mitchell J, Tot T *et al.* Lobular intraepithelial neoplasia [lobular carcinoma in situ] with comedo-type necrosis: A clinicopathologic study of 18 cases. *Am J Surg Pathol* 2006;30:1445–1453.
76. Masannat YA, Husain E, Roylance R, Heys SD, Carder PJ, Ali H *et al.* Pleomorphic LCIS what do we know? A UK multicenter audit of pleomorphic lobular carcinoma in situ. *Breast* 2018;38:120–124.
77. Holland R, Hendriks JH, Vebeek AL, Mravunac M, Schuurmans Stekhoven JH. Extent, distribution, and mammographic/histological correlations of breast ductal carcinoma in situ. *Lancet* 1990;335:519–522.
78. Faverly DR, Hendriks JH, Holland R. Breast carcinomas of limited extent: frequency, radiologic-pathologic characteristics, and surgical margin requirements. *Cancer* 2001;15:647–659.

79. Going JJ, Moffat DF. Escaping from Flatland: clinical and biological aspects of human mammary duct anatomy in three dimensions. *J Pathol* 2004;203:538–544.
80. Lester SC, Bose S, Chen YY, Connolly JL, Fitzgibbons PL, Members of the Cancer Committee *et al.* Protocol for the examination of specimens from patients with ductal carcinoma in situ of the breast. *Arch Pathol Lab Med* 2009;133:15–25.
81. Elston CW, Ellis IO. Pathological prognostic factors in breast cancer. The value of histological grade in breast cancer: experience from a large study with long-term follow-up. *Histopathology* 1991;19:403–410.
82. Tavassoli FA, Norris HJ. Intraductal apocrine carcinoma: a clinicopathologic study of 37 cases. *Mod Pathol* 1994;7:813–818.
83. Tan PH, Lui GG, Chiang G, Yap WM, Poh WT, Bay BH. Ductal carcinoma in situ with spindle cells: a potential diagnostic pitfall in the evaluation of breast lesions. *Histopathology* 2004;45:343–351.
84. Kawasaki T, Nakamura S, Sakamoto G, Murata S, Tsunoda-Shimizu H, Suzuki K *et al.* Neuroendocrine ductal carcinoma in situ (NE-DCIS) of the breast—comparative clinicopathological study of 20 NE-DCIS cases and 274 non-NE-DCIS cases. *Histopathology* 2008;53:288–298.
85. Guerry P, Erlandson RA, Rosen PP. Cystic hypersecretory hyperplasia and cystic hypersecretory duct carcinoma of the breast. Pathology, therapy, and follow-up of 39 patients. *Cancer* 1988;61:1611–1620.
86. Page DL, Salhany KE, Jensen RA, Dupont WD. Subsequent breast carcinoma risk after biopsy with atypia in a breast papilloma. *Cancer* 1996;78:258–266.
87. Collins LC, Carlo VP, Hwang H, Barry TS, Gown AM, Schnitt SJ. Intracystic papillary carcinomas of the breast: a reevaluation using a panel of myoepithelial cell markers. *Am J Surg Pathol* 2006;30:1002–1007.
88. Collins LC, Schnitt SJ. Papillary lesions of the breast: selected diagnostic and management issues. *Histopathology* 2008;52:20–29.
89. Carter D, Orr SL, Merino MJ. Intracystic papillary carcinoma of the breast. After mastectomy, radiotherapy or excisional biopsy alone. *Cancer* 1983;52:14–19.
90. Rakha EA, Gandhi N, Climent F, van Deurzen CH, Haider SA, Dunk L *et al.* Encapsulated papillary carcinoma of the breast: an invasive tumor with excellent prognosis. *Am J Surg Pathol* 2011;35:1093–1103.

91. Sandoval-Leon AC, Drews-Elger K, Gomez-Fernandez CR, Yepes MM, Lippman ME. Paget's disease of the nipple. *Breast Cancer Res Treat* 2013;141:1–12.
92. Zheng J, Yu J, Zhou T. Clinical characteristics of breast ductal carcinoma in situ with microinvasion: a narrative review. *J Int Med Res* 2020;48:11.
93. Liebens F, Carly B, Cusumano P, Van Beveren M, Beier B, Fastrez M *et al*. Breast cancer seeding associated with core needle biopsies: a systematic review. *Maturitas* 2009;20:62:113–123.
94. Nagi C, Bleiweiss I, Jaffer S. Epithelial displacement in breast lesions: a papillary phenomenon. *Arch Pathol Lab Med* 2005;129:1465–1469.
95. National Institute for Health and Care Excellence. *Early and locally advanced breast cancer: diagnosis and management*. Accessed November 2022. Available at: <https://www.nice.org.uk/guidance/ng101>
96. McCart Reed AE, Kalinowski L, Simpson PT, Lakhani SR. Invasive lobular carcinoma of the breast: the increasing importance of this special subtype. *Breast Cancer Res* 2021;7:23:6.
97. Canas-Marques R, Schnitt SJ. E-cadherin immunohistochemistry in breast pathology uses and pitfalls. *Histopathology* 2016;68:57–69.
98. Sullivan T, Raad RA, Goldberg S, Assaad SI, Gadd M, Smith BL *et al*. Tubular carcinoma of the breast: a retrospective analysis and review of the literature. *Breast Cancer Res Treat* 2005;93:199–205.
99. Rakha EA, Lee AH, Evans AJ, Menon S, Assad NY, Hodi Z *et al*. Tubular carcinoma of the breast: further evidence to support its excellent prognosis. *J Clin Oncol* 2010;28:99–104.
100. Yang YL, Liu BB, Zhang X, Fu L. Invasive micropapillary carcinoma of the breast: An update. *Arch Pathol Lab Med* 2016;140:799–805.
101. Hashmi AA, Munawar S, Rehman N, Ahmed O, Islam S, Asghar IA *et al*. Invasive papillary carcinoma of the breast: Clinicopathological features and hormone receptor profile. *Cureus* 2021;22:13:13480.
102. D'Arcy C, Quinn CM. Apocrine lesions of the breast: part 2 of a two-part review. Invasive apocrine carcinoma, the molecular apocrine signature and utility of immunohistochemistry in the diagnosis of apocrine lesions of the breast. *J Clin Pathol* 2019;72:7–11.

103. Vranic S, Gatalica Z. An update on the molecular and clinical characteristics of apocrine carcinoma of the breast. *Clin Breast Cancer* 2022;22:e576–e585.
104. McCart Reed AE, Kalaw E, Nones K, Bettington M, Lim M, Bennett J *et al.* Phenotypic and molecular dissection of metaplastic breast cancer and the prognostic implications. *J Pathol* 2019;247:214–227.
105. Soo K, Tan PH. Low-grade adenosquamous carcinoma of the breast. *J Clin Pathol* 2013;16:506–511.
106. Victoor J, Bourgain C, Vander Borght S, Vanden Bempt I, De Rop C, Floris G. Fibromatosis-like metaplastic carcinoma: a case report and review of the literature. *Diagn Pathol* 2020;3:15:20.
107. Zhao Y, Gong X, Li N, Zhu B, Yu D, Jin X. Fibromatosis-like metaplastic carcinoma of breast: a challenge for clinicopathologic diagnosis. *Int J Clin Exp Pathol* 2018;11:3691–3696.
108. Gobbi H, Simpson JF, Borowsky A, Jensen RA, Page DL. Metaplastic breast tumors with a dominant fibromatosis-like phenotype have a high risk of local recurrence. *Cancer* 1999;85:2170–2182.
109. Rakha EA, Coimbra ND, Hodi Z, Juneinah E, Ellis IO, Lee AH. Immunoprofile of metaplastic carcinomas of the breast. *Histopathology* 2017;70:975–985.
110. Nayak A, Wu Y, Gilcrease MZ. Primary squamous cell carcinoma of the breast: predictors of locoregional recurrence and overall survival. *Am J Surg Pathol* 2013;37:867–873.
111. Tse GM, Tan PH, Putti TC, Lui PCW, Chaiwun B, Law BKB. Metaplastic carcinoma of the breast: a clinicopathological review. *J Clin Pathol* 2006;59:1079–1083.
112. Koufopoulos N, Kokkali S, Antoniadou F, Dimas DT, Missitzis IL. Matrix-producing breast carcinoma: A rare subtype of metaplastic breast carcinoma. *Cureus* 2019;22:11:5188.
113. Foschini MP, Morandi L, Asioli S, Giove G, Corradini AG, Eusebi V. The morphological spectrum of salivary gland type tumours of the breast. *Pathology* 2017; 49:215–227.
114. Cserni G, Quinn CM, Foschini MP, Bianchi S, Callagy G, Chmielik E *et al.* Triple-negative breast cancer histological subtypes with a favourable prognosis. *Cancers (Basel)* 2021;14:5694.

115. Makretsov N, He M, Hayes M, Chia S, Horsman DE, Sorensen PH *et al.* A fluorescence in situ hybridization study of ETV6-NTRK3 fusion gene in secretory breast carcinoma. *Genes Chromosomes Cancer* 2004;40:152–157.
116. Alsadoun N, MacGrogan G, Truntzer C, Lacroix-Triki M, Bedgedjian I, Koeb MH, *et al.* Solid papillary carcinoma with reverse polarity of the breast harbors specific morphologic, immunohistochemical and molecular profile in comparison with other benign or malignant papillary lesions of the breast: a comparative study of 9 additional cases. *Mod Pathol* 2018;31:1367–1380.
117. Pareja F, D'Alfonso TM. Neuroendocrine neoplasms of the breast: A review focused on the updated World Health Organization (WHO) 5th Edition morphologic classification. *Breast J* 2020;26:1160–1167
118. Rakha EA, Reis-Filho JS, Baehner F, Dabbs DJ, Decker T, Eusebi V *et al.* Breast cancer prognostic classification in the molecular era: the role of histological grade. *Breast Cancer Res* 2010;12:207.
119. Rakha EA, El-Sayed ME, Menon S, Green AR, Lee AHS, Ellis IO. Histologic grading is an independent prognostic factor in invasive lobular carcinoma of the breast. *Breast Cancer Res Treat* 2008;111:121–127.
120. Dunne B, Going JJ. Scoring nuclear pleomorphism in breast cancer. *Histopathology* 2001;39:259–265.
121. Katayama A, Toss SM, Parkin M, Sano T, Oyama T, Quinn MC *et al.* Nuclear morphology in breast lesions: refining its assessment to improve diagnostic concordance. *Histopathology* 2022;80:315–528.
122. Ibrahim A, Lashen A, Toss M, Mihai R, Rakha E. Assessment of mitotic activity in breast cancer: revisited in the digital pathology era. *J Clin Pathol* 2022;75:365–372.
123. Verhoeven D, Bourgeois N, Derde MP, Kaufman L, Buyskens N. Comparison of cell growth in different parts of breast cancers. *Histopathology* 1990;17:505–509.
124. Connor AJM, Pinder SE, Elston CW, Bell JA, Wencyk P, Robertson JFR *et al.* Intratumoural heterogeneity of proliferation in invasive breast carcinoma evaluated with MIB1 antibody. *Breast* 1997;6:171–176.
125. Knuttel FM, Menezes GL, van Diest PJ, Witkamp AJ, van den Bosch MA, Verkooijen HM. Meta-analysis of the concordance of histological grade of breast cancer between core needle biopsy and surgical excision specimen. *Br J Surg* 2016;103:644–655.

126. Harris GC, Denley HE, Pinder SE, Lee AH, Ellis IO, Elston CW *et al.* Correlation of histologic prognostic factors in core biopsies and therapeutic excisions of invasive breast carcinoma. *Am J Surg Pathol* 2003;27:11–15.
127. Pinder SE, Ellis IO, Galea M, O'Rourke S, Blamey RW, Elston CW. Pathological prognostic factors in breast cancer. III. Vascular invasion: relationship with recurrence and survival in a large study with long-term follow-up. *Histopathology* 1994;24:41–47.
128. Lee AH, Pinder SE, Macmillan RD, Mitchell M, Ellis IO, Elston CW *et al.* Prognostic value of lymphovascular invasion in women with lymph node negative invasive breast carcinoma. *Eur J Cancer* 2006;42:357–362.
129. Rakha EA, Martin S, Lee AH, Morgan D, Pharoah PD, Hodi Z *et al.* The prognostic significance of lymphovascular invasion in invasive breast carcinoma. *Cancer* 2012;118:3670–3680.
130. Braun M, Flucke U, Debald M, Walgenbach-Bruenagel G, Walgenbach K-J, Holler T *et al.* Detection of lymphovascular invasion in early breast cancer by D2-40 (podoplanin): a clinically useful predictor for axillary lymph node metastases. *Breast Cancer Res Treat* 2008;112:503–511.
131. Aziz S, Wik E, Knutsvik G, Klingen TA, Chen Y, Davidsen B *et al.* Extra-nodal extension is a significant prognostic factor in lymph node positive breast cancer. *PLoS One* 2017;15:0171853.
132. Galea MH, Blamey RW, Elston CE, Ellis IO. The Nottingham Prognostic Index in primary breast cancer. *Breast Cancer Res Treat* 1992;22:207.
133. Cserni G, Bianchi S, Vezzosi V, van Diest P, van Deurzen C, Sejbien I *et al.* Variations in sentinel node isolated tumour cells/micrometastasis and non-sentinel node involvement rates according to different interpretations of the TNM definitions. *Eur J Cancer* 2008;44:2185–2191.
134. Mascarel de I, MacGrogan G, Debled M, Brouste V, Mauriac L. Distinction between isolated tumor cells and micrometastases in breast cancer: is it reliable and useful? *Cancer* 2008;112:1672–1678.
135. Wong SM, Almana N, Choi J, Hu J, Gagnon H, Natsuhara K *et al.* Prognostic significance of residual axillary nodal micrometastases and isolated tumor cells after neoadjuvant chemotherapy for breast cancer. *Ann Surg Oncol* 2019;26:3502–3509.

136. Provenzano E, Bossuyt V, Viale G, Cameron D, Badve S, Denkert C *et al.* Standardization of pathologic evaluation and reporting of postneoadjuvant specimens in clinical trials of breast cancer: recommendations from an international working group. *Mod Pathol* 2015;28:1185–1201.
137. Pinder SE, Provenzano E, Earl H, Ellis IO. Laboratory handling and histology reporting of breast specimens from patients who have received neoadjuvant chemotherapy. *Histopathology* 2007;50:409–417.
138. Cortazar P, Zhang L, Untch M, Mehta K, Costantino JP, Wolmark N *et al.* Pathological complete response and long-term clinical benefit in breast cancer: the CTNeoBC pooled analysis. *Lancet* 2014;384:164–172.
139. Von Minckwitz G, Untch M, Blohmer JU, Costa SD, Eidtmann H, Fasching PA *et al.* Definition and impact of pathologic complete response on prognosis after neoadjuvant chemotherapy in various intrinsic breast cancer subtypes. *J Clin Oncol* 2012;30:1796–1804.
140. Cortazar P, Geyer Jr C. Pathological complete response in neoadjuvant treatment of breast cancer. *Ann Surg Oncol* 2015;22:1441–1446.
141. Chevallier B, Roche H, Olivier JP, Chollet P, Hurteloup P. Inflammatory breast cancer. Pilot study of intensive induction chemotherapy (FEC-HD) results in a high histologic response rate. *Am J Clin Oncol* 1993;16:223–228.
142. Sataloff DM, Mason BA, Prestipino AJ, Seinige UL, Lieber CP *et al.* Pathologic response to induction chemotherapy in locally advanced carcinoma of the breast: a determinant of outcome. *J Am Coll Surg* 1995;180:297–306.
143. Ogston KN, Miller ID, Payne S, Hutcheon AW, Sarkar TK, Smith I *et al.* A new histological grading system to assess response of breast cancers to primary chemotherapy: prognostic significance and survival. *Breast* 2003;12:320–327.
144. Symmans WF, Peintinger F, Hatzis C, Rajan R, Kuerer H, Valero V *et al.* Measurement of residual breast cancer burden to predict survival after neoadjuvant chemotherapy. *J Clin Oncol* 2007;25:4414–4422.
145. The University of Texas MD Anderson Cancer Center. *Calculators*. Accessed February 2022. Available at: <http://www3.mdanderson.org/app/medcalc/index.cfm?pagename=jsconvert3;>

146. Naidoo K, Parham DM, Pinder SE. An audit of residual cancer burden reproducibility in a UK context. *Histopathology* 2017;70:217–222.
147. Hamy AS, Lam GT, Laas E, Darrigues L, Balezeau T, Guerin J *et al.* Lymphovascular invasion after neoadjuvant chemotherapy is strongly associated with poor prognosis in breast carcinoma. *Breast Cancer Res Treat* 2018;169:295–304.
148. Davies C, Godwin J, Gray R, Clarke M, Cutter D, Darby S *et al.* Relevance of breast cancer hormone receptors and other factors to the efficacy of adjuvant tamoxifen: patient-level meta-analysis of randomised trials. *Lancet* 2011;378:771–784.
149. Forbes JF, Sestak I, Howell A, Bonanni B, Bundred N, Levy C *et al.* Anastrozole versus tamoxifen for the prevention of locoregional and contralateral breast cancer in postmenopausal women with locally excised ductal carcinoma in situ (IBIS-II DCIS): a double-blind, randomised controlled trial. *Lancet* 2016;387:866–873.
150. Yan Y, Zhang L, Tan L, Ma X, Zhang Y, Shao S *et al.* Endocrine therapy for ductal carcinoma in situ (DCIS) of the breast with breast conserving surgery (BCS) and radiotherapy (RT): a meta-analysis. *Pathol Oncol Res* 2020;26:521–531.
151. Cuzick J, Sestak I, Pinder SE, Ellis IO, Forsyth S, Bundred NJ *et al.* Effect of tamoxifen and radiotherapy in women with locally excised ductal carcinoma in situ: long-term results from the UK/ANZ DCIS trial. *Lancet Oncol* 2011;12:21–29.
152. Harvey JM, Clark GM, Osborne CK, Allred DC. Estrogen receptor status by immunohistochemistry is superior to the ligand-binding assay for predicting response to adjuvant endocrine therapy in breast cancer. *J Clin Oncol* 1999;17:1474–1481.
153. National Institute for Health and Care Excellence. *Diagnostic assessment and adjuvant therapy learning*. Available at: <https://www.nice.org.uk/guidance/ng101/chapter/recommendations#diagnostic-assessment-and-adjuvant-therapy-planning>
154. Hammond MEH, Hayes DF, Dowsett M, Allred DC, Hagerty KL, Badve S *et al.* American Society of Clinical Oncology/College of American Pathologists guideline recommendations for immunohistochemical testing of estrogen and progesterone receptors in breast cancer. *Arch Pathol Lab Med* 2010;134:907–922.
155. Allison KH, Hammond MEH, Dowsett M, Mckernin SE, Carey LA, Fitzgibbons PL *et al.* Estrogen and progesterone receptor testing in breast cancer: ASCO/CAP guideline update. *J Clin Oncol* 2020;38:1346–1366.

156. Hodi Z, Chakrabarti J, Lee AH, Ronan JE, Elston CW, Cheung KL *et al*. The reliability of assessment of oestrogen receptor expression on needle core biopsy specimens of invasive carcinomas of the breast. *J Clin Pathol* 2007;60:299–302.
157. Arnedos M, Nerurkar A, Osin P, A'Hern R, Smith IE, Dowsett M. Discordance between core needle biopsy (CNB) and excisional biopsy (EB) for estrogen receptor (ER), progesterone receptor (PgR) and HER2 status in early breast cancer (EBC). *Ann Oncol* 2009;20:1948–1952.
158. Bensch F, Gerritse S, van Helden EJ, Boon E, Angus L, Overbosch J *et al*. Decalcification of breast cancer bone metastases with EDTA does not affect ER, PR, and HER2 results. *Am J Surg Pathol* 2019;43:1355–1360.
159. Washburn E, Tang X, Caruso C, Walls M, Han B. Effect of EDTA decalcification on estrogen receptor and progesterone receptor immunohistochemistry and HER2/neu fluorescence in situ hybridization in breast carcinoma. *Hum Pathol* 2021;117:108–114.
160. Rhodes A, Jasani B, Barnes DM, Bobrow LG, Miller KD. Reliability of immunohistochemical demonstration of oestrogen receptors in routine practice: interlaboratory variance in the sensitivity of detection and evaluation of scoring systems. *J Clin Pathol* 2000;53:125–130.
161. Rhodes A, Jasani B, Balaton AJ, Barnes DM, Anderson E, Bobrow LG *et al*. Study of interlaboratory reliability and reproducibility of estrogen and progesterone receptor assays in Europe. Documentation of poor reliability and identification of insufficient microwave antigen retrieval time as a major contributory element of unreliable assays. *Am J Clin Pathol* 2001;115:44–58.
162. Ibrahim M, Dodson A, Barnett S, Fish D, Jasani B, Miller K. Potential for false-positive staining with a rabbit monoclonal antibody to progesterone receptor (SP2): findings of the UK National External Quality Assessment Scheme for Immunocytochemistry and FISH highlight the need for correct validation of antibodies on introduction to the laboratory. *Am J Clin Pathol* 2008;129:398–409.
163. UK NEQAS International Quality Expertise. *Immunohistochemistry best methods database*. Accessed February 2022. Available at: <https://ukneqasiccish.org/best-methods/>

164. Fitzgibbons PL, Murphy DA, Hammond ME, Allred DC, Valenstein PN. Recommendations for validating estrogen and progesterone receptor immunohistochemistry assays. *Arch Pathol Lab Med* 2010;134:930–935.
165. McCarty KS Jr, Miller LS, Cox EB, Konrath J, McCarty KS Sr. Estrogen receptor analyses. Correlation of biochemical and immunohistochemical methods using monoclonal antireceptor antibodies. *Arch Pathol Lab Med* 1985;109:716–721.
166. Dodson A, Parry S, Ibrahim M, Bartlett JM, Pinder S, Dowsett M *et al.* Breast cancer biomarkers in clinical testing: analysis of a UK national external quality assessment scheme for immunocytochemistry and in situ hybridisation database containing results from 199 300 patients. *J Pathol Clin Res* 2018;4:262–273.
167. Muftah AA, Aleskandarany M, Sonbul SN, Nolan CC, Diez Rodriguez M, Caldas C *et al.* Further evidence to support bimodality of oestrogen receptor expression in breast cancer. *Histopathol* 2017;70:456–465.
168. Iwamoto T, Booser D, Valero V, Murray LJ, Koenig K, Hatzis C *et al.* Estrogen receptor (ER) mRNA and ER-related gene expression in breast cancers that are 1% to 10% ER-positive by immunohistochemistry. *J Clin Oncol* 2012;30:729–734.
169. Sanford RA, Song J, Gutierrez-Barrera AM, Profato J, Woodson A, Litton JK *et al.* High incidence of germline BRCA mutation in patients with ER low-positive/PR low-positive/HER-2 neu negative tumors. *Cancer* 2015;121:3422–3427.
170. Reisenbichler ES, Lester SC, Richardson AL, Dillon AD, Brock EJ, Ly A. Interobserver concordance in implementing the 2010 ASCO/CAP recommendations for reporting ER in breast carcinomas: a demonstration of the difficulties of consistently reporting low levels of ER expression by manual quantification. *Am J Clin Pathol* 2013;140:487–494.
171. Slamon DJ, Godolphin W, Jones LA, Holt JA, Wong SG, Keith DE *et al.* Studies of the HER-2/neu proto-oncogene in human breast and ovarian cancer. *Science* 1989;244:707–712.
172. Cameron D, Piccart-Gebhart MJ, Gelber RD, Procter M, Goldhirsch A, de Azambuja E *et al.* 11 years' follow-up of trastuzumab after adjuvant chemotherapy in HER2-positive early breast cancer: final analysis of the HERceptin Adjuvant (HERA) trial. *Lancet* 2017;25:389:1195–1205.

173. Swain SM, Baselga J, Kim SB, Ro J, Semiglazov V, Campone M *et al.* Pertuzumab, trastuzumab, and docetaxel in HER2-positive metastatic breast cancer. *N Engl J Med* 2015;19:372:724–734.
174. Huober J, Holmes E, Baselga J, de Azambuja E, Untch M, Fumagalli D *et al.* Survival outcomes of the NeoALTTO study (BIG 1-06): updated results of a randomised multicenter phase III neoadjuvant clinical trial in patients with HER2-positive primary breast cancer. *Eur J Cancer* 2019;118:169–177.
175. Ali S, Hendry J, Le D, Mondal PK, Sami A, Chalchal H *et al.* Efficacy of adjuvant trastuzumab in women with HER2-positive T1a or bN0M0 breast cancer: a population-based cohort study. *Sci Rep* 2022;20:1068.
176. Rakha EA, Tan PH, Quinn C *et al.* UK recommendations for HER2 assessment in breast cancer: An update. *J Clin Pathol* 2023;76:217–227
177. Lee AH, Key HP, Bell JA, Hodi Z, Ellis IO. Concordance of HER2 status assessed on needle core biopsy and surgical specimens of invasive carcinoma of the breast. *Histopathology* 2012;60:880–884.
178. Greer LT, Rosman M, Mylander WC, Hooke J, Kovatich A, Sawyer K *et al.* Does breast tumor heterogeneity necessitate further immunohistochemical staining on surgical specimens? *J Am Coll Surg* 2013;216:239–251.
179. Durgapal P, Mathur SR, Kalamuddin M, Datta Gupta S, Parshad R, Julka PK *et al.* Assessment of Her-2/neu status using immunocytochemistry and fluorescence in situ hybridization on fine-needle aspiration cytology smears: Experience from a tertiary care centre in India. *Diagn Cytopathol* 2013;42:726–731.
180. Schrijver WA, van der Groep P, Hoefngel LD, Hoeve Ter DN, Peeters T, Moelans BC *et al.* Influence of decalcification procedures on immunohistochemistry and molecular pathology in breast cancer. *Mod Pathol* 2016;29:1460–1470.
181. Lundgaard Hansen B, Winther H, Moller K. Excessive section drying of breast cancer tissue prior to deparaffinisation and antigen retrieval causes a loss in HER2 immunoreactivity. *UKNEQAS Immunocytochemistry J* 2008;6:76:117–122.
182. Press MF, Sauter G, Bernstein L, Villalobos IE, Mirlacher M, Zhou JY *et al.* Diagnostic evaluation of HER-2 as a molecular target: an assessment of accuracy and reproducibility of laboratory testing in large, prospective, randomized clinical trials. *Clin Cancer Res* 2005;11:6598–6607.

183. Pauletti G, Dandekar S, Rong H, Ramos L, Peng H, Seshadri R *et al.* Assessment of methods for tissue-based detection of the HER-2/neu alteration in human breast cancer: a direct comparison of fluorescence in situ hybridization and immunohistochemistry. *J Clin Oncol* 2000;18:3651–3664.
184. Rakha EA, Pinder SE, Bartlett JM, Ibrahim M, Starczynski J, Carder PJ *et al.* National Coordinating Committee for Breast Pathology. Updated UK recommendations for HER2 assessment in breast cancer. *J Clin Pathol* 2015;68:93–99.
185. Wolff AC, Hammond MEH, Allison KH, Harvey BE, Mangu PB, Bartlett JMS *et al.* Human epidermal growth factor receptor 2 testing in breast cancer: American Society of Clinical Oncology/College of American Pathologists clinical practice guideline focused update. *J Clin Oncol* 2018;36:2105–2122.
186. Rakha EA, Miligy IM, Quinn CM, Provenzano E, Shaaban AM, Marchiò C *et al.* Retrospective observational study of HER2 immunohistochemistry in borderline breast cancer patients undergoing neoadjuvant therapy, with an emphasis on Group 2 (HER2/CEP17 ratio ≥ 2.0 , HER2 copy number < 4.0 signals/cell) cases. *Br J Cancer* 2021;124:1836–1842.
187. Hanna WM, Rüschoff J, Bilous M, Coudry RA, Dowsett M, Osamura RY *et al.* HER2 in situ hybridization in breast cancer: clinical implications of polysomy 17 and genetic heterogeneity. *Mod Pathol* 2014;27:4–18.
188. Bartlett AI, Starczynski J, Robson T, Maclellan A, Campbell FM, van de Velde CJ *et al.* Heterogeneous HER2 gene amplification: impact on patient outcome and a clinically relevant definition. *Am J Clin Pathol* 2011;136:266–274.
189. Shaaban AM, Purdie CA, Bartlett JM, Stein RC, Lane S, Francis A *et al.* HER2 testing for breast carcinoma: recommendations for rapid diagnostic pathways in clinical practice. *J Clin Pathol* 2014;67:161–167.

Appendix A RCPATH and NHSBSP breast pathology synoptic proforma template for surgically resected lesions, including dataset and commonly used optional items

This template is provided as an example proforma for use for synoptic reporting of breast screening and symptomatic breast disease-related specimens. It can be separated into separate documents for reporting benign, in situ carcinoma and invasive carcinoma-related cases and can be adapted to suit local needs and protocols (but must include the RCPATH dataset, see Appendix B).

Sections in italics are regarded as optional (non-core).

Pathology report

Patient's identifier:

Date reported: Report number:

Pathologist: Laboratory:

Surgical specimen(s)

Side: Right Left

Specimen type:

Wide local excision Excision biopsy Localisation specimen Segmental excision

Mastectomy Subcutaneous mastectomy Nipple sparing mastectomy

Re-excision Further margins (including cavity shaves/bed biopsies)

Microdochectomy/microductectomy Total duct excision/Hadfield procedure

Axillary procedure:

None Sentinel node biopsy Axillary sampling Axillary LN level I

Axillary LN level II Axillary LN level III

*Other

Specimen weight (g)

*Comment/further macroscopic *description:

*Specimen radiograph seen: Yes No

*Mammographic abnormality: Yes No Unsure

*Site of previous core biopsy seen Yes No

*Histological calcification Absent Benign Malignant Benign and malignant

Benign lesions

Columnar cell change Complex sclerosing lesion/radial scar Fibroadenoma

Fibrocystic change Multiple papillomas Papilloma (single)

Periductal mastitis/duct ectasia Sclerosing adenosis Solitary cyst

Other Specify other.....

Epithelial proliferation

Not present Present without atypia

Flat epithelial atypia Present with atypia (ductal) Present with atypia (lobular)

Malignant lesions

Malignant in situ lesion: Absent Present

In situ components: DCIS LCIS

DCIS grade: High Intermediate Low Not assessable

DCIS growth pattern: Solid Cribriform Papillary Micropapillary

Apocrine Flat

Other Specify other.....

DCIS necrosis: Present Absent

Inflammation: Present Absent

DCIS size (mm):

Paget's disease: Present Absent

Microinvasion: Present Absent

LCIS type: Classical Pleomorphic Florid

LCIS size mm (for pleomorphic LCIS):

Invasive carcinoma Present Absent

Size and extent

Tumour size (mm):

Whole tumour size (mm):

Disease extent: Localised Multiple invasive foci Not assessable

Invasive tumour type Pure (tick 1 box below) Mixed (tick all components present below)

Tubular/cribriform Lobular Mucinous Invasive carcinoma NST Micropapillary

Other Other type/component:

Histological grade 1 2 3 Not assessable

**Components (optional):*

Tubule formation 1 2 3 *Not assessable*

Nuclear pleomorphism 1 2 3 *Not assessable*

Mitoses 1 2 3 *Not assessable*

Lymphovascular invasion Present Absent Possible

Lymph node stage

Sentinel/axillary nodes present: No Yes

Total present:

Total positive

Total with ITCs:..... Size of metastasis :mm

**Extracapsular spread:* Present Not identified

For single node positive: Macrometastasis Micrometastasis

Size of metastasis: mm

Other nodes present: No Yes Site:

Total present:

Total positive:.....

For single node positive: Macrometastasis Micrometastasis

**Status of perinodal fat: involved, not involved*

**Summary lymph node stage:*

1 = Node negative 2 = 1–3 nodes positive 3 = 4 or more nodes positive

Modifications for post-neoadjuvant therapy cases (in addition to standard dataset items)

Post-therapy lymph node stage

Axillary nodes:

Total present:

Total positive:

Total showing treatment response but no tumour cells:

Other nodes: Site:

Total present:

Total positive:.....

Total showing treatment response but no tumour cells:

Evidence of treatment response in the metastases: Present Absent

Final classification of chemotherapy response

Breast disease response:

Lymph node response:

TNM stage

T stage: pTis pT1mi pT1a pT1b pT1c pT2 pT3 pT4a pT4b
pT4c pT4d Cannot be assessed

N stage: pN0 pN1mi pN1a pN1b pN1c pN2a pN2b pN3a
pN3c Cannot be assessed

M stage: pM1 Cannot be assessed

Note: Add suffix 'y' to TNM codes for post-neoadjuvant therapy treated cases

Excision status

Distance from each margin (mm)

Invasive

Superior..... Inferior Medial Lateral

Deep Superficial Nipple margin.....

In situ (DCIS, pleomorphic/florid LCIS)

Superior Inferior..... Medial Lateral
Deep Superficial Nipple margin

Receptor status

Oestrogen receptor status: Positive ($\geq 1\%$) Negative ($< 1\%$) Low positive (1–10%)

% positive tumour cells =

Average intensity of staining = Weak Moderate Strong

*Allred score (0–8):

*H score (0–300):

*On-slide positive control material: Present Absent

*Progesterone receptor status: Positive ($\geq 1\%$) Negative ($< 1\%$)

*% positive tumour cells =

*Average intensity of staining = Weak Moderate Strong

*Allred score (0–8):

*H score (0–300):

*On-slide positive control material: Present Absent

HER2 IHC score: 0 Negative 1+ Negative 2+ Equivocal 3+ Positive

*ISH ratio:

Status: Amplified Non-amplified Borderline Not performed

*HER2 copy no: Chromosome 17 no:

Final HER2 status: Positive Negative

*Optional:

Proliferation (Ki67) index:

TNM stage:

SNOMED codes

T:

M:

Key

*Non-core data item.

Appendix B RCPATH and NHSBSP breast pathology synoptic proforma template for surgically resected lesions, including dataset and commonly used optional items in list format

| Element name | Values | Implementation comments | COSD v9 |
|---|--|-------------------------|--|
| Is there a history of neo-adjuvant therapy? | Single selection value list: <ul style="list-style-type: none"> • Yes • No • Not known | | pCR1000 |
| Side | Single selection value list: <ul style="list-style-type: none"> • Right • Left | | pCR0820 <ul style="list-style-type: none"> • Right = R • Left = L |
| Specimen type | Multiple selection value list: <ul style="list-style-type: none"> • Wide local excision • Excision biopsy • Localisation specimen • Segmental excision • Mastectomy • Subcutaneous mastectomy • Nipple-sparing mastectomy • Re-excision • Further margins (including cavity shaves/bed biopsies) • Microdochectomy/microductectomy | | pCR0760 <ul style="list-style-type: none"> • Wide local excision = EX • Excision biopsy = EX • Localisation specimen = BU • Segmental excision = EX • Mastectomy = RE • Subcutaneous mastectomy = RE |

| | | | |
|---------------------------------|---|---|---|
| | <ul style="list-style-type: none"> • Total duct excision/Hadfield's procedure • Sentinel node biopsy • Axillary sampling • Axillary LN level I • Axillary LN level II • Axillary LN level III • Other* | | <ul style="list-style-type: none"> • Nipple-sparing Mastectomy = RE • Re-excision = FE • Further margins (including cavity shaves/bed biopsies) = 99 • Microdochestomy/microductectomy = 99 • Total duct excision/Hadfield's procedure = EX • Sentinel node biopsy = 99 • Axillary sampling = 99 • Axillary LN level I = 99 • Axillary LN level II = 99 • Axillary LN level III = 99 • Other* = 99 |
| Specimen type, other (specify)* | Free text | Only applicable if 'Specimen type, Other' is selected | |

| | | | |
|------------------------------------|---|--|--|
| Specimen weight | Weight in g | | |
| Specimen radiograph seen* | <ul style="list-style-type: none"> • Yes • No | | |
| Mammographic abnormality* | <ul style="list-style-type: none"> • Yes • No • Unsure | | |
| Site of previous core biopsy seen* | <ul style="list-style-type: none"> • Yes • No | | |
| Histological calcification* | <ul style="list-style-type: none"> • Absent • Benign • Malignant • Benign and malignant | | |
| Benign lesions | <ul style="list-style-type: none"> • Columnar cell change • Complex sclerosing lesion/radial scar • Fibroadenoma • Fibrocystic change • Multiple papillomas • Papilloma (single) • Periductal mastitis/duct ectasia • Sclerosing adenosis • Solitary cyst • Other (Specify other) | | |
| Epithelial proliferation | <ul style="list-style-type: none"> • Not present • Present without atypia • Flat epithelial atypia • Present with atypia (ductal) • Present with atypia (lobular) | | |
| DCIS | Single selection value list: | | |

| | | | |
|----------------------------|---|--|---------|
| | <ul style="list-style-type: none"> • Present • Absent | | |
| DCIS grade | Single selection value list: <ul style="list-style-type: none"> • High • Intermediate • Low • Cannot be assessed | | pBR4160 |
| DCIS growth pattern | <ul style="list-style-type: none"> • Solid • Cribriform • Papillary • Micropapillary • Apocrine • Flat • Other (Specify other) | | |
| DCIS necrosis | <ul style="list-style-type: none"> • Present • Absent | | |
| Inflammation | <ul style="list-style-type: none"> • Present • Absent | | |
| DCIS size | Size in mm | | pBR4180 |
| Paget's disease | <ul style="list-style-type: none"> • Present • Absent | | |
| Microinvasion | <ul style="list-style-type: none"> • Present • Absent | | |
| LCIS | Single selection value list: <ul style="list-style-type: none"> • Present • Not identified | | |
| LCIS type | <ul style="list-style-type: none"> • Classical • Pleomorphic • Florid | | |
| DCIS/pleomorphic LCIS size | Size in mm | | pBR4180 |

| | | | |
|---|---|---|--|
| Invasive carcinoma | <ul style="list-style-type: none"> • Present • Absent | | |
| Invasive tumour size | Size in mm | | |
| Whole tumour (invasive + DCIS or pleomorphic LCIS) size | Size in mm | | pBR4190 |
| Disease extent | Single selection value list: <ul style="list-style-type: none"> • Localised • Multiple invasive foci • Cannot be assessed | | |
| Invasive tumour type | Single selection value list: <ul style="list-style-type: none"> • Pure • Mixed | | |
| Invasive tumour type, components | Multiple selection value list: <ul style="list-style-type: none"> • Tubular/cribriform • Lobular • Mucinous • Invasive carcinoma NST • Micropapillary • Other | Single selection value list if 'Pure' selected for invasive tumour type | |
| Invasive tumour type, components, other | Free text | Only applicable if 'Invasive tumour type, components Other' is selected | |
| Histological grade | Single selection value list: <ul style="list-style-type: none"> • 1 • 2 • 3 • Cannot be assessed | | pCR0860 <ul style="list-style-type: none"> • 1 = G1 • 2 = G2 • 3 = G3 |

| | | | |
|--|---|---|--|
| | | | <ul style="list-style-type: none"> Cannot be assessed = GX |
| Lymphovascular invasion | Single selection value list: <ul style="list-style-type: none"> Present Absent Possible | | pCR0870 <ul style="list-style-type: none"> Present = YU Absent = NU Possible = UU |
| Axillary nodes, total present | Integer | | |
| Axillary nodes, total positive | Integer | | |
| Axillary nodes, for single node positive | Single selection value list: <ul style="list-style-type: none"> Macrometastasis Micrometastasis Not applicable | Macrometastasis and micrometastasis only selectable if 'Axillary nodes, total positive = 1' | pBR4200 <ul style="list-style-type: none"> Macrometastasis = 4 Micrometastasis = 2 Not applicable = 9 |
| Axillary nodes, for node negative: ITCs | Single selection value list: <ul style="list-style-type: none"> Present Not identified | | |
| Other nodes, site | Free text | | |
| Other nodes, total present | Integer | | |
| Other nodes, total positive | Integer | | |
| Other nodes, for single node positive | Single selection value list: <ul style="list-style-type: none"> Macrometastasis Micrometastasis Not applicable | Macrometastasis and micrometastasis only selectable if 'Other nodes, total positive = 1' | |

| | | | |
|--|---|--|--|
| Axillary nodes, for node negative: ITCs | Single selection value list: <ul style="list-style-type: none"> • Present • Not identified | | |
| Summary lymph node stage | Single selection value list: <ul style="list-style-type: none"> • 1 • 2 • 3 | | |
| Residual invasive tumour size | Size in mm | | |
| Whole residual tumour (invasive + DCIS or pleomorphic LCIS) size | Size in mm | | |
| Residual disease extent | Single selection value list: <ul style="list-style-type: none"> • Localised residual tumour • Multiple residual invasive foci • Cannot be assessed | | |
| Residual invasive tumour type | Single selection value list: <ul style="list-style-type: none"> • Pure • Mixed • Not applicable (no residual invasive tumour) | | |
| Residual invasive tumour type, components | Multiple selection value list: <ul style="list-style-type: none"> • Tubular/cribriform • Lobular • Mucinous • Invasive carcinoma NST • Micropapillary • Other | Single selection value list if 'Pure' selected for residual invasive tumour type. Not applicable if 'Residual invasive tumour | |

| | | | |
|--|--|---|--|
| | <ul style="list-style-type: none"> • Not applicable | type' is 'Not applicable'. | |
| Residual invasive tumour type, components, other | Free text | Only applicable if 'Residual invasive tumour type, components Other' is selected. | |
| Residual tumour histological grade | Single selection value list: <ul style="list-style-type: none"> • 1 • 2 • 3 • Cannot be assessed | | |
| Residual DCIS | Single selection value list: <ul style="list-style-type: none"> • Present • Absent | | |
| Residual DCIS grade | Single selection value list: <ul style="list-style-type: none"> • High • Intermediate • Low • Cannot be assessed | | |
| Residual LCIS | Single selection value list: <ul style="list-style-type: none"> • Present • Not identified | | |
| Residual DCIS/ pleomorphic LCIS size | Size in mm | | |
| Residual Paget's disease | Single selection value list: <ul style="list-style-type: none"> • Present • Not identified • Cannot be assessed | | |

| | | | |
|---|---|--|--|
| Residual microinvasion | Single selection value list: <ul style="list-style-type: none"> • Present • Not identified | | |
| Residual lymphovascular invasion | Single selection value list: <ul style="list-style-type: none"> • Present • Not identified • Uncertain | | |
| Post-therapy axillary nodes, total present | Integer | | |
| Post-therapy axillary nodes, total positive | Integer | | |
| Post-therapy axillary nodes, total showing treatment response but no tumour cells | Integer | | |
| Post therapy other nodes, site | Free text | | |
| Post-therapy other nodes, total present | Integer | | |
| Other nodes, total positive | Integer | | |
| Post-therapy other nodes, total showing treatment response but no tumour cells | Integer | | |
| Evidence of treatment | Single selection value list: <ul style="list-style-type: none"> • Present | | |

| | | | |
|------------------------|---|--|---------|
| response in metastases | <ul style="list-style-type: none"> • Absent | | |
| T stage | <p>Single selection value list:</p> <ul style="list-style-type: none"> • TX • T0 • Tis (DCIS) • Tis (LCIS) • Tis (Paget's) • T1mi • T1a • T1b • T1c • T2 • T3 • T4a • T4b • T4c • T4d • pTX • pT0 • pTis (DCIS) • pTis (LCIS) • pTis (Paget's) • ypT1mi • ypT1a • ypT1b • ypT1c • ypT2 • ypT3 • ypT4a • ypT4b | | pCR0910 |

| | | | |
|---------|---|--|---------|
| | <ul style="list-style-type: none"> • ypT4c • ypT4d | | |
| N stage | <p>Single selection value list:</p> <ul style="list-style-type: none"> • pNX • pN0 • pN0(i-) • pN0(i+) • pN0(mol-) • pN0(mol+) • pN1mi • pN1a • pN1b • pN1c • pN2a • pN2b • pN3a • pN3b • pN3c • ypNX • ypN0 • ypN0(i-) • ypN0(i+) • ypN0(mol-) • ypN0(mol+) • ypN1mi • ypN1a • ypN1b • pN1c • pN2a • pN2b | | pCR0920 |

| | | | |
|--|--|--|------------------------------------|
| | <ul style="list-style-type: none"> • pN3a • pN3b • pN3c | | |
| M stage | Single selection value list: <ul style="list-style-type: none"> • pM0 • cM0(i+) • M1 | | pCR0930 |
| Excision margins | Single selection value list: <ul style="list-style-type: none"> • Involved • Distance from each margin | | |
| Distance from superior margin, invasive | Distance in mm | | pBR4210 (Submit closest margin) |
| Distance from inferior margin, invasive | Distance in mm | | pBR4210 (Submit closest margin) |
| Distance from medial margin, invasive | Distance in mm | | pBR4210 (Submit closest margin) |
| Distance from lateral margin, invasive | Distance in mm | | pBR4210 (Submit closest margin) |
| Distance from deep margin, invasive | Distance in mm | | pBR4210 (Submit closest margin) |
| Distance from superficial margin, invasive | Distance in mm | | pBR4210 (Submit closest margin) |
| Distance from nipple margin, invasive | Distance in mm | | pBR4210 (Submit closest margin) |

| | | | |
|---|---|--|--|
| Distance from superior margin, in situ | Distance in mm | | pBR4210 (Submit closest margin) |
| Distance from inferior margin, in situ | Distance in mm | | pBR4210 (Submit closest margin) |
| Distance from medial margin, in situ | Distance in mm | | pBR4210 (Submit closest margin) |
| Distance from lateral margin, in situ | Distance in mm | | pBR4210 (Submit closest margin) |
| Distance from deep margin, in situ | Distance in mm | | pBR4210 (Submit closest margin) |
| Distance from superficial margin, in situ | Distance in mm | | pBR4210 (Submit closest margin) |
| Distance from nipple margin, in situ | Distance in mm | | pBR4210 (Submit closest margin) |
| Oestrogen receptor status | Single selection value list: <ul style="list-style-type: none"> • Positive • Low positive (1-10%) • Negative | | pBR4220 <ul style="list-style-type: none"> • Positive = P • Low positive (1-10%) = P • Negative = N |
| Oestrogen receptor, % positive tumour cells | Number (0–100) | | |
| Oestrogen receptor, average | <ul style="list-style-type: none"> • Weak • Moderate • Strong | | |

| | | | |
|---|---|--|---------|
| intensity of staining | | | |
| Oestrogen receptor, Score | Number (0–8 for Allred score and 0–300 if using H score) | | |
| On-slide positive control material* | Single selection value list: <ul style="list-style-type: none"> • Present • Absent | | |
| Progesterone receptor status* | Single selection value list: <ul style="list-style-type: none"> • Positive • Negative | | pBR4290 |
| Progesterone receptor, % positive tumour cells* | Number (0–100) | | |
| Progesterone receptor, average intensity of staining* | <ul style="list-style-type: none"> • Weak • Moderate • Strong | | |
| Progesterone receptor, Score | Number (0–8 for Allred score and 0-300 if using H score) | | |
| On-slide positive control material* | Single selection value list: <ul style="list-style-type: none"> • Present • Absent | | |
| HER2 IHC score | Single selection value list: <ul style="list-style-type: none"> • 0 Negative • 1+ Negative • 2+ Equivocal • 3+ Positive | | pBR4280 |
| ISH ratio* | Free text | | |

| | | | |
|------------------------|--|--|---------|
| HER2 status | Single selection value list: <ul style="list-style-type: none"> • Amplified • Non-amplified • Borderline • Not performed | | pBR4310 |
| HER2 copy number* | Number | | |
| Chromosome 17 number* | Number | | |
| Final HER2 status | Single selection value list: <ul style="list-style-type: none"> • Positive • Negative | | |
| SNOMED Topography code | May have multiple codes. Look up from SNOMED tables. | | pCR6410 |
| SNOMED Morphology code | May have multiple codes. Look up from SNOMED tables. | | pCR6420 |

Key

*Non-core data item.

Appendix C Assessing percentage tumour and total tissue cellularity for molecular testing

A certain amount of DNA (or RNA, depending on the test) is required to carry out different molecular tests. The exact thresholds will be set by the testing laboratory. The DNA/RNA content relates directly to the total tissue cellularity. However, molecular tests need to be interpreted in the context of percentage tumour cells present in the submitted sample. This is because, where the tumour percentage is low (<20%), somatic variants present at a low frequency may not be detected, giving a false negative result.

When selecting a tissue block for molecular testing it should be determined whether sample quality (in terms of percentage tumour) could be improved by microdissection. For example, if there are tumour-rich areas separated by cellular non-tumour tissue, the tumour foci can be outlined on the H&E to guide microdissection. In this situation, the percentage tumour cellularity and total cellularity estimates are of the selected area to be macrodissected. If the tumour is present diffusely throughout the section, microdissection is not feasible.

Assessing percentage tumour

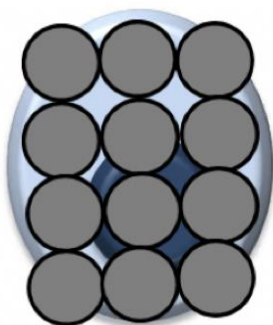
This is an estimate of the proportion of neoplastic cell nuclei out of the total number of nucleated cells in the section. It excludes any tumour-associated stromal or inflammatory cells. It is not a measure of the area occupied by the tumour. For example, if the section comprises a tumour focus surrounded by dense fibrous stroma, the tumour may occupy only 50% of the section but may contribute 90% of the DNA. Conversely, inflammatory cells are much smaller than most tumour cells, so if 50% of a section comprises tumour cells and 50% comprises inflammatory cells, the relative contribution of neoplastic DNA can be as low as 10%, particularly as this needs to be estimated for a 3-dimensional volume of tissue (see Figure C1).

A simple way to assess tumour percentage is to assess percentage of section occupied by tumour then adjust percentage neoplastic nuclei on the basis of composition of non-tumour area.

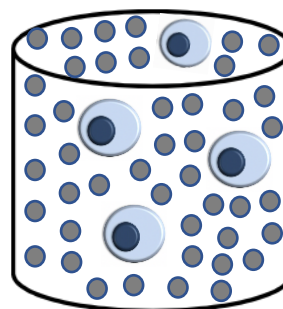
Figure C1: Relative contribution of DNA from tumour cells and lymphocytes per unit area. (Adapted with permission from the Royal Marsden Assessing Tumour Percentage and Tissue Cellularity Standard Operating Procedure.)



**Neoplastic cell – 6 pg
(picograms) DNA**



Lymphocytes – 12 x 6 pg



Effect of 3D on tumour

Assessing total tissue cellularity

This estimate helps the laboratory decide how much tissue/number of sections will be needed to extract the required amount of nucleic acid.

As a guide, ~1 nanograms of DNA is retrieved from 150 (diploid) cells. For whole genome sequencing where 2 micrograms of DNA has been recommended, ~300,000 cells are required.

The following tissue cellularity categories are provided as an example but should be agreed with providing molecular lab for consistency.

| Category | Number of cells |
|--------------|-----------------|
| Very low | <100 |
| Low | ~1,000–3,000 |
| Intermediate | 4,000–10,000 |
| High | 10,000–50,000 |
| Very high | >50,000 |

An online training module can be found at the [Genomics Education Programme website](#).

The [NHSE EQA scheme for assessing percentage tumour is accessible here](#). Participation is voluntary.

Appendix D TNM classification of tumours of the breast (UICC TNM 8)

This update to Appendix D provides updated information on staging using UICC TNM 8, which should be used for all tumours diagnosed after 1 January 2018.¹

UICC TNM 8 is essentially unchanged from UICC TNM 7. Please note that it is recommended to use UICC TNM 8 (not AJCC TNM 8) as there are significant differences between the two staging systems.

Primary tumour (T)

Designation should be made with the subscript 'c' or 'p' modifier to indicate whether the T classification was determined by clinical (physical examination or radiological) or pathological measurements, respectively.

If the tumour size is slightly less than or greater than a cut-off for a given T classification, it is recommended that the size be rounded to the millimetre reading that is closest to the cut-off, e.g. size of 1.1 mm is reported as 1 mm, or a size of 2.01 cm is reported as 2.0 cm.

| | |
|---------------|---|
| TX | Primary tumour cannot be assessed |
| T0 | No evidence of primary tumour |
| Tis | Carcinoma in situ |
| Tis (DCIS) | DCIS |
| Tis (LCIS) | LCIS |
| Tis (Paget's) | Paget's disease of the nipple NOT associated with invasive carcinoma and/or carcinoma in situ (DCIS and/or LCIS) in the underlying breast parenchyma Carcinomas in the breast parenchyma associated with Paget's disease are categorised based on the size and characteristics of the parenchymal disease, but presence of Paget's disease should still be noted |
| T1 | Tumour ≤20 mm in greatest dimension |
| T1mi | Tumour ≤1 mm in greatest dimension |
| T1a | Tumour >1 mm but ≤5 mm in greatest dimension |
| T1b | Tumour >5 mm but ≤10 mm in greatest dimension |
| T1c | Tumour >10 mm but ≤20 mm in greatest dimension |
| T2 | Tumour >20 mm but ≤50 mm in greatest dimension |
| T3 | Tumour >50 mm in greatest dimension |

| | |
|-----|--|
| T4 | Tumour of any size with direct extension to the chest wall and/or to the skin (ulceration or skin nodules) (Note: invasion of the dermis alone does not qualify as T4) |
| T4a | Extension to the chest wall, not including only pectoralis muscle adherence/invasion |
| T4b | Ulceration and/or ipsilateral satellite nodules and/or oedema (including peau d'orange) of the skin, which do not meet the criteria for inflammatory carcinoma |
| T4c | Both T4a and T4b |
| T4d | Inflammatory carcinoma |

Nodes (pN)

Classification is based on axillary lymph node dissection with or without sentinel lymph node biopsy. Classification based solely on sentinel lymph node biopsy without subsequent axillary lymph node dissection is designated (SN) for 'sentinel node,' e.g. pN0(SN).

| | |
|-----------|---|
| pNX | Regional lymph nodes cannot be assessed (e.g. previously removed or not removed for histological assessment) |
| pN0 | No regional lymph node metastasis identified histologically NB: ITCs are defined as small clusters of cells ≤ 0.2 mm, or single tumour cells, or a cluster of < 200 cells in a single histologic cross section. ITCs may be detected by routine H&E or by IHC. Nodes containing only ITCs are excluded from the total positive node count for purposes of N classification but should be included in the total number of nodes evaluated. |
| pN0(i-) | No regional lymph node metastases histologically, negative IHC |
| pN0(i+) | Malignant cells in regional lymph node(s) ≤ 0.2 mm (detected by H&E or IHC including ITC) |
| pN0(mol-) | No regional lymph node metastases histologically, negative molecular findings (RT-PCR) |
| pN0(mol+) | Positive molecular findings (RT-PCR), but no regional lymph node metastases detected by histology or IHC |
| pN1 | Micrometastases OR Metastases in 1–3 axillary lymph nodes AND/OR Metastases in internal mammary nodes with metastases detected by sentinel lymph node biopsy but not clinically detected |
| pN1mi | Micrometastases (> 0.2 mm and/or > 200 cells but none > 2.0 mm) |
| pN1a | Metastases in 1–3 axillary lymph nodes, at least 1 metastasis > 2.0 mm |
| pN1b | Metastases in internal mammary nodes with micrometastases or macrometastases detected by sentinel lymph node biopsy but not clinically detected |

- pN1c Metastases in 1–3 axillary lymph nodes **and** in internal mammary lymph nodes with micrometastases or macrometastases detected by sentinel lymph node biopsy but not clinically detected
- pN2 Metastases in 4–9 axillary lymph nodes OR
Metastases in clinically detected internal mammary lymph nodes in the **absence** of axillary lymph node metastases.
- pN2a Metastases in 4–9 axillary lymph nodes (at least 1 deposit >2 mm)
- pN2b Metastases in clinically detected internal mammary lymph nodes in the **absence** of axillary lymph node metastases
- pN3 Metastases in ≥10 axillary lymph nodes OR
Metastases in infraclavicular (level III axillary) lymph nodes OR
Metastases in clinically detected ipsilateral internal mammary lymph nodes in the **presence** of 1 or more positive level I, II axillary lymph nodes OR
Metastases in >3 axillary lymph nodes **and** in internal mammary lymph nodes with micrometastases or macrometastases detected by sentinel lymph node biopsy but not clinically detected OR
Metastases in ipsilateral supraclavicular lymph nodes
- pN3a Metastases in ≥10 axillary lymph nodes (at least 1 tumour deposit >2.0 mm) OR
Metastases in the infraclavicular (level III axillary lymph) nodes
- pN3b Metastases in clinically detected ipsilateral internal mammary lymph nodes in the **presence** of 1 or more positive axillary lymph nodes OR
Metastases in >3 axillary lymph nodes and in internal mammary lymph nodes with micrometastases or macrometastases detected by sentinel lymph node biopsy but not clinically detected
- pN3c Metastases in ipsilateral supraclavicular lymph nodes

Post-treatment ypN classification

Post-treatment ypN should be evaluated as for clinical (pre-treatment) ‘N’ methods above. The modifier ‘SN’ is used only if a sentinel node evaluation was performed after treatment. If no subscript is attached, it is assumed that the axillary nodal evaluation was by axillary lymph node dissection (ALND).

The X classification should be used (ypNX) if no yp post-treatment SN or ALND was performed.

N categories are the same as those used for pN.

Distant metastases (M)

This is generally not assessable by the pathologist and cannot, therefore, be included on surgical specimen histology reports.

- M0 No clinical or radiological evidence of distant metastases
- cM0(i+) No clinical or radiological evidence of distant metastases, but deposits of molecularly or microscopically detected tumour cells in circulating blood, bone marrow, or other non-regional nodal tissue that are ≤ 0.2 mm in a patient without symptoms or signs of metastases
- M1 Distant detectable metastases as determined by classic clinical and radiographic means and/or histologically proven >0.2 mm

Post-treatment ypM classification

The M category for patients treated with neoadjuvant therapy is the category assigned in the clinical stage, prior to initiation of neoadjuvant therapy. Identification of distant metastases after the start of therapy in cases where pre-therapy evaluation showed no metastases is considered progression of disease. If a patient was designated to have detectable distant metastases (M1) before chemotherapy, the patient will be designated as M1 throughout.

Helpful rules of thumb for TNM stage

In the case of multiple simultaneous tumours in 1 organ, the tumour with the highest T category should be classified and the multiplicity or the number of tumours should be indicated in parentheses, e.g. T2(m) or T2(5). In simultaneous bilateral cancers of paired organs, each tumour should be classified independently.

If there is doubt concerning the correct T, N or M category to which a particular case should be allotted, then the lower (i.e. less advanced) category should be chosen. This will also be reflected in the stage grouping.

Anatomic stage/prognostic groups

*T0 and T1 tumours with nodal micrometastases only are excluded from Stage IIA and are classified Stage IB.

- M0 includes M0(i+).
- The designation pM0 is not valid; any M0 should be clinical.

- If a patient presents with M1 prior to neoadjuvant systemic therapy, the stage is considered Stage IV and remains Stage IV regardless of response to neoadjuvant therapy.
- Post-neoadjuvant therapy is designated with 'yc' or 'yp' prefix.

Notably, no stage group is assigned if there is a pCR to neoadjuvant therapy, e.g. ypT0ypN0cM0.

| Stage | T | N | M |
|--------------|-----------------------------|----------|----------|
| 0 | Tis | N0 | M0 |
| IA | T1 (<i>includes T1mi</i>) | N0 | M0 |
| IB | T0 | N1mi | M0 |
| | T1 (<i>includes T1mi</i>) | N1mi | M0 |
| IIA | T0 | N1 * | M0 |
| | T1 (<i>includes T1mi</i>) | N1 * | M0 |
| | T2 | N0 | M0 |
| IIB | T2 | N1 | M0 |
| | T3 | N0 | M0 |
| IIIA | T0 | N2 | M0 |
| | T1 (<i>includes T1mi</i>) | N2 | M0 |
| | T2 | N2 | M0 |
| | T3 | N1 | M0 |
| | T3 | N2 | M0 |
| IIIB | T4 | N0 | M0 |
| | T4 | N1 | M0 |
| | T4 | N2 | M0 |
| IIIC | Any T | N3 | M0 |
| IV | Any T | Any N | M1 |

Reference

1. Brierley JD, Gospodarowicz MK, Wittekind C (eds.). *TNM Classification of Malignant Tumours (8th edition)*. Oxford, UK: Wiley-Blackwell, 2017.

Appendix E SNOMED codes for breast pathology

SNOMED topography should be recorded for the site of the tumour. SNOMED morphology codes should be recorded for the diagnosis/tumour morphology.

Versions of SNOMED prior to SNOMED CT ceased to be licenced by the International Health Terminology Standards Development Organisation from 26 April 2017. It is recognised that versions of SNOMED 2, SNOMED 3/RT and SNOMED CT are in use in the UK.

SNOMED procedure codes (P codes in SNOMED 2/3/RT) should be recorded for the procedure. P codes vary according to the SNOMED system in use in different organisations, therefore local P codes should be recorded and used for audit purposes.

The following are SNOMED3 equivalents of the ICD-O codes that are recognised internationally.

The licensing rights to SNOMED are held by IHTSDO.

| Morphological codes | SNOMED code | SNOMED CT terminology | SNOMED CT code |
|--|--------------------|--|-----------------------|
| Adenocarcinoma not otherwise specified (NOS) | M-81403 | Adenocarcinoma, no subtype (morphologic abnormality) | 1187332001 |
| Adenoid cystic carcinoma | M-82003 | Adenoid cystic carcinoma (morphologic abnormality) | 11671000 |
| Adenoma of nipple | M-85060 | Adenoma of the nipple (morphologic abnormality) | 65787003 |
| Adenomyoepithelioma (benign) | M-89830 | Adenomyoepithelioma (morphologic abnormality) | 128765009 |
| Adenomyoepithelioma (malignant) | M-89833 | Adenomyoepithelioma with carcinoma (morphologic abnormality) | 703644009 |

| | | | |
|--|---------|---|------------|
| Angiosarcoma | M-91203 | Haemangiosarcoma (morphologic abnormality) | 39000009 |
| Apocrine carcinoma | M-85733 | Adenocarcinoma with apocrine metaplasia (morphologic abnormality) | 22694002 |
| Atypical medullary carcinoma | M-85133 | Atypical medullary carcinoma (morphologic abnormality) | 128698005 |
| Carcinoma with osteoclast-like giant cells | M-80353 | Carcinoma with osteoclast-like giant cells (morphologic abnormality) | 128631001 |
| Cribriform carcinoma | M-82013 | Cribriform carcinoma (morphologic abnormality) | 30156004 |
| DCIS | M-85002 | Intraductal carcinoma, noninfiltrating, no International Classification of Diseases for Oncology (ICDO) subtype (morphologic abnormality) | 1162814007 |
| Ductal adenoma | M-85030 | Intraductal papilloma (morphologic abnormality) | 5244003 |
| Ductal carcinoma/NST | M-85003 | Infiltrating duct carcinoma (morphologic abnormality) | 82711006 |
| Encysted papillary carcinoma | M-85042 | Noninfiltrating intracystic carcinoma (morphologic abnormality) | 703545003 |
| Fibroadenoma | M-90100 | Fibroadenoma, no ICDO subtype (morphologic abnormality) | 1156873009 |
| Fibroadenoma juvenile | M-90300 | Juvenile fibroadenoma (morphologic abnormality) | 46212000 |
| Fibromatosis-like carcinoma | M-85723 | Adenocarcinoma with spindle cell metaplasia (morphologic abnormality) | 68358000 |

| | | | |
|-----------------------------------|---------|--|-----------|
| Granular cell tumour | M-95800 | Granular cell tumour (morphologic abnormality) | 12169001 |
| Haemangioma | M-91200 | Haemangioma, no ICDO subtype (morphologic abnormality) | 253053003 |
| Hamartoma | M-90203 | Hamartoma (morphologic abnormality) | 51398009 |
| Inflammatory carcinoma | M-85303 | Inflammatory carcinoma (morphologic abnormality) | 32968003 |
| Intraductal papilloma | M-85030 | Intraductal papilloma (morphologic abnormality) | 5244003 |
| Intraductal papilloma with DCIS | M-85032 | Noninfiltrating intraductal papillary adenocarcinoma (morphologic abnormality) | 30566004 |
| Invasive micropapillary carcinoma | M-85073 | Invasive micropapillary carcinoma of breast (morphologic abnormality) | 703578005 |
| Invasive papillary carcinoma | M-85033 | Intraductal papillary adenocarcinoma with invasion (morphologic abnormality) | 64524002 |
| LCIS | M-85202 | Lobular carcinoma in situ (morphologic abnormality) | 77284006 |
| Lipoma | M-88500 | Lipoma, no ICDO subtype (morphologic abnormality) | 253045006 |
| Lobular carcinoma | M-85203 | Lobular carcinoma (morphologic abnormality) | 89740008 |
| Low-grade adenosquamous carcinoma | M-85703 | Adenocarcinoma with squamous metaplasia (morphologic abnormality) | 15176003 |

| | | | |
|--|------------------|---|------------|
| Lymphoma NOS | M-95903 | Malignant lymphoma, no ICDO subtype (morphologic abnormality) | 1163043007 |
| Medullary carcinoma | M-85103 | Medullary carcinoma (morphologic abnormality) | 32913002 |
| Metaplastic carcinoma NOS | M-85753 | Metaplastic carcinoma (morphologic abnormality) | 128705006 |
| Metastatic carcinoma | M-80106 | Carcinoma, metastatic (morphologic abnormality) | 79282002 |
| Mixed carcinoma | Specify subtypes | | |
| Mucinous carcinoma | M-84803 | Mucinous adenocarcinoma (morphologic abnormality) | 72495009 |
| Myoepithelial carcinoma | M-89823 | Malignant myoepithelioma (morphologic abnormality) | 128884000 |
| Myofibroblastoma | M-88250 | Myofibroblastoma (morphologic abnormality) | 128738002 |
| Neuroendocrine carcinoma (poorly differentiated) | M-80413 | Small cell carcinoma (morphologic abnormality) | 74364000 |
| Neuroendocrine carcinoma (well differentiated) | M-82463 | Neuroendocrine carcinoma (morphologic abnormality) | 1286767006 |
| Nodular fasciitis | M-88280 | Nodular fasciitis (morphologic abnormality) | 703616008 |
| Paget's disease of nipple | M-85403 | Paget's disease, mammary (morphologic abnormality) | 2985005 |

| | | | |
|---------------------------------|---------|--|------------|
| Papillary carcinoma in situ | M-85032 | Noninfiltrating intraductal papillary adenocarcinoma (morphologic abnormality) | 30566004 |
| Papilloma multiple | M-85050 | Intraductal papillomatosis (morphologic abnormality) | 32296002 |
| Phyllodes benign | M-90200 | Phyllodes tumour, benign (morphologic abnormality) | 16566002 |
| Phyllodes malignant | M-90203 | Phyllodes tumour, malignant (morphologic abnormality) | 87913009 |
| Phyllodes borderline | M-90201 | Phyllodes tumour, borderline (morphologic abnormality) | 71232009 |
| Pleomorphic carcinoma | M-80223 | Pleomorphic carcinoma (morphologic abnormality) | 16741004 |
| Pleomorphic LCIS | M-85192 | Pleomorphic lobular carcinoma in situ (morphologic abnormality) | 444591006 |
| Secretory carcinoma | M-85023 | Juvenile carcinoma of the breast (morphologic abnormality) | 41919003 |
| Signet ring carcinoma | M-84903 | Signet ring cell carcinoma (morphologic abnormality) | 87737001 |
| Spindle cell carcinoma | M-80323 | Spindle cell carcinoma (morphologic abnormality) | 65692009 |
| Squamous cell carcinoma | M-80703 | Squamous cell carcinoma, no ICDO subtype (morphologic abnormality) | 1162767002 |
| Syringomatous adenoma of nipple | M-84070 | Syringoma (morphologic abnormality) | 71244007 |
| Tubular adenoma | M-82110 | Tubular adenoma, no ICDO subtype (morphologic abnormality) | 1156654007 |

| | | | |
|----------------------------|---------|--|----------|
| Tubular carcinoma | M-82113 | Tubular adenocarcinoma (morphologic abnormality) | 4631006 |
| Undifferentiated carcinoma | M-80203 | Carcinoma, undifferentiated (morphologic abnormality) | 38549000 |

Other conditions

| Term | SNOMED code | SNOMED CT terminology | SNOMED CT code |
|-------------------------------|--------------------|---|-----------------------|
| Abscess | M-41610 | Abscess (morphologic abnormality) | 44132006 |
| Accessory/ectopic breast | D4-48012 | Accessory breast (disorder) | 18166000 |
| Apocrine metaplasia | M-73310 | Apocrine metaplasia (morphologic abnormality) | 81274009 |
| Atypical apocrine hyperplasia | M-73315 | Atypical apocrine metaplasia (morphologic abnormality) | 103673004 |
| Atypical ductal hyperplasia | M-72175 | Atypical intraductal hyperplasia (morphologic abnormality) | 6660000 |
| Atypical lobular hyperplasia | M-72105 | Atypical lobular hyperplasia (morphologic abnormality) | 33889003 |
| Calcification | M-55400 | Calcified structure(morphologic abnormality) | 18115005 |
| Collagenous spherulosis | M-72171 | Collagenous spherulosis (morphologic abnormality) | 447298005 |
| Columnar cell atypia | M-67020 | Columnar cell atypia (morphologic abnormality) | 55465005 |
| Columnar cell lesions | M-74240 | Blunt duct adenosis (morphologic abnormality) | 58811002 |

| | | | |
|---------------------------------------|---------|---|-----------|
| Complex sclerosing lesion | M-78731 | Radial scar (morphologic abnormality) | 133855003 |
| Cyst NOS | M-33400 | Cyst (morphologic abnormality) | 367643001 |
| Duct ectasia | M-32100 | Duct ectasia (morphologic abnormality) | 22049009 |
| Epithelial hyperplasia without atypia | M-72170 | Intraductal hyperplasia (morphologic abnormality) | 67617000 |
| Excision margins tumour free | M-09400 | Surgical margin uninvolved by tumour (finding) | 55182004 |
| Fat necrosis | M-54110 | Fat necrosis (morphologic abnormality) | 79682009 |
| Fibrocystic change | M-74320 | Fibrocystic disease (morphologic abnormality) | 133852000 |
| Fibromatosis | M-76100 | Angiomatosis (morphologic abnormality) | 14350002 |
| Fistula | M-39300 | Acquired fistula (morphologic abnormality) | 51711001 |
| Foreign body reaction | M-44140 | Foreign body giant cell granuloma (morphologic abnormality) | 37058002 |
| Galactocoele | M-33220 | Galactocoele associated with childbirth (disorder) | 87840008 |
| Gynaecomastia | M-71000 | Hypertrophy (morphologic abnormality) | 56246009 |
| Infarction | M-54700 | Infarct (morphologic abnormality) | 55641003 |
| Inflammation acute | M-41000 | Acute inflammation (morphologic abnormality) | 4532008 |
| Inflammation chronic | M-43000 | Focal chronic inflammation (morphologic abnormality) | 409781003 |

| | | | |
|---|----------|---|-----------|
| Inflammation chronic | M-43000 | Diffuse chronic inflammation (morphologic abnormality) | 123632006 |
| Inflammation granulomatous | M-44000 | Granulomatous inflammation (morphologic abnormality) | 6266001 |
| Involucional change | M-79140 | Menstrual involution of breast (morphologic abnormality) | 33429008 |
| Juvenile hypertrophy | D7-90404 | Pubertal breast hypertrophy (disorder) | 198113009 |
| Lactational change | M-82040 | Lactating adenoma (morphologic abnormality) | 128651002 |
| Metaplasia atypical | M-73005 | Atypical metaplasia (morphologic abnormality) | 125544002 |
| Metaplasia chondroid | M-73600 | Cartilaginous metaplasia (morphologic abnormality) | 112671001 |
| Metaplasia epithelial (clear cell, etc) | M-73200 | Epithelial metaplasia (morphologic abnormality) | 54725001 |
| Metaplasia osseous | M-73400 | Osseous metaplasia (morphologic abnormality) | 38109001 |
| Metaplasia squamous | M-73220 | Squamous metaplasia (morphologic abnormality) | 83577005 |
| Microglandular adenosis | M-72480 | Microglandular hyperplasia (morphologic abnormality) | 2953007 |
| Microglandular hyperplasia | M-72450 | Adenofibromyomatous hyperplasia (morphologic abnormality) | 88000003 |
| Morphological description only | M-09350 | Morphologic description only (finding) | 85728002 |
| Mucocoele-like lesion | M-33440 | Mucous cyst (morphologic abnormality) | 19633006 |

| | | | |
|--------------------------|---------|---|-----------|
| Normal: NOS | M-00100 | Normal tissue (finding) | 30389008 |
| PASH | M-72430 | Stromal hyperplasia (morphologic abnormality) | 75235002 |
| Plasma cell mastitis | M-43060 | Plasma cell inflammation (morphologic abnormality) | 26246006 |
| Pregnancy | M-68080 | Pregnancy pattern (morphologic abnormality) | 68737009 |
| Radial scar | M-78731 | Radial scar (morphologic abnormality) | 133855003 |
| Radiotherapy effect | M-11600 | Radiation injury (morphologic abnormality) | 81018009 |
| Sclerosing adenosis | M-74220 | Fibrosing adenosis (morphologic abnormality) | 50916005 |
| Surgical wound or cavity | M-14020 | Surgical wound (morphologic abnormality) | 112633009 |
| Weddelite | M-55400 | Pathologic calcification, calcified structure (morphologic abnormality) | 18115005 |

Appendix F Diagnostic immunohistochemistry of the breast

IHC can be a valuable adjunct to conventional histology in improving diagnostic accuracy and consistency. Marker studies should not be viewed in isolation but interpreted in the context of the appearances on conventional H&E histology.

1 Distinction between usual epithelial hyperplasia and atypical ductal hyperplasia/low-grade ductal carcinoma in situ

Epithelial hyperplasia of usual type generally shows strong but heterogeneous/mosaic staining for high molecular weight ('basal') cytokeratin markers (e.g. CK5, CK5/6, CK14 and CK17), whereas ADH and low/intermediate DCIS are uniformly negative. Care should be taken to not misinterpret positivity in residual normal epithelial and myoepithelial cells. However, negative staining with basal cytokeratins should not by itself be regarded as diagnostic of atypia or malignancy, since many normal epithelial cells and all columnar cell lesions are negative. Likewise, a small proportion of high-grade DCIS may be of a basal phenotype and focally positive with basal cytokeratins. 34betaE12, which detects a common epitope on CK1, 5, 10 and 14, is not discriminatory in this context and is not recommended.

ER staining may also be useful in this context. Usual epithelial hyperplasia will typically exhibit a heterogeneous pattern with variable percentage positivity as well as staining intensities. In contrast, the clonal luminal epithelial cell populations of ADH and low-grade DCIS exhibit homogeneous strong ER positivity. This strong uniform pattern of ER expression is unhelpful in distinguishing low-grade intraductal epithelial proliferations from both lobular neoplasia and from the entire range of columnar cell lesions, as all these show a similar staining pattern (of a luminal phenotype).

2 Lobular carcinoma phenotype

Expression of the cell adhesion molecule E-cadherin may be useful in distinguishing between DCIS and lobular in situ neoplasia (ALH and LCIS), and also between invasive carcinoma of NST and invasive lobular lesions. E-cadherin typically exhibits a strong linear membrane pattern of staining in ductal lesions (in situ and/or invasive), while lobular lesions are usually negative. Interpretation is not, however, always straightforward and up to 20% of lobular carcinomas cases show membrane E-cadherin reactivity.^{1,2} Some

lobular carcinomas show cytoplasmic E-cadherin positivity; in others, there is weak, patchy membrane positivity, while in some there may be an aberrant pattern of staining with punctate cytoplasmic or membrane 'dot-like' positivity, particularly in the pleomorphic variant. It may be useful to compare intensity of E-cadherin staining with adjacent normal ducts/lobules as lobular carcinomas may occasionally only show weak rather than absent staining. In equivocal cases, p120 catenin or beta-catenin may be helpful, showing cytoplasmic positivity in lobular carcinomas and a membrane pattern of staining in ductal carcinomas.

Specifically, positive E-cadherin staining should not be used to re-classify a tumour (as NST) that is considered to be a typical invasive lobular carcinoma on H&E examination; indeed in this situation the value of examination of E-cadherin may be questioned. Immunohistochemical findings must be interpreted in the context of the findings on conventional histology. Care must be taken not to misinterpret E-cadherin positive benign epithelial and myoepithelial cells admixed with the cells of lobular neoplasia.

3 Assessment of stromal invasion

The distinction between invasive and in situ disease has significant implications for patient management. Identification of a peripheral rim of enclosing myoepithelial cells confirms a tumour focus remains in situ, while the absence of a surrounding layer is strongly suggestive (although not necessarily diagnostic) of invasion. Potential attenuation, or discontinuity, of the myoepithelial cell layer in an in situ lesion should always be considered.

Common diagnostic scenarios benefitting from identification of myoepithelium include:

- distinction between the entrapped tubules in the central portion of a radial scar and invasive tubular carcinoma
- distinction between invasive malignancy and in situ carcinoma, particularly when the latter is colonising a sclerosing lesion (e.g. sclerosing adenosis)
- identification of certain special types of tumour characterised by the presence of myoepithelial differentiation, e.g. adenoid cystic carcinoma and adenomyoepithelioma.

A range of immunohistochemical markers can be used to highlight myoepithelial cells but these vary in sensitivity and specificity. SMMHC is a particularly useful marker that gives strong positive staining in the cytoplasm of myoepithelial cells, although it also highlights smooth muscle of vascular walls. Care should be taken not to misinterpret such staining,

particularly when vessels are found closely applied to epithelial cell islands, for example with the fibrovascular cores of a papillary lesion. SMMHC is only weakly expressed by stromal myofibroblasts, if at all, thus usually shows little background reactivity, producing a 'clean' picture.

Other myoepithelial markers that identify antigens present in muscle, e.g. the calcium-binding protein calponin and smooth muscle actin (SMA), show greater reactivity in vascular walls and stromal myofibroblasts and, therefore, may be more problematic to interpret. p63 is a sensitive marker expressed in the nucleus of myoepithelial cells. It may be expressed in a small proportion of breast cancers, especially metaplastic carcinomas in which it is a useful marker. As the reactivity is nuclear in location, it may appear discontinuous (e.g. around expanded duct spaces), but demonstration of nuclear expression of p63 complements the other cytoplasmic markers. It is important to remember that there may be p63 positive cells at the periphery of islands of low-grade adenosquamous carcinoma; this reactivity, in particular, may be misinterpreted in this setting.

CK5 and CK14 are neither very specific nor sensitive myoepithelial markers and are hence not routinely recommended for assessment of myoepithelial cells.

Myoepithelial markers and basement membrane (laminin and collagen IV) markers may assist in the diagnosis of microinvasive carcinoma. A pancytokeratin marker or CK7 may also be valuable to highlight single or small irregular clusters of epithelial cells, for example, in the background of inflammation or diathermy artefact.

4 Paget's disease of nipple versus melanoma versus carcinoma

Paget's disease of the nipple expresses CAM 5.2 but this is not seen in intraepidermal squamous carcinoma, normal squamous epithelium or melanoma. CK7 is positive in almost all cases of Paget's disease but not intraepidermal squamous carcinoma or melanoma. However, care should be exercised in the interpretation of CK7 staining as Merkel cells, Toker cells and intraepithelial extensions of lactiferous duct cells may be positive with this marker. HER2 is positive in approximately 90% of cases and is particularly valuable diagnostically. EMA may also be expressed in Paget's disease. HMB45 and Melan-A are positive in melanoma but not Paget's disease or intraepidermal squamous carcinoma. S100 is of limited usefulness, as approximately 20% of Paget's disease may be positive. p63 staining may be useful to exclude intraepidermal squamous cell carcinoma.

5 Spindle cell lesions

The differential diagnosis of spindle cell lesions of the breast is wide and includes a variety of benign and malignant lesions of epithelial, myoepithelial and mesenchymal origin. A detailed overview of this subject is beyond the scope of this document; the following is a brief practical guide.

The differential diagnosis of any malignant spindle cell lesion of the breast must include monophasic spindle cell (metaplastic) carcinoma, as well as sarcoma including angiosarcoma (particularly if there is a history of radiotherapy exposure) and malignant phyllodes tumour. Some spindle cell carcinomas may show only mild pleomorphism, especially the fibromatosis-like variant; this diagnosis must be considered in the differential diagnosis of any low-grade breast spindle cell lesion.

A wide panel of cytokeratin markers should be employed in the assessment of a possible metaplastic carcinoma as the sensitivity of any individual marker in this context varies.³ Antibodies to broad spectrum cytokeratins (e.g. AE1/AE3 and MNF116) are most frequently positive (approximately 80%), basal cytokeratins (such as 34 β E12, CK5 and CK14) are positive in approximately 70% and luminal cytokeratins (e.g. CK8/18, CK7 and CK19) are expressed in 30–60% of cases. Myoepithelial markers are also frequently positive; p63 is particularly valuable in this setting and should always be included in the panel.

Most spindle cell lesions including metaplastic carcinoma will express vimentin, which is of little value. Expression of SMA may reflect myofibroblastic as well as smooth muscle differentiation and is, therefore, seen in nodular fasciitis, myofibroblastoma and fibroblastic/myofibroblastic proliferative post-FNAC or core biopsy. CD34 is expressed in the stroma of the vast majority of phyllodes tumours (except malignant lesions) but is also seen in myofibroblastoma, pseudoangiomatous stromal hyperplasia (PASH) and spindle cell/pleomorphic lipoma among others. Fibromatosis of the breast is usually positive for SMA but negative for CD34. Approximately 50% of fibromatoses show nuclear expression of beta-catenin, although this is not specific and is also present in the stroma of phyllodes tumours. Myofibroblastomas are often positive for hormone receptors and bcl-2.⁴ Other useful findings identifying specific mesenchymal breast lesions include expression of ALK-1 in inflammatory myofibroblastic tumours and diffuse strong staining for STAT-6 in solitary fibrous tumours.

6 Papillary lesions

A uniform layer of myoepithelial cells (highlighted by, for example, SMM and p63) is seen underlying the epithelium in the fibrovascular fronds in benign papillomas, while a myoepithelial layer is absent in the fronds in papillary carcinoma in situ and encapsulated papillary carcinoma. The latter will typically not have a surrounding layer of myoepithelium at its periphery. When DCIS is seen within a papilloma and, in papillary carcinoma in situ, a myoepithelial cell layer is identified at the periphery of the involved ducts, although this may appear discontinuous. Low-grade epithelial atypia in a papilloma may be highlighted by lack of staining with CK5 and CK14, as in non-papillary lesions, although examination of ER is less helpful in this setting as the non-neoplastic columnar cells of the papilloma will also be ER-positive. A proportion of solid papillary carcinomas express neuroendocrine markers such as synaptophysin and chromogranin; these markers can be useful in challenging cases where the differential diagnosis includes florid usual epithelial hyperplasia.

7 Apocrine carcinoma phenotype

Expression of gross cystic disease fluid protein 15 (GCDFP15) and androgen receptor may help confirm an apocrine phenotype. Positive staining of GCDFP15 may help identify breast as the site of origin in samples from metastatic lesions but GATA3 is more useful in this setting, see below.⁵

8 Primary versus metastatic carcinoma

No single immunohistochemical marker is sensitive or specific enough to identify a carcinoma as definitively of breast origin. There are a variety of potentially useful markers that may aid diagnosis, although selection will depend on the likely differential diagnosis, taking into account gender of the patient, histological features, previous history and clinical findings. GATA3 is a sensitive marker of breast cancer (overall approximately 83% of primary breast carcinomas are positive) although rates are lower (38%) in triple negative cancers.⁵ Other tumours that may express this marker include urothelial, skin and salivary gland carcinomas, among many others. Staining is nuclear and typically strong and diffuse in breast cancers. GCDFP15 has moderate specificity but also lacks sensitivity and is expressed in only 10–20% of triple negative breast cancers. Strong and extensive nuclear ER positivity is suggestive of a breast origin (85–90% primary breast cancers) although it is also strongly positive in some gynaecological malignancies. Weak ER expression has been reported in occasional carcinomas from a wide variety of sites including stomach and

lung, thus positive staining does not definitively indicate a breast origin. Expression of other markers, such as thyroid transcription factor 1 (TTF-1) and napsin-A, may help distinguish breast from lung cancer (positive in 75% and 87% of lung adenocarcinomas respectively), although TTF-1 has rarely been reported in primary breast cancers.⁶ The CK7/CK20 expression profile should also be considered. The majority of breast carcinomas are CK7 positive/CK20 negative while gastric, hepatobiliary, colonic and mucinous ovarian carcinomas are usually CK20 positive. Positive expression of CK20 is, therefore, highly suggestive of a non-breast origin. Wilms tumour 1 (WT1) is expressed in the majority of ovarian serous or transitional carcinoma carcinomas while breast carcinomas are usually negative. PAX8 is another marker which may help distinguish primary breast cancer from serous papillary ovarian malignancy, being expressed in 96% of the latter but rarely in breast cancer. Expression of CDX2 is suggestive of a gastrointestinal origin; expression is seen in 85% of colorectal cancers and approximately 50% of gastric cancers. If malignant melanoma is a consideration, then positive expression of HMB45 and Melan-A may be diagnostic. Notably, S100 protein may be expressed in breast carcinomas and is, therefore, less useful.

9 Lymph node assessment

IHC is not recommended as routine for the examination of lymph nodes; however, it may be helpful if there are worrisome/uncertain features seen in the H&E sections (Table F1). In this situation IHC for broad spectrum cytokeratin, clone AE1/AE3, is recommended.⁷ Reactivity of dendritic reticulum cells and some lymphoid cells may lead to false positive results when using some cytokeratin antibodies and assessment must therefore be based on immunoreactivity and morphological correlation.

Table F1: IHC in breast cancer diagnosis.

| Diagnosis | Useful markers | Findings | Comments |
|--|----------------|---|---|
| Distinction between epithelial hyperplasia of usual type and atypical ductal | CK5, CK14, ER | Heterogeneous/mosaic staining for CK5 and CK14 in epithelial hyperplasia of usual type with ADH and DCIS uniformly negative. A mosaic pattern with ER | Absence of staining does not necessarily imply atypia or malignancy as many normal cells and columnar cells are negative with CK5 |

| | | | |
|--------------------------------|--|--|--|
| hyperplasia/ low-grade DCIS | | may also be seen in usual epithelial hyperplasia, compared with uniform, strong positivity in the low-grade neoplasia family | and CK14 (and positive for ER) |
| Lobular carcinoma phenotype | E-cadherin (and p120 catenin and beta-catenin) | Invasive lobular carcinoma and lobular in situ neoplasia usually negative for E-cadherin and show cytoplasmic positivity for p120 and beta-catenin | Compare staining intensity with adjacent normal ducts/lobules. Approximately 10–20% lobular carcinomas are E-cadherin positive. Take care not to misinterpret admixed E-cadherin positive epithelial and myoepithelial cells in lobular neoplasia. Some lobular carcinomas show cytoplasmic E-cadherin positivity, in others there is weak, patchy membrane positivity, while in some there may be an aberrant pattern of staining with punctate cytoplasmic or membrane ‘dot-like’ positivity, particularly |

| | | | |
|--|--|--|--|
| | | | in the pleomorphic variant |
| Assessment of stromal invasion | SMMHC and p63 with pancytokeratin or CK7 in some cases | Identification of surrounding myoepithelium usually implies an in situ process Pancytokeratin or CK7 may highlight infiltrative architecture in problematic cases | Basal cytokeratins (CK5 and CK14) are not specific or sensitive myoepithelial markers. Note that myoepithelial staining may be discontinuous, therefore absence of staining does not always imply invasion and peripheral myoepithelial positivity does not imply in situ in, for example, adenoid cystic and adenosquamous carcinomas |
| Paget's disease of nipple versus squamous carcinoma and melanoma | HER2, CAM5.2, CK7, EMA, S100 protein, Melan-A, p63 | Paget's disease positive for CAM5.2, CK7, HER2 (approximately 90%) and EMA. Melanoma positive for S100 and Melan-A. p63 positive in squamous cell carcinoma | 20% of Paget's disease are S100 protein positive; Toker cells are CK7 and CAM5.2 positive |
| Spindle cell lesions | Various including broad spectrum cytokeratins | Various – see text | Note potential for cytokeratin positivity in myoepithelial lesions and stroma |

| | | | |
|------------------------------------|--|---|---|
| | (e.g. AE1/AE3 and MNF116), basal cytokeratins (e.g. 34βE12, CK5 and CK14) and luminal cytokeratins (e.g. CK8/18, CK7 and CK19), SMA, CD34, ER, p63 | | of malignant phyllodes |
| Papillary lesions | SMMHC and p63; CK5, CK14, ER; chromogranin and synaptophysin in some cases | Myoepithelial markers positive in the fibrovascular cores of benign papilloma. Myoepithelium absent or reduced in papillary carcinoma in situ and encapsulated papillary carcinoma. Myoepithelial cells absent at periphery of encapsulated papillary carcinoma. Neuroendocrine markers may be positive in solid papillary carcinomas | CK5, CK14 and ER may be useful for identifying low-grade atypical epithelial proliferation within papilloma |
| Apocrine carcinoma phenotype | GCDFP-15, AR | Expressed in cells showing apocrine differentiation | |
| Primary versus secondary carcinoma | CK7, CK20, GATA3, GCDFP 15, | Breast cancers usually CK7 positive/CK20 negative; ER positivity in | Some breast cancers may be S100 positive; some |

| | | | |
|-----------------------|--|---|---|
| | ER, PR, TTF1, Napsin-A, WT1, PAX-8, CDX-2, S100 | breast and gynaecological malignancies (and at low level, in a range of other carcinomas), TTF1 and Napsin-A positive in adenocarcinoma of lung; WT1 and PAX8 positive in ovarian serous and transitional carcinoma | lung and gastric cancers may show weak ER positivity |
| Lymph node assessment | AE1/AE3; other broad spectrum cytokeratins and CK7 | Identifies epithelial cells and therefore facilitates detection of low level metastatic disease | Note potential for dendritic reticulum cells and some lymphoid cells to express epithelial markers; take care not to over-interpret benign epithelial inclusions; not recommended to be done as routine |

References

1. Canas-Marques R, Schnitt SJ. E-cadherin immunohistochemistry in breast pathology uses and pitfalls. *Histopathology* 2016;68:57–69.
2. Schnitt SJ, Brogi E, Chen YY, King TA, Lakhani SR. American Registry of Pathology Expert Opinions: The spectrum of lobular carcinoma in situ: diagnostic features and clinical implications. *Ann Diagn Pathol* 2020;45:151481.
3. Rakha EA, Coimbra ND, Hodi Z, Juneinah E, Ellis IO, Lee AH. Immunoprofile of metaplastic carcinomas of the breast. *Histopathology* 2017;6:975–985.
4. Magro G, Bisceglia M, Michal M. Expression of steroid hormone receptors, their regulated proteins, and bcl-2 protein in myofibroblastoma of the breast. *Histopathology* 2000;36:515–521.

5. Ni YB, Tsang JYS, Shao MM, Chan SK, Cheung SY, Tong J *et al.* GATA-3 is superior to GCDFP-15 and mammaglobin to identify primary and metastatic breast cancer. *Breast Cancer Res Treat* 2018;169:25–32.
6. Ni YB, Tsang JY, Shao MM, Chan SK, Tong J, To KF *et al.* TTF-1 expression in breast carcinoma: an unusual but real phenomenon. *Histopathology* 2014;64:4:504–511.
7. Xu X, Roberts SA, Pasha TL, Zhang PJ. Undesirable cytokeratin immunoreactivity of native nonepithelial cells in sentinel lymph nodes from patients with breast carcinoma. *Arch Pathol Lab Med* 2000;124:1310–1313.

Appendix G Prognostic classifiers in breast cancer and emerging prognostic and biomarker assays

Selection of systemic adjuvant therapy in early stage breast cancer is based on the assessment of prognostic and predictive factors. Although several factors have demonstrated strong and independent prognostic and predictive value, not 1 variable on its own is able to reflect the degree of tumour heterogeneity or stratify patients into clinically distinct classes for treatment decision-making. Considering multiple factors in combination is of greater clinical value and forms the basis of a number of systems used to group patients into various risk categories and to estimate the prognosis for an individual patient. In routine practice, prognostic stratification aims to identify patients whose prognosis is so good that adjuvant systemic therapy can potentially be avoided and, conversely, those whose prognosis is poor and systemic therapy is advised. Predictive stratification is applied to identify patients who will or will not respond to a specific type of therapy.

Currently available and widely used prognostic indices, algorithms and management guidelines include: the Nottingham Prognostic Index (NPI),¹ the tumour, node and metastasis (TNM) staging system² and the web-based tool, [PREDICT](#).³ These have been developed based on the clinical evidence of the different components of each classifier when used in combination.

There are numerous management guidelines, including the St Gallen Consensus Criteria, National Comprehensive Cancer Network Clinical Guideline and the European Society for Medical Oncology, which are derived from consensus opinions of international experts based on their interpretation of the current clinical evidence.^{4,5} These guidelines stratify patients into subsets based on prognostic tools and suggest preferred treatment protocols on the basis of reported estimates of efficacy.

The NPI is a well-validated prognostic scoring system based on the 3 standard and well-established prognostic variables in operable breast cancer: tumour size, histological grade and axillary lymph node status.⁶ When first described, the NPI divided patients into 3 prognostic groups. However, subsequent studies used NPI scores to allocate patients to more groups (up to 6 groups have been described).

The NPI is calculated using the formula: $NPI = \text{Grade (1 to 3)} + \text{node stage (1 to 3, see below)} + (\text{invasive carcinoma size in cm} \times 0.2)$.

Node stage is the axillary lymph node stage estimated as follows:

Score 1 = Negative nodes

Score 2 = 1–3 positive axillary nodes or a positive internal mammary node alone (e.g. for medial tumours), including micrometastatic disease

Score 3 = >3 positive nodes and/or the apical node, or any low axillary node and an internal mammary node together.

These 3 pathological variables are assessed microscopically. Size is the greatest dimension of the invasive tumour; in multifocal disease the largest invasive tumour mass is considered (unless the grades of synchronous lesions differ, when the lesion that would give the highest score should be reported).

NPI scores vary from 2.01 up to >7 and can be subdivided into the following groups:

<2.4 = Excellent prognostic group

2.4–<3.4 = Good prognostic group

3.4–<4.4 = Moderate 1 prognostic group

4.4–<5.4 = Moderate 2 prognostic group

≥5.4 = Poor prognostic group.

This latter category can be subdivided into poor (≥5.4–<6.4) and very poor prognostic groups (≥6.4).

The NPI was derived from patients treated with operable primary surgery. Although there is some evidence that it retains value post-neoadjuvant chemotherapy,⁷ it is not generally considered applicable to tumours after neoadjuvant therapy, or in locally advanced disease, or in patients with distant metastasis or for recurrent tumours.

Although management protocols vary among different centres, adjuvant systemic therapy is typically given to patients in the poor prognostic group, while patients in the excellent prognostic group may not be offered such therapy. Although many guidelines recommend hormone therapy be offered to all ER-positive patients, some published data indicate that patients in the excellent prognostic group have an outcome comparable to the age-matched general population even without systemic therapy.

The UICC TNM staging system (currently TNM 8) is applicable to all breast cancers, including those with metastatic disease and is a requirement for the Cancer Outcome and Services Dataset (COSD) and is thusly included in the UK RCPATH dataset.² However, its stratification power is limited in early stage disease, which comprises a large proportion of cases typically presenting in UK practice (i.e. small and/or node-negative tumours) and, crucially, does not incorporate histological grade or receptors status.

Web-based outcome and treatment benefit assessment tools may be used to help in decision-making regarding recommendations for systemic adjuvant therapy in early stage breast cancer. The first of these, Adjuvant!Online, used tumour size, node stage, tumour grade, ER status, patient age and comorbidities to predict patient survival. [PREDICT](#) is a similar mathematical model developed using cohorts of UK patients and includes HER2 and Ki67 status. These algorithms not only estimate prognosis but, based on the Oxford Overviews, aim to estimate the benefits of different systemic therapies. Thus, the main advantage of these web-based systems is that the additional benefit of a range of systemic therapies (hormone therapy, chemotherapy, HER2-targeted therapy and combinations) can be estimated, in addition to the patient's underlying prognosis.

1 Molecular biomarkers

Global gene expression profiling can be used to classify invasive breast cancers into molecularly distinct intrinsic subtypes;⁸ these include luminal A, luminal B, HER2-enriched (HER2-E) and basal-like classes. Studies have demonstrated that such molecular subtyping is an independent predictor of survival in breast cancer when used in multivariate analyses with standard prognostic variables.⁹ Although approximately equivalent groups can be defined using immunohistochemistry, there is no globally agreed panel of markers to define luminal, HER2 and basal-like groups. Basal-like and 'triple negative' (ER, PR and HER2 negative) cancers are not invariably equivalent entities. While many patients with triple negative cancer have a poor prognosis, this is not true for all; for example, this group includes adenoid cystic carcinomas and low-grade metaplastic lesions, which have a favourable outcome.

With the introduction of high-throughput genome-wide technologies, numerous multigene signatures and molecular assays have been identified, which can predict outcome and, potentially, response to systemic therapy and, thus, complement traditional markers. Such assays rely on measurement of gene expression in tumour RNA. Some have (or are) being assessed in clinical trials (TAILORx, RxPONDER, MINDACT, OPTIMA and others)

and are commercially available. [Guidance from the National Institute for Health and Care Excellence](#) (NICE) states that 1 of several molecular assays may be used for the assessment of invasive carcinomas in people with early breast cancer that is ER-positive, HER2-negative and lymph node-negative (or with micrometastatic disease), if they have an intermediate risk of distant recurrence (using a validated tool such as PREDICT or the NPI) and if the information provided by the test would help them choose, with their clinician, whether or not to have adjuvant chemotherapy. The assays that are approved and funded by the NHS in this setting in the UK include EndoPredict (the EPclin score), the Oncotype Dx Breast Recurrence Score and Prosigna.

Recent guidance from NICE¹⁰ has expanded the role of molecular tests in cases with 1–3 lymph node-positive disease. The guidance states that EndoPredict, Oncotype DX or Prosigna can be used as options alongside consideration of clinical risk factors to guide adjuvant chemotherapy decisions for treating ER- or PR-positive, HER2-negative early breast cancer with 1 to 3 positive lymph nodes for women who have been through the menopause, men and trans, non-binary or intersex people, depending on their hormonal profile.

The most widely used in the UK is the Oncotype DX Breast Recurrence Score, derived from the expression of 21 genes in formalin-fixed, paraffin-embedded tumour tissue using RT-PCR. The scores vary from 0 to 100; cut-offs are used to stratify patients into risk groups. The EndoPredict test analyses the activity of 12 genes which, together with the node status and carcinoma size, provides an EPclin Risk score to classify the patient as having low-risk or high-risk disease. Molecular ‘intrinsic’ subtypes (luminal A, luminal B, HER2-enriched (HER2-E) and basal-like classes) (PAM50) and prognostic risk assessments are also provided by the Prosigna Breast Cancer Prognostic Gene Signature Assay to classify risk for node-negative patients as low (0–40), intermediate (41–60) or high (61–100).

Other assays to determine prognosis are described. Some are available commercially, but are not, at present, approved for NHS funding. These include MammaPrint, which is not currently recommended for guiding adjuvant chemotherapy in early breast cancer in NHS patients as it is not considered to be cost effective by NICE, and IHC4/IHC4+C, which is an immunohistochemical assessment of ER, PR, HER2 and Ki67 (see below) but which is considered by NICE to have, as yet, insufficient analytical validity.

In essence, although these molecular classifiers include different genes and different algorithms, they may measure essentially similar biology to each other. It is noteworthy, however, that they do not necessarily place any individual patient in the same risk category. Further clinical trials are ongoing to assess their value in different patient groups (for example, those with a higher nodal volume of disease).¹¹ These assays are relatively high cost, technically demanding and, at present, only of established value for a subset of early breast cancer patients. At present, therefore, for many patients these genomic assays are not available or applicable and prognostic and predictive assessment for them is based on 'routine' histological examination.

2 Additional biomarkers

The shift towards an earlier diagnosis of breast cancer, largely due to improved imaging methods and screening programmes, and the incremental application of increasingly effective adjuvant therapies, has highlighted the need for additional prognostic and predictive markers to enable individualised, patient-tailored therapy.

2.1 Ki67

Among the widely assessed variables in breast cancer, the proliferation marker Ki67 has received the most attention. Ki67 is a nuclear non-histone protein expressed in proliferating cells and absent in quiescent (G0 phase) cells. Its expression levels are determined as the percentage of immunohistochemically stained invasive tumour cell nuclei. The use of Ki67 as a prognostic and predictive marker in breast cancer has been widely investigated because it is perceived that Ki67 assessment can provide a more objective and accurate method of tumour proliferation than mitotic counts, a key component of histological grade.

Although a prognostic value to Ki67 assessment has been demonstrated, variation among studies regarding standardisation of methodology, assessment and optimal cut-off points have limited its application clinically.¹² While the international Ki67 in Breast Cancer Working Group has been working to standardise assessment of Ki67 for some years, it notes that the clinical utility is presently limited to prognosis assessment in stage I or II breast cancer.¹³ The St Gallen 2021 expert panel was unable to define a clinically appropriate cut point for recommending chemotherapy in ER-positive, node-negative breast cancer (its main clinical use); the 2019 WHO Blue Book does not recommend routine assessment and it is not part of the RCPATH dataset.⁴ Development of guidelines regarding standardisation of methodology and of assessment is required and it is hoped

that reproducibility of assessment of Ki67 will be facilitated by digital pathology and image analysis.

2.2 Tumour infiltrating lymphocytes

The assessment of TILs has gained momentum as a prognostic marker, particularly in triple negative and HER2-positive invasive breast cancer patients.^{14,15} High numbers of TILs are associated with better outcomes and better response to neoadjuvant therapy in these patient groups. TILs can be assessed on routine H&E stained slides and can be quantified pathologically, ideally in a standardised manner according to international recommendations from the Immuno-Oncology Biomarkers Working Group (see www.tilsinbreastcancer.org, where training tutorials are available). As for Ki67 assessment, the more widespread use of digital pathology and the development of computational pathology methods is likely to make automated counting of TILs easier. At present, this is not regarded as routine, even in triple negative and HER2-positive breast cancer cases and is not part of the RCPATH dataset.

2.3 PD-L1 testing

Immunotherapy by immune checkpoint blockade has been used in several tumour types, such as melanoma and non-small cell lung cancer, with good tumour responses. Various anti-PD1/PD-L1 (programmed death-ligand 1) agents have, and are, being evaluated in breast cancer, in combination with other agents, with promising early results. Data from the phase III Impassion-130 trial showed that immunohistochemical PD-L1 expression on >1% of immune cells in metastatic triple negative breast cancer was predictive of improvements in progression-free and overall survival when first-line atezolizumab was added to nab-paclitaxel.¹⁶ When assessing PD-L1 in breast cancers, it is essential that the appropriate and specific, approved and validated antibody and scoring systems are applied, relevant to the therapy proposed. However, prediction of response to checkpoint inhibitors is evolving and additional biomarkers are likely to be described.

Newer markers and assays will continue to be developed with claims of more accurate prediction of response to therapies in different tumour subtypes. However, careful analysis of the evidence base will be required to see if these provide any additional value, and immediate adoption into pathology datasets is inappropriate.

References

1. Galea MH, Blamey RW, Elston CE, Ellis IO. The Nottingham Prognostic Index in primary breast cancer. *Breast Cancer Res Treat* 1992;22:207–219.

2. Brierley JD, Gospodarowicz MK, Wittekind C. *TNM Classification of Malignant Tumours (UICC)* (8th edition). Oxford, UK: Wiley-Blackwell, 2016.
3. Wishart GC, Azzato EM, Greenberg DC, Rashbass J, Kearins O, Lawrence G *et al*. PREDICT: a new UK prognostic model that predicts survival following surgery for invasive breast cancer. *Breast Cancer Res* 2010;doi:10.1186.2464.
4. Burstein HJ, Curigliano G, Thürlimann B, Weber WP, Poortmans P, Regan MM *et al*. Customizing local and systemic therapies for women with early breast cancer: the St. Gallen International Consensus Guidelines for treatment of early breast cancer 2021. *Ann Oncol* 2021;32:1216–1235.
5. Gradishar WJ, Anderson BO, Abraham J, Aft R, Agnese D, Allison KH *et al*. Breast Cancer, Version 3.2020, National Comprehensive Cancer Network (NCCN) Clinical Practice Guidelines in Oncology. *J Natl Compr Canc Netw* 2020;18:452–478.
6. Blamey RW, Pinder SE, Ball RG, Ellis OI, Elston WC, Mitchell JM *et al*. Reading the prognosis of the individual with breast cancer. *Eur J Cancer* 2007;43:1545–1547.
7. Abrial SC, Penault-Llorca F, Delva R, Bougnoux P, Leduc B, Mouret-Reynier MA *et al*. High prognostic significance of residual disease after neoadjuvant chemotherapy: a retrospective study in 710 patients with operable breast cancer. *Breast Cancer Res Treat* 2005;94:255–263.
8. van 't Veer LJ, Dai H, van de Vijver MJ, He YD, Hart AA, Mao M *et al*. Gene expression profiling predicts clinical outcome of breast cancer. *Nature* 2002;415:530–536.
9. Parker JS, Mullins M, Cheang MC, Leung S, Voduc D, Vickery T *et al*. Supervised risk predictor of breast cancer based on intrinsic subtypes. *J Clin Oncol* 2009;27:1160–1167.
10. NICE. *Tumour profiling tests to guide adjuvant chemotherapy decisions in early breast cancer*. Available at: www.nice.org.uk/guidance/dg58/chapter/1-Recommendations
11. Bartlett SMJ, Bayani J, Marshall A, Dunn AJ, Cunningham C, Sobol SM *et al*. Comparing breast cancer multiparameter tests in the OPTIMA prelim trial: No test is more equal than the others. *J Natl Cancer Inst* 2016;29:108.
12. Stuart-Harris R, Caldas C, Pinder SE, Pharoah P. Proliferation markers and survival in early breast cancer: a systematic review and meta-analysis of 85 studies in 32,825 patients. *Breast* 2008;17:323–334.

13. Nielsen TO, Leung SCY, Rimm DL, Dodson A, Acs B, Badve S *et al.* Assessment of Ki67 in breast cancer: Updated recommendations from the International Ki67 in Breast Cancer Working Group. *J Natl Cancer Inst* 2021;113:808–819.
14. Hendry S, Salgado R, Gevaert T, Russell PA, John T, Thapa B *et al.* Assessing tumor-infiltrating Lymphocytes in solid tumors: A practical review for pathologists and proposal for a standardized method from the International Immuno-oncology Biomarkers Working Group: Part 1: Assessing the host immune response, TILs in invasive breast carcinoma and ductal carcinoma in situ, metastatic tumor deposits and areas for further research. *Adv Anat Pathol* 2017;24:235–251.
15. Laenkholm AV, Callagy G, Balancin M, Bartlett JMS, Sotiriou C, Marchio C *et al.* Incorporation of TILs in daily breast cancer care: how much evidence can we bear? *Virchows Arch* 2022;480:147–162.
16. Schmid P, Adams S, Rugo HS, Schneeweiss A, Barrios CH, Iwata H *et al.* Atezolizumab and nab-paclitaxel in advanced triple-negative breast cancer. *N Engl J Med* 2018;29:2108–2121.

Breast Cancer Grading

Nottingham Criteria

Accurate grading of invasive breast cancer requires good fixation, processing, section cutting, staining and careful application of grading criteria. In the UK, about 20% of symptomatic breast cancers are grade 1, 30% grade 2, and 50% grade 3. These proportions may be different in asymptomatic cancers detected by mammographic screening. Special type cancers (lobular, etc) should also be graded. Three separate scores are given:

Gland (acinus) formation

Score 1: more than 75% of the whole carcinoma forms acini

Score 2: 10–75% of the whole carcinoma forms acini

Score 3: less than 10% of the whole carcinoma forms acini

Only score clearly formed glandular lumens surrounded by polarised cancer cells

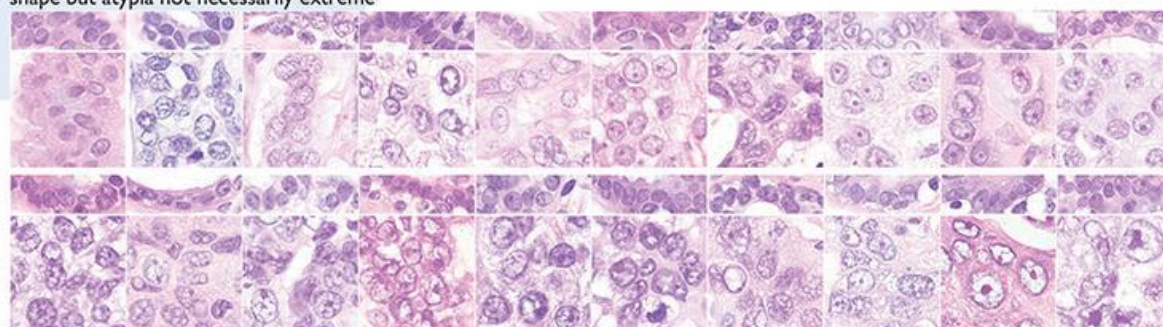
Nuclear atypia/pleomorphism

Only about 5% of symptomatic cancers score 1 for nuclear atypia; about 50% score 3.

Score 1: nuclei only slightly larger than benign breast epithelium (<1.5× normal area); minor variation in size, shape and chromatin pattern

Score 2: nuclei distinctly enlarged (1.5–2× normal area), often vesicular, nucleoli visible; may be distinctly variable in size and shape but not always

Score 3: markedly enlarged vesicular nuclei (>2× normal area), nucleoli often prominent; generally marked variation in size and shape but atypia not necessarily extreme



Nuclei of 20 consecutive breast cancers by increasing mean nuclear area (left to right, top to bottom). Paired non-neoplastic breast epithelium is shown above each case for comparison. Only one cancer (top left) has nuclei which score 1. The others in the top row score 2. All 10 in the bottom row score 3.

Mitosis counts

Measure diameter of high power field (hpf) on your microscope to the nearest 0.01 mm. Always use same objective and eyepieces; if either is changed, measure again. Read score thresholds from table below. Scan sections to find area with most mitotic activity (often at tumour edge). In this area count definite mitoses in 10 consecutive fields. Skip fields with few carcinoma cells or obvious necrosis. Convert to score (1–3).

Table of mitosis score thresholds

| Field diameter (mm) | Mitotic frequency score | | | Field diameter (mm) | Mitotic frequency score | | | Field diameter (mm) | Mitotic frequency score | | |
|---------------------|-------------------------|------|-----|---------------------|-------------------------|-------|-----|---------------------|-------------------------|-------|-----|
| | 1 | 2 | 3 | | 1 | 2 | 3 | | 1 | 2 | 3 |
| 0.40 | ≤4 | 5–9 | ≥10 | 0.50 | ≤7 | 8–14 | ≥15 | 0.60 | ≤10 | 11–20 | ≥21 |
| 0.41 | ≤4 | 5–9 | ≥10 | 0.51 | ≤7 | 8–14 | ≥15 | 0.61 | ≤10 | 11–21 | ≥22 |
| 0.42 | ≤5 | 6–10 | ≥11 | 0.52 | ≤7 | 8–15 | ≥16 | 0.62 | ≤11 | 12–22 | ≥23 |
| 0.43 | ≤5 | 6–10 | ≥11 | 0.53 | ≤8 | 9–16 | ≥17 | 0.63 | ≤11 | 12–22 | ≥23 |
| 0.44 | ≤5 | 6–11 | ≥12 | 0.54 | ≤8 | 9–16 | ≥17 | 0.64 | ≤11 | 12–23 | ≥24 |
| 0.45 | ≤5 | 6–11 | ≥12 | 0.55 | ≤8 | 9–17 | ≥18 | 0.65 | ≤12 | 13–24 | ≥25 |
| 0.46 | ≤6 | 7–12 | ≥13 | 0.56 | ≤8 | 9–17 | ≥18 | 0.66 | ≤12 | 13–24 | ≥25 |
| 0.47 | ≤6 | 7–12 | ≥13 | 0.57 | ≤9 | 10–18 | ≥19 | 0.67 | ≤12 | 13–25 | ≥26 |
| 0.48 | ≤6 | 7–13 | ≥14 | 0.58 | ≤9 | 10–19 | ≥20 | 0.68 | ≤13 | 14–26 | ≥27 |
| 0.49 | ≤6 | 7–13 | ≥14 | 0.59 | ≤9 | 10–19 | ≥20 | 0.69 | ≤13 | 14–27 | ≥28 |

Final grading

Add scores for acinus formation, nuclear atypia and mitosis count. Total score must be in the range 3–9.

Total score 3, 4 or 5 = **grade 1** Total score 6 or 7 = **grade 2** Total score 8 or 9 = **grade 3**

Prepared by Dr James J Going, Department of Pathology, Western Infirmary, Glasgow, based on Elston CW, Ellis IO. Pathological prognostic factors in breast cancer. I. The value of histological grade in breast cancer: experience from a large study with long-term follow-up. *Histopathology*, 1991; 19: 403–410, and reproduced with permission.

© NHS Cancer Screening Programmes 2005. Printed by Charlesworth, Wakefield.

Additional copies are available from DH Publications Orderline (tel 08701 555 455 or email doh@prolog.uk.com) quoting BGRADPSTR.

Appendix I Summary table – Explanation of levels of evidence

(modified from Palmer K *et al. BMJ* 2008;337:1832)

| Grade (level) of evidence | Nature of evidence |
|---------------------------|---|
| Grade A | <p>At least 1 high-quality meta-analysis, systematic review of randomised controlled trials or a randomised controlled trial with a very low risk of bias and directly attributable to the target cancer type</p> <p>or</p> <p>A body of evidence demonstrating consistency of results and comprising mainly well-conducted meta-analyses, systematic reviews of randomised controlled trials or randomised controlled trials with a low risk of bias, directly applicable to the target cancer type.</p> |
| Grade B | <p>A body of evidence demonstrating consistency of results and comprising mainly high-quality systematic reviews of case-control or cohort studies and high-quality case-control or cohort studies with a very low risk of confounding or bias and a high probability that the relation is causal and which are directly applicable to the target cancer type</p> <p>or</p> <p>Extrapolation evidence from studies described in A.</p> |
| Grade C | <p>A body of evidence demonstrating consistency of results and including well-conducted case-control or cohort studies and high-quality case-control or cohort studies with a low risk of confounding or bias and a moderate probability that the relation is causal and which are directly applicable to the target cancer type</p> <p>or</p> <p>Extrapolation evidence from studies described in B.</p> |

| | |
|---------------------------|---|
| Grade D | Non-analytic studies such as case reports, case series or expert opinion or Extrapolation evidence from studies described in C. |
| Good practice point (GPP) | Recommended best practice based on the clinical experience of the authors of the writing group. |

Appendix J AGREE II guideline monitoring sheet

The cancer datasets of the Royal College of Pathologists comply with the AGREE II standards for good quality clinical guidelines. The sections of this dataset that indicate compliance with each of the AGREE II standards are indicated in the table.

| AGREE standard | Section of guideline |
|---|------------------------|
| Scope and purpose | |
| 1 The overall objective(s) of the guideline is (are) specifically described | Introduction |
| 2 The health question(s) covered by the guideline is (are) specifically described | Introduction |
| 3 The population (patients, public, etc.) to whom the guideline is meant to apply is specifically described | Foreword, Introduction |
| Stakeholder involvement | |
| 4 The guideline development group includes individuals from all the relevant professional groups | Foreword |
| 5 The views and preferences of the target population (patients, public, etc.) have been sought | Foreword |
| 6 The target users of the guideline are clearly defined | Introduction |
| Rigour of development | |
| 7 Systematic methods were used to search for evidence | Foreword |
| 8 The criteria for selecting the evidence are clearly described | Foreword |
| 9 The strengths and limitations of the body of evidence are clearly described | Foreword |
| 10 The methods for formulating the recommendations are clearly described | Foreword |
| 11 The health benefits, side effects and risks have been considered in formulating the recommendations | N/A |
| 12 There is an explicit link between the recommendations and the supporting evidence | Throughout |
| 13 The guideline has been externally reviewed by experts prior to its publication | Foreword |
| 14 A procedure for updating the guideline is provided | Foreword |
| Clarity of presentation | |
| 15 The recommendations are specific and unambiguous | Throughout |
| 16 The different options for management of the condition or health issue are clearly presented | Throughout |
| 17 Key recommendations are easily identifiable | Throughout |

| | |
|---|----------------|
| Applicability | |
| 18 The guideline describes facilitators and barriers to its application | Foreword |
| 19 The guideline provides advice and/or tools on how the recommendations can be put into practice | All appendices |
| 20 The potential resource implications of applying the recommendations have been considered | Foreword |
| 21 The guideline presents monitoring and/or auditing criteria | 10 |
| Editorial independence | |
| 22 The views of the funding body have not influenced the content of the guideline | Foreword |
| 23 Competing interest of guideline development group members have been recorded and addressed | Foreword |